

Influence of Maxillary Sinus Width on New Bone Formation After Transcrestal Sinus Floor Elevation: A Proof-of-Concept Prospective Cohort Study

Teresa Lombardi, DDS,* Claudio Stacchi, DDS, MSc,† Federico Berton, DDS, MSc,‡
Tonino Traini, DDS, PhD,§ Lucio Torelli, DSc,¶ and Roberto Di Lenarda, DDS, MSc||

Insufficient alveolar bone height is a common obstacle to the placement of dental implants in the posterior maxilla. This condition results from bone loss caused by periodontal disease, from alveolar bone resorption after teeth extraction, from pneumatization of the maxillary sinus, or a combination of the above.¹ Many techniques have been described to overcome this situation because the grafting of maxillary sinus with lateral approach was proposed in 1976 by Tatum² and first published in 1980 by Boyne and James.³ Transcrestal sinus floor elevation (tSFE), which was first suggested by Tatum⁴ and then developed by Summers,⁵ is a minimally invasive approach to perform the grafting procedure through the residual alveolar crest: this technique allows to reduce patient morbidity and to pre-

Purpose: *Graft maturation in the maxillary sinus requires adequate angiogenesis and osteoprogenitor cells migration from the surrounding bony walls: the aim of this study was to analyze the correlation between sinus cavity dimensions and new bone formation after transcrestal sinus floor elevation (tSFE).*

Methods: *Patients needing maxillary sinus augmentation (residual crest height ≤ 4 mm) were treated with tSFE using xenogeneic granules. Six months later, bone-core biopsies were retrieved for histological analysis in the implant insertion sites. Buccopalatal sinus width (SW) was evaluated on cone beam computed tomography, and correlations between histomorphometric and anatomical parameters were quantified by means of linear regression analysis.*

Results: *Eight consecutive patients underwent tSFE procedures: at 6 months, average percentage of newly formed bone resulted $24.2\% \pm 7.9\%$. Statistical analysis showed a strong inverse correlation between SW and new bone formation ($R^2 = 0.88$), and a strong direct correlation between the number of exposed bone walls and new bone formation ($R^2 = 0.82$).*

Conclusion: *Within the limitations of this proof-of-concept study, in which a restricted number of patients were analyzed, tSFE showed more predictable results in narrow than in large sinuses, in terms of new bone formation. (Implant Dent 2017;26:209–216)*

Key Words: *transalveolar sinus lift, osteotomes, dental implants, bone regeneration*

*Private Practice, Cassano allo Ionio, Italy.

†Adjunct Professor, Department of Medical, Surgical and Health Sciences, University of Trieste, Trieste, Italy.

‡Research Fellow, Department of Medical, Surgical and Health Sciences, University of Trieste, Trieste, Italy.

§Senior Researcher and Professor, Department of Medical, Oral and Biotechnological Sciences, University of Chieti-Pescara, Chieti, Italy.

¶Full Professor, Department of Medical, Surgical and Health Sciences, University of Trieste, Trieste, Italy.

||Associate Professor, Department of Mathematics and Informatics, University of Trieste, Trieste, Italy.

Reprint requests and correspondence to: Claudio Stacchi, DDS, MSc, Clinica Odontoiatrica e Stomatologica dell'Università degli Studi di Trieste, Piazza Ospitale, 1—Trieste 34100, Italy, Phone: +39-0481-531229, Fax: +39-0481-531229, E-mail: claudio@stacchi.it

serve the integrity of sinus bone walls, which are the most important source for osteoprogenitor cells.⁶ Blinded approach is considered the main drawback of tSFE, with the impossibility to visualize eventual membrane perforations, even if their incidence is reported to be lower than in lateral sinus floor augmentation.^{7,8}

Residual bone height remained for many years the criterion of choice between lateral and tSFE. Since the

Sinus Consensus Conference of 1996, 5 to 7 mm of residual crestal height have been considered by many authors as a prerequisite to perform predictable tSFE procedures;^{9–12} however, recent surgical advances^{13–15} showed successful application of this technique irrespective of the residual alveolar bone height, obtaining considerable vertical augmentation with transcrestal approach.

In any sinus floor augmentation procedure, exposure of the bony walls

Table 1. Demographic Characteristics of the Treated Patients, Smoking Habits, and Measures (in mm) of Crestal Bone Height (CH) at Baseline and 6 Months After tSFE, With Relative CH Gain

Patient	Age	Sex	Smoke	Baseline CH (mm)	6-Months CH (mm)	CH Increase (mm)
1	64	M	S	2.4	10.8	8.4
2	53	M	N	3.9	14.3	10.4
3	49	F	N	2.6	11.4	8.8
4	54	F	N	3.3	12.3	9
5	50	M	N	3.7	11.1	7.4
6	41	F	N	3.2	12.6	9.4
7	69	M	S	1.4	9.4	8
Total	54.3 ± 9.4	4M—3F	2S—5N	2.93 ± 0.86	11.7 ± 1.55	8.77 ± 0.98

and their close contact with the graft are among the crucial factors for a fast and predictable colonization of the biomaterial by mesenchymal osteoprogenitor cells, which is the main biological basis for new bone formation. In transcrestal approach, the membrane is indirectly elevated by gradual increments of the biomaterial, with limited possibilities for the operator to influence and check the elevation process.

Furthermore, even with a complete elevation of the membrane from the bony walls, the healing process seems faster and more effective in terms of bone formation in narrow sinuses than in sinuses with wider buccolingual dimension.¹⁶

Avila et al¹⁷ investigated the influence of the distance from the lateral to the medial wall on the clinical outcomes of lateral sinus augmentation procedures, showing that the percentage of vital bone formation is inversely proportional to the buccopalatal distance.

An histological study by Soardi et al¹⁸ examined the healing of mineralized human bone allograft (MHBA) after lateral sinus augmentation in severely atrophic ridges (2 mm residual crestal height) and correlated the results to the sinus cavity size. Authors found that MHBA seems to promote satisfactory bone formation and that the larger the sinus, the longer the maturation time needed to achieve a suitable amount of new bone.

A retrospective study by Spinato et al¹⁹ compared sinus size with cone beam computed tomography (CBCT) outcomes of tSFE performed using MHBA: this study gives a quantitative

and statistically significant confirmation that crestal technique is more appropriate and predictable, in terms of intrasinus bone coverage of the implants, in narrow than in wide sinuses.

The purpose of this prospective proof-of-concept study was to explore the possible influence of sinus cavity size on the clinical outcomes of tSFE. The null hypothesis of this study is that there are no differences in new bone formation after tSFE performed in sinuses of different buccopalatal width. The specific aims of the study were (1) to measure the quantity of new bone formation, correlating it with the sinus buccopalatal width, (2) to test the efficacy of tSFE procedures in performing an adequate elevation of the Schneiderian membrane from lateral and medial bone walls.

MATERIALS AND METHODS

Study Design and Sample

To address the research purpose, the investigators designed and implemented a prospective cohort study. The study population was composed of all patients presenting for evaluation and management of any partial edentulism requiring unilateral maxillary sinus elevation between June and December 2013. To be included in the study sample, patients had to present a residual crestal height on the sinus floor ≤ 4 mm, to be 18 years or older, and able to understand and sign a written informed consent form.

Patients were excluded as study subjects if presenting one of the following general exclusion criteria:

- general contraindications to implant surgery
- immunosuppressed patients
- irradiated in the head and neck area
- uncontrolled diabetes (HBA1c > 7.5%)
- pregnant or breastfeeding
- alcohol or drugs abusers
- heavy smokers (>20 cigarettes/d)
- allergic to bovine collagen
- psychiatric problems or unrealistic expectations
- treated or under treatment with intravenous aminobisphosphonates
- participating in other studies, if the present protocol could not be properly followed.

Local exclusion criteria consisted of the following:

- maxillary sinus pathologies contraindicating sinus augmentation
- acute oral infections
- poor oral hygiene and motivation (FMPS > 30)
- uncontrolled periodontal disease.

The study was conducted in accordance with the fundamental principles of the Helsinki Declaration as revised in Seoul (2008) concerning research on human subjects, and the Regional Ethical Board approved the study protocol. All patients received thorough information about the nature and aim of the study (including procedures, treatment alternatives, follow-up evaluations, and potential risks) and signed a written informed consent for the treatment and the use of their data for research purposes.

Patients' recruitment, treatment, and follow-up visits were conducted by 2 operators (T.L. and C.S.).

Clinical Procedures

Preoperative radiographs (periapical and panoramic), together with a clinical examination, were performed to assess periodontal conditions and prosthetic evaluation with diagnostic waxing was conducted, to complete the treatment plan. CBCT with a template was performed to assess bone volume and evaluate sinus characteristics and dimensions.

Patients were premedicated with 2 g of amoxicillin/clavulanate potassium

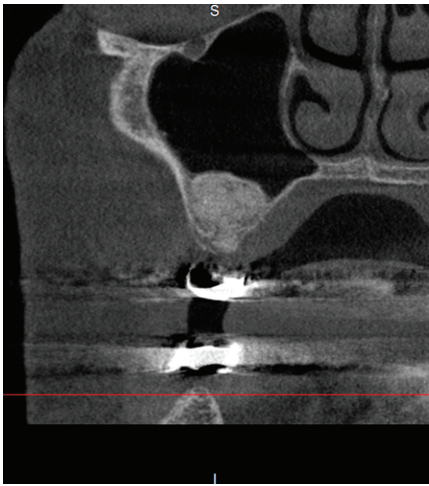


Fig. 1. CBCT taken 6 months after surgery, showing both lateral and medial bone walls of the sinus in close contact with the graft. In our study, the quantity of NFB seemed to have a strong direct correlation with the number of exposed bony walls, from which osteoprogenitor cells can easily migrate to the grafting material.

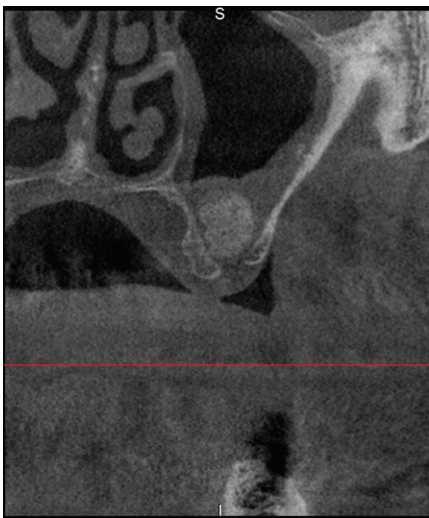

Fig. 2. CBCT taken 6 months after surgery, showing no contact between the graft and sinus lateral and medial bone walls. The graft appeared enclosed under a sort of dome deriving from the detachment of the Schneiderian membrane only from the sinus floor, receiving less osteoprogenitor cells and blood supply, and resulting in a slower cellular colonization and new bone formation.

1 hour before the surgery. Perioral skin was disinfected using iodopovidone 10%, and the subjects were asked to rinse with chlorhexidine mouthwash

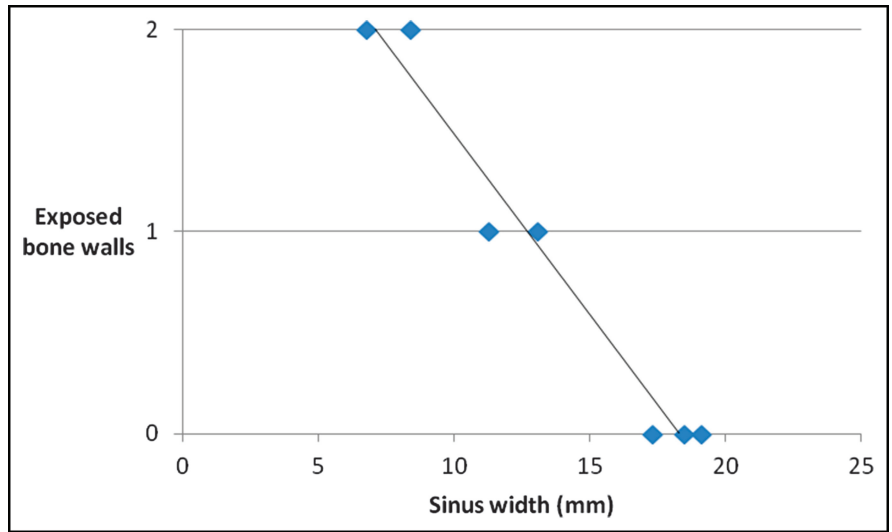


Fig. 3. Buccopalatal width of the sinus and number of bone walls exposed by tSFE procedure showed a strong inverse correlation ($R^2 = 0.96$). In the transcresal approach, the membrane elevation is indirectly performed by the biomaterial with a very limited possibility for the operator to control its action. Hence, it is extremely important to understand which are the most favorable conditions where the transcresal approach could adequately elevate the membrane, ensuring a predictable exposure of both lateral and medial sinus bone walls.

0.2% for 30 seconds. Under local anesthesia (articaine HCl 40 mg/mL with epinephrine 1:100.000—Alfacaina; Weimer Pharma, Rastatt, Germany), a full-thickness envelope flap was elevated to expose the alveolar crest and to define the exact point for the osteotomy with a surgical template. Then, a crestal access to the sinus cavity was created using a standardized sequence of specifically designed drills and osteotomes (Smart Lift; Meta, Reggio Emilia, Italy)²⁰ until reaching the Schneiderian membrane, whose integrity was checked with Valsalva maneuver. Hence, indirect membrane elevation was performed by condensing gradual increments of xenogeneic hydroxyapatite granules (Endobon; Biomet 3i, Palm Beach Gardens, FL), until a minimum height of 10 mm was obtained (comprising the residual bone crest). The crestal access to the sinus was then protected with a resorbable collagen membrane (Bio-Gide; Geistlich, Wolhusen, Switzerland), and flaps were closed with Sentineri sutures²¹ and single stitches using a synthetic monofilament (PTFE; Omnia, Fidenza, Italy).

Patients were prescribed with antibiotics for 6 days (amoxicillin 1 g twice a day) and nonsteroidal

anti-inflammatory drug (ibuprofen 600 mg), when needed. Sutures were removed after 10 days.

After 6 months, CBCT was performed to evaluate regenerated bone volume and plan implants insertion. Then, 3-mm diameter bone-core biopsies were harvested with the assistance of a surgical template in each grafted area using trephine drills (Dentag; Maniago, Italy), and dental implants were inserted in the site. The surgical guide was also used if other implants were inserted in the same surgical session. Implants were left submerged for 4 months, then connected to healing abutments to start prosthetic procedures.

Histological Processing

All histological and histomorphometric analyses were performed by one of the authors (T.T.). The retrieved biopsies were immediately rinsed for 40 seconds in cold 5% glucose solution and fixed in 10% buffered formalin at pH 7.1. After 5 days, the specimens were washed in sodium phosphate and then dehydrated in an ascending series of alcohols for 10 days. After dehydration, the specimens were removed from the trephine using a custom plunger and

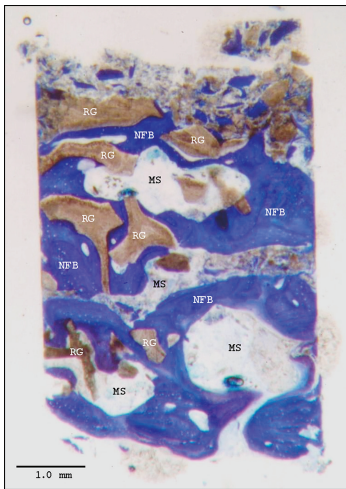


Fig. 4. Graft particles were easily distinguishable from the other components of the regenerated tissue 6 months after surgery. At low-power magnification, RG particles, NFB, and MS were present. Several biomaterial particles were embedded and interconnected by NFB trabeculae. Longitudinal section of bone core at $\times 20$; Azure B-methylene blue dye solution.

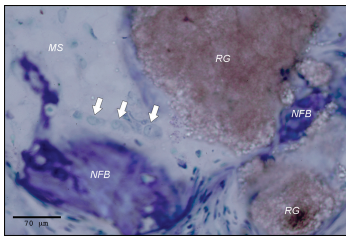


Fig. 5. Small areas of apposition bone growth were noted around most of the biomaterial particles not included in the NFB. Note the presence of active osteoblasts (white arrows) between 2 particles of RG, indicating intense osteogenesis. Stained with Azure B-methylene blue dye solution and observed at $\times 800$.

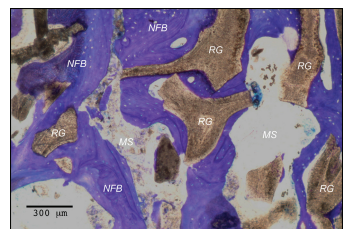


Fig. 6. A close contact, with no gaps, was observed at the bone-biomaterial interface, indicating the biocompatibility and the osteoconductive properties of the graft. Stained with Azure B-methylene blue dye solution and observed at $\times 100$.

Table 2. List of Anatomical Measures (Buccopalatal SW Measured in Millimeters at 10-mm Height Comprising the Residual Crestal Bone—SW), Number of Bone Walls Exposed by tSFE Procedure (Range 0–2) and Histomorphometric Data 6 Months After tSFE (Biopsy Area in mm², Percentage of NFB, MS, and RG)

Patient	Mean SW (mm)	Exposed Walls	Biopsy Area (mm ²)	NFB (%)	MS (%)	RG (%)
1	17.3	0	13.54	17.26	73.12	9.62
2	6.8	2	9.39	38.95	53.57	7.48
3	19.1	0	4.18	16.87	75.31	7.82
4	11.3	1	6.96	26.36	72.5	1.14
5	13.1	1	15.7	25.2	47.5	27.23
6	8.4	2	30.21	27.39	49.84	22.77
7	18.5	0	16.1	17.6	54.6	27.8
Total	13.5 ± 4.94	0.86 ± 0.9	13.72 ± 8.53	24.23 ± 7.95	60.92 ± 12.16	14.84 ± 10.82

infiltrated with an ascending series of LR White embedding resin (London Resin, Aldermaston, United Kingdom). After 20 days of infiltration and the final polymerization, undecalcified sections were cut at 50 μm using TT System (TMA2, Grottamare, Italy) and then ground down to about 30 μm using a series of polishing discs using a micro-grinding system (TMA2), followed by a final polish with 0.3- μm alumina. Specimens were cut vertically through the core centre. The histological slides were stained with Azure B-methylene blue dye solution.

Histomorphometry

The following variables were measured: (1) total area of the biopsy (in mm²), (2) percentage of newly formed bone (NFB), (3) percentage of connective tissue/marrow spaces (MS), and (4) percentage of residual graft (RG) particles.

The analysis was performed using a transmitted brightfield light microscope Axiolab (Zeiss, Oberkochen, Germany), connected to a high-resolution digital camera (FinePix S2 Pro; Fuji Film, Tokyo, Japan). A software with image capturing capabilities (Image-Pro Plus 6.0; Media Cybernetics, Bethesda, MD) was used to collect and analyze images. The software was calibrated for each experimental image by means of the “Calibration Wizard” feature, which reports the number of pixels between 2 selected points (cover slip with a square grid of 1 mm). The linear remapping of the pixel numbers

was used to calibrate the distance in microns.

Radiographic Measurements

Sinus dimensions were evaluated, using the template as a reference point, in the 4 CBCT cross sections corresponding to the exact position where the biopsy was retrieved and implant was placed. A single independent calibrated examiner (FB) measured (1) residual crestal height, (2) distance between buccal and palatal walls at 10-mm level (comprising the residual alveolar crest), using the distance measurement tool of an imaging software (Osirix MD; Pixmeo, Bernex, Switzerland), and (3) number of internal sinus bone walls in contact with the graft (2 = graft in contact with both lateral and medial walls 1 = graft in contact with lateral or medial wall 0 = graft not in contact with bone walls). Residual crestal height (CH) and sinus width (SW) are expressed in millimeters and represent the mean of 4 values.

Outcome Measures

This study tested the null hypothesis that there were no differences in the clinical outcomes among sinuses of different width against the alternative hypothesis of a difference.

Primary outcome measures:

- histomorphometric findings: NFB, MS, and RG particles

Secondary outcome measures:

- radiographic findings: efficacy of tSFE in elevating Schneiderian

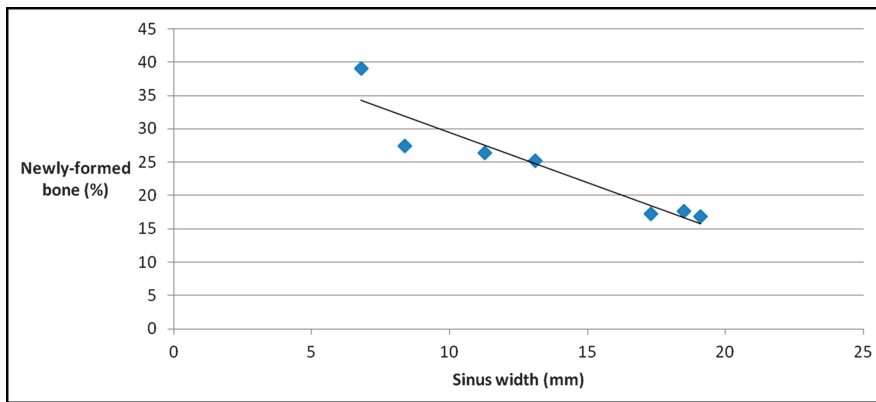


Fig. 7. A strong inverse correlation resulted between sinus buccopalatal width and quantity of new bone formation ($R^2 = 0.88$). Healing process, starting from the exposed bony walls with the stimulation of osteogenetic progenitor cells and the exposition of bone matrix, goes on in centripetal and apical directions: it can last for months after SFE.

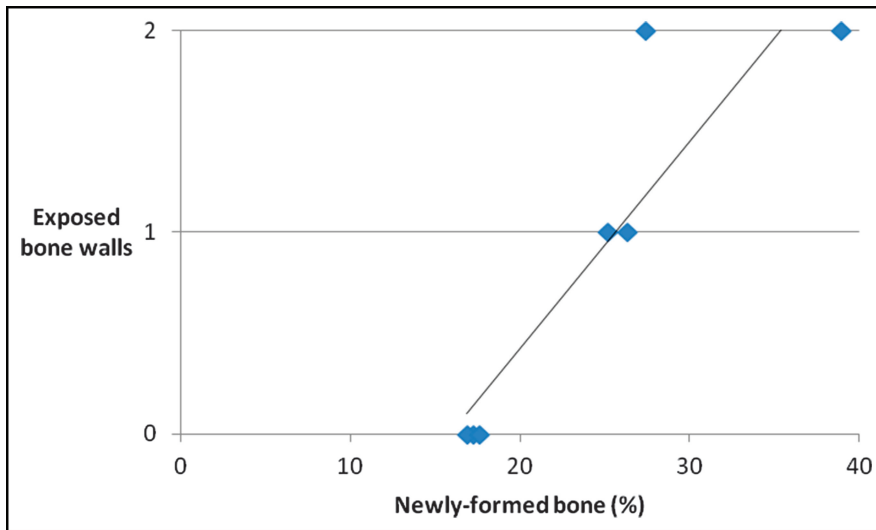


Fig. 8. The number of bone walls exposed by tSFE procedure and the quantity of new bone formation seemed to have a strong direct correlation ($R^2 = 0.82$). When the graft is not in contact with the bone walls, it receives less osteoprogenitor cells and blood supply, resulting in a slower cellular colonization and new bone formation.

membrane (contact between graft and sinus bone walls)

- implant failure: implant mobility or implant removal suggested by progressive marginal bone loss. Implant stability was tested by tightening abutment screws (35 N/cm) at prosthesis delivery
- any complications or adverse events were recorded and reported.

Statistics

Descriptive statistics was performed using a statistical software package (R

Software version 3.1.3; R Foundation for Statistical Computing, Vienna, Austria). The associations between histomorphometric and anatomical parameters were quantified by means of linear regression analysis. R-squared value was calculated to evaluate the fitting of data to the statistical model.

RESULTS

Study Population and Clinical Outcomes

Eight patients (5 women, 3 men; mean age 54.3 ± 9.4 ; median age 53)

were recruited and consecutively treated by 2 operators (T.L., 5 patients and C.S., 3 patients) between June and December 2013. The minimum follow-up for all patients was 1 year after implant loading. Five patients (62.5%) declared not to smoke, whereas 3 patients (37.5%) were light smokers (<10 cigarettes/d). After CBCT analysis, one patient was referred to the otorhinolaryngologist for sinus membrane thickening, and was cleared to proceed with the surgical procedure.

One membrane perforation occurred while performing the crestal access to the sinus: the procedure was aborted and patient dropped out. No other drop-outs occurred during the entire period of observation. No postoperative complications occurred.

All the implants were successfully in function 1 year after loading.

Radiographic Measurements

Mean SW (measured at 10-mm level comprising the residual alveolar crest) was 13.5 ± 4.9 mm. Mean CH measured 2.93 ± 0.86 mm and mean volume of grafting material inserted during tSFE was 1.43 ± 0.47 cc. Mean CH (residual bone + graft) 6 months after surgery measured 11.70 ± 1.55 mm (mean CH increase 8.77 ± 0.98 mm). Table 1 presents the main demographic characteristics and clinical outcomes of all patients.

From 6-months CBCT measurements, mean SW in sinuses ($n = 2$) where both bony walls (lateral and medial) showed close contact with the graft was 9.8 ± 2.9 mm (Fig. 1). Mean SW in sinuses ($n = 2$) where only one bone wall (lateral or medial) was in close contact with the graft was 12.4 ± 1.6 mm. Mean SW in sinuses ($n = 3$) showing no contact between the graft and sinus bony walls (lateral and medial) was 15.7 ± 3.4 mm (Fig. 2). SW and number of bone walls exposed by tSFE procedure showed a strong inverse correlation ($R^2 = 0.96$ —Fig. 3).

Histomorphometric Measurements

Seven specimens (one for each patient) were available for histological analysis. Graft particles were easily

distinguishable from the other components of the regenerated tissue 6 months after surgery (Fig. 4). Most of the particles were surrounded by NFB, with numerous osteoblasts, indicating active new bone formation on the external surface of the graft (Fig. 5). In most of the sections, graft particles were merged by NFB bridges (Fig. 6). The histomorphometric analysis showed an average percentage of NFB of 24.2% ($\pm 7.9\%$), a mean percentage of residual bone graft particles of 14.8% ($\pm 10.8\%$), with the rest of the specimens occupied by MS (60.9% $\pm 12.2\%$). Complete histomorphometric results are listed in Table 2.

The statistical analysis showed a strong inverse correlation between SW and new bone formation ($R^2 = 0.88$ —Fig. 7), and a strong direct correlation between the number of exposed bone walls and new bone formation ($R^2 = 0.82$ —Fig. 8).

DISCUSSION

Transcrestal maxillary sinus floor elevation represents a minimally invasive alternative to the lateral approach, with advantages in terms of lower morbidity for the patient, preservation of bone walls integrity and reduced risk of infection²²; on the other side, tSFE is a blinded technique and the operator has little control on entity and modality of Schneiderian membrane elevation. The original Summers technique⁵ had been modified and developed by numerous authors over time^{20,23–28} improving its potentiality, safety, and predictability. Recent systematic reviews showed that survival rate of implants associated to tSFE procedures is high and does not differ if compared with implants placed in combination with the lateral approach.^{7,22,29}

The aim of this proof-of-concept study was to analyze the correlation between sinus buccopalatal dimension and new bone formation after tSFE procedures: our hypothesis was that larger cavities are less favorable than narrow ones for new bone formation.

Average percentage of NFB at 6 months was 24.2%: this outcome is

comparable with the histomorphometric results obtained in other studies using the same biomaterial in sinus augmentation with lateral approach.^{30,31} Data analysis suggest a strong inverse correlation between SW and quantity of NFB after 6 months ($R^2 = 0.88$): the wider the sinus, the lower the percentage of NFB observed in the histomorphometric analysis. This finding is in accordance with a recent radiographic study on tSFE by Zheng et al³² and with the studies on the sinus elevation with lateral approach by Avila et al¹⁷ and Soardi et al,¹⁸ confirming with the histological evidence that sinus cavity width seems an influencing factor in terms of new bone formation. In fact, after membrane elevation and sinus grafting, healing process starts from the traumatized bony walls with the stimulation of osteogenetic progenitor cells and the exposition of bone matrix.³³ Osteogenesis starts from the maxillary bony walls and goes on in centripetal and apical directions: it can last for months after SFE.³⁴ Schneiderian membrane is a potential additional source of cells committed to the osteogenic lineage,^{35,36} but recent studies showed that its contribution to new bone formation plays a secondary role if compared with bone walls.^{6,37,38} In our study, the quantity of NFB seems to have a strong direct correlation with the number of exposed bony walls ($R^2 = 0.82$): the higher the number of bony walls in contact with the graft, the higher the percentage of NFB observed in histomorphometry. In larger sinuses, the graft appeared enclosed under a sort of dome deriving from the detachment of the Schneiderian membrane only from the sinus floor, receiving less osteoprogenitor cells and blood supply, and resulting in a slower cellular colonization and new bone formation.

Furthermore, a strong inverse correlation ($R^2 = 0.96$) was found between buccolingual SW and the number of bony walls exposed during the augmentation procedure. While in sinus floor elevation with lateral approach the surgeon elevates the membrane with manual instruments, having a direct vision

on the sinus bone walls exposure, in the transcrestal approach the membrane elevation is indirectly performed by the biomaterial with a very limited possibility for the operator to control its action. Hence, it is extremely important to understand which are the most favorable conditions where the transcrestal approach could adequately elevate the membrane, ensuring a predictable exposure of both lateral and medial sinus bone walls. The histological findings of this study, suggesting that the wider is the sinus, the lower is the number of exposed bone walls, are consistent with the results of the radiographic analyses by Spinato et al and Zheng et al.^{19,32}

However, the results of this study present 2 main limitations, which should be carefully regarded in the interpretation of the results. First of all, biopsies were collected at a single time point (6 months), so from these data it is not possible to discern if bone maturation will eventually occur in larger sinuses after a longer period or if wider cavities represent an unfavorable condition for new bone formation, such a sort of critical size defect. Moreover, the limited numerosity of the sample should be considered and data must be interpreted with caution: the findings from this proof-of-concept study will be useful to design prospective clinical trials with high statistical power.

CONCLUSIONS

Within the limitations of this study, in which a scarce number of patients were analyzed, transcrestal sinus augmentation showed more predictable results in narrow than in larger sinuses, both in terms of new bone formation and in terms of membrane elevation from the bone walls. Prospective trials validating the outcomes of this proof-of-concept study on an appropriate sample of patients are necessary, to suggest sound clinical indications for the daily practice.

DISCLOSURE

The authors claim to have no financial interest, either directly or

indirectly, in the products or information listed in the article.

APPROVAL

The study protocol was approved by the Regional Ethical Board (n. 002315).

REFERENCES

- Wallace SS, Froum SJ, Cho SC, et al. Sinus augmentation utilizing anorganic bovine bone (Bio-Oss) with absorbable and nonabsorbable membranes placed over the lateral window: Histomorphometric and clinical analyses. *Int J Periodontics Restorative Dent.* 2005;25:551-559.
- Tatum OH. "Lecture presented at the Alabama Implant Congress." 1976.
- Boyne PJ, James RA. Grafting of the maxillary sinus floor with autogenous marrow and bone. *J Oral Surg.* 1980;38:613-616.
- Tatum H Jr. Maxillary and sinus implant reconstructions. *Dent Clin North Am.* 1986;30:207-229.
- Summers RB. A new concept in maxillary implant surgery: The osteotome technique. *Compendium.* 1994;15:152, 154-156, 158 passim; quiz 162.
- Rong Q, Li X, Chen SL, et al. Effect of the Schneiderian membrane on the formation of bone after lifting the floor of the maxillary sinus: An experimental study in dogs. *Br J Oral Maxillofac Surg.* 2015;53:607-612.
- Del Fabbro M, Corbella S, Weinstein T, et al. Implant survival rates after osteotome-mediated maxillary sinus augmentation: A systematic review. *Clin Implant Dent Relat Res.* 2012;14:e159-e168.
- Ferrigno N, Laureti M, Fanali S. Dental implants placement in conjunction with osteotome sinus floor elevation: A 12-year life-table analysis from a prospective study on 588 ITI implants. *Clin Oral Implants Res.* 2006;17:194-205.
- Jensen OT, Shulman LB, Block MS, et al. Report of the Sinus Consensus Conference of 1996. *Int J Oral Maxillofac Implants.* 1998;13:11-45.
- Zitzmann NU, Schärer P. Sinus elevation procedures in the resorbed posterior maxilla: Comparison of the crestal and lateral approaches. *Oral Surg Oral Med Oral Pathol Oral Radiol Endod.* 1998;85:8-17.
- Pjetursson BE, Lang NP. Sinus floor elevation utilizing the transalveolar approach. *Periodontol 2000.* 2014;66:59-71.

- Mohan N, Wolf J, Dym H. Maxillary sinus augmentation. *Dent Clin North Am.* 2015;59:375-388.
- Bernardello F, Righi D, Cosci F, et al. Crestal sinus lift with sequential drills and simultaneous implant placement in sites with <5 mm of native bone: A multicenter retrospective study. *Implant Dent.* 2011;20:439-444.
- Trombelli L, Franceschetti G, Stacchi C, et al. Minimally invasive transcresal sinus floor elevation with deproteinized bovine bone or β -tricalcium phosphate: A multicenter, double-blind, randomized, controlled clinical trial. *J Clin Periodontol.* 2014;41:311-319.
- Trombelli L, Franceschetti G, Trisi P, et al. Incremental, transcresal sinus floor elevation with a minimally invasive technique in the rehabilitation of severe maxillary atrophy. Clinical and histological findings from a proof-of-concept case series. *J Oral Maxillofac Surg.* 2015;73:861-888.
- Watzek G, Fürst G, Gruber R. Biological basis of sinus grafting. In: Jensen OT, ed. *The Sinus Bone Graft.* 2nd ed. Hanover Park, IL: Quintessence; 2006:13-26.
- Avila G, Wang HL, Galindo-Moreno P, et al. The influence of the bucco-palatal distance on sinus augmentation outcomes. *J Periodontol.* 2010;81:1041-1050.
- Soardi CM, Spinato S, Zaffe D, et al. Atrophic maxillary floor augmentation by mineralized human bone allograft in sinuses of different size: An histologic and histomorphometric analysis. *Clin Oral Implants Res.* 2011;22:560-566.
- Spinato S, Bernardello F, Galindo-Moreno P, et al. Maxillary sinus augmentation by crestal access: A retrospective study on cavity size and outcome correlation. *Clin Oral Implants Res.* 2015;26:1375-1382.
- Trombelli L, Minenna P, Franceschetti G, et al. Transcresal sinus floor elevation with a minimally invasive technique. *J Periodontol.* 2010;81:158-166.
- Sentineri R, Lombardi T, Berton F, et al. Laurell-Gottlow suture modified by Sentineri for tight closure of a wound with a single line of sutures. *Br J Oral Maxillofac Surg.* 2016;54:e18-19.
- Tan WC, Lang NP, Zwahlen M, et al. A systematic review of the success of sinus floor elevation and survival of implants inserted in combination with sinus floor elevation. Part II: Transalveolar technique. *J Clin Periodontol.* 2008;35:241-254.
- Cosci F, Luccioli M. A new sinus lift technique in conjunction with placement of

265 implants: A 6-year retrospective study. *Implant Dent.* 2000;9:363-368.

24. Fugazzotto PA. Immediate implant placement following a modified trephine/osteotome approach: Success rates of 116 implants to 4 years in function. *Int J Oral Maxillofac Implants.* 2002;17:113-120.

25. Chen L, Cha J. An 8-year retrospective study: 1,100 patients receiving 1,557 implants using the minimally invasive hydraulic sinus condensing technique. *J Periodontol.* 2005;76:482-491.

26. Kfir E, Kfir V, Mijiritsky E, et al. Minimally invasive antral membrane balloon elevation followed by maxillary bone augmentation and implant fixation. *J Oral Implantol.* 2006;32:26-33.

27. Lee S, Kang-Lee G, Park KB, et al. Crestal window sinus lift: Minimally invasive, predictable, and systematic approach to sinus grafting. *J Impl Adv Clin Dent.* 2009;1:75-88.

28. Sentineri R, Dagnino G. Sinus physiolift: A new technique for less invasive great sinus augmentation with crestal approach. *J Osteol Biomat.* 2011;2:69-75.

29. Del Fabbro M, Wallace SS, Testori T. Long-term implant survival in the grafted maxillary sinus: A systematic review. *Int J Periodontics Restorative Dent.* 2013;33:773-783.

30. Nevins M, Camelo M, De Angelis N, et al. The clinical and histologic efficacy of xenograft granules for maxillary sinus floor augmentation. *Int J Periodontics Restorative Dent.* 2011;31:227-235.

31. Testori T, Iezzi G, Manzon L, et al. High temperature-treated bovine porous hydroxyapatite in sinus augmentation procedures: A case report. *Int J Periodontics Restorative Dent.* 2012;32:295-301.

32. Zheng X, Teng M, Zhou F, et al. Influence of maxillary sinus width on transcresal sinus augmentation outcomes: Radiographic evaluation based on cone beam CT. *Clin Implant Dent Relat Res.* 2016;18:292-300.

33. Schenk RK. Cytodynamics and histodynamics of primary bone repair. In: Lane JM, ed. *Fracture Healing.* 1st ed. New York, NY: Churchill Livingstone; 1987:23-32.

34. Haas R, Baron M, Donath K, et al. Porous hydroxyapatite for maxillary sinus augmentation: A comparative histomorphometric study in sheep. *Int J Oral Maxillofac Implants.* 2002;17:337-346.

35. Gruber R, Kandler B, Fuerst G, et al. Porcine sinus mucosa holds cells

that respond to bone morphogenetic protein (BMP)-6 and BMP-7 with increased osteogenic differentiation in vitro. *Clin Oral Implants Res.* 2004; 15:575–580.

36. Derjac-Aramă AI, Sarafoleanu C, Manea CM, et al. Regenerative potential of human Schneiderian membrane:

Progenitor cells and epithelial-mesenchymal transition. *Anat Rec (Hoboken)*. 2015;298:2132–2140.

37. Scala A, Botticelli D, Faeda RS, et al. Lack of influence of the Schneiderian membrane in forming new bone apical to implants simultaneously installed with sinus floor elevation: An

experimental study in monkeys. *Clin Oral Implants Res.* 2012;23:175–181.

38. Jungner M, Cricchio G, Salata LA, et al. On the early mechanisms of bone formation after maxillary sinus membrane elevation: An experimental histological and immunohistochemical study. *Clin Implant Dent Relat Res.* 2015;17:1092–1102.