UNIVERSITÀ DEGLI STUDI DI TRIESTE

Multiparametric US for scrotal diseases

This is the peer reviewed (post-print) version of the following article:

Original
Multiparametric US for scrotal diseases / Bertolotto, M., Muça, M., Currò, F., Bucci, S., Rocher, L., Cova, M.A.. - In: ABDOMINAL RADIOLOGY. - ISSN 2366-004X. - STAMPA. - 43:4(2018), pp. 899-917. [10.1007/s00261-018-1510-7]

Availability:
This version is available at: 11368/2929130 since: 2018-09-14T13:04:28Z

Publisher:

Published
DOI:10.1007/s00261-018-1510-7

Terms of use:

Some rights reserved. More details in the PostPrint rights section below.

License:
Digital Rights Management not defined

Publisher copyright

-.-

(Article begins on next page)

21 October 2026

arTs Università degli Studi di Trieste
Archivio della ricerca – postprint

Multiparametric US for scrotal diseases

Michele Bertolotto,[1] Matilda Muça,[1] Francesca Currò,[1] Stefano Bucci,[2] Laurence Rocher,[3] Maria Assunta Cova[1]

[1]Department of Radiology, University of Trieste, Ospedale di Cattinara, Strada di Fiume 447, 34149 Trieste, Italy
[2]Department of Urology, University of Trieste, Ospedale di Cattinara, Strada di Fiume 447, 34149 Trieste, Italy
[3]Department of Radiology, Hôpital de Bicêtre, 78 Avenue du General Lecters, 94270 Paris, France

Abstract

Multiparametric US is increasingly recognized as a valuable problem-solving technique in scrotal pathologies. Compared to conventional Doppler modes, contrast-enhanced ultrasonography (CEUS) has higher sensitivity in assessing the presence or absence of flows, and to improve differentiation between poorly vascularized tumors and non-neoplastic, avascular lesions. Characterization of benign and malignant complex cysts is improved. In trauma patients, CEUS can help evaluating the viability of testicular parenchyma. In patients with severe epididymo-orchitis, it allows unequivocal assessment of post-inflammatory ischemic changes and abscess formation. CEUS does not add significantly to conventional Doppler modes in spermatic cord torsion. Attempt of differentiating benign and malignant tumors remains a research tool. In the clinical practice, elastography has a limited role for tumor characterization. The majority of malignant tumors are stiff at elastography, but they may display soft areas, or appear globally soft. A quantitative evaluation of testicular stiffness is feasible using shear-wave elastography. Potential clinical applications for elastographic modes could include work-up of infertile patients.

Key words: CEUS—Elastography—Scrotal pathologies—Multiparametric US

Abbreviations

CEUS	Contrast-enhanced ultrasonography
MRI	Magnetic resonance imaging
US	Ultrasonography

Correspondence to: Michele Bertolotto; *email:* bertolot@units.it

Ultrasound contrast agents are gas-filled microbubbles composed of a shell of biocompatible materials which contains gases of low solubility and diffusivity [1, 2]. Microbubbles behave as an active source of sound and modify the characteristic signature of the echo from blood. For CEUS examinations, US equipment must have contrast-specific modes designed to allow separation between non-linear response induced by microbubbles and signal from the tissues. Since microbubbles display their resonance peak at ultrasonographic frequencies used for abdominal imaging, abdominal applications are prevailing, particularly in evaluation of liver and kidney. However, a number of smaller bubbles resonate at higher frequencies, making feasible CEUS of superficial structures such as small bowel, carotid artery, eye, superficial nodes, joints, and testis [3, 4]. Regarding scrotal pathologies, there is increasing evidence that CEUS is a cost-effective, easy-to-use, reproducible means which helps solving equivocal cases on conventional ultrasonographic modes [3]. As it has been shown for abdominal organs, its strength is the ability to detect slow flows in poorly vascularized lesions with sensitivity at least equal, if not superior, to contrast-enhanced magnetic resonance imaging (MRI) [5–7], much higher compared to conventional Doppler modes. Contrast-enhanced ultrasonography is used off-label for scrotal imaging. Its employment, however, is based on several publications and supported by international guidelines [3]. Microbubbles are administered safely in various applications with minimal risks to the patients. They have a very low rate of anaphylactoid reactions (1:70,000 patients, 0.0014%) [8], significantly lower than the rate with iodine-based and comparable with gadolinium-based contrast agents [9, 10]. Microbubble contrast agents are eliminated through the lungs and liver. Until metabolized, they act as blood pool agents, and they are neither excreted through the kidneys nor are able to enter the interstitial spaces and can be safely administered to patients with renal insufficiency [3, 11].

Elastography visualizes differences in the biomechanical properties of tissues. Elastographic techniques can be classified in two main categories, strain and shear-wave elastography [12]. Strain elastography provides qualitative results. A stress is applied by repeated manual compression of the transducer, and the amount of lesion deformation relative to the surrounding normal tissue is evaluated and displayed in color. Shear-wave elastography uses an acoustic radiation force pulse to produce a longitudinal strain with known properties, and the speed of shear (transversal) waves is measured, propagating perpendicular to the longitudinal strain. This measurement is used to obtain a quantitative estimation of tissue stiffness at elastography [12, 13]. While several investigations explored the use of strain elastography in imaging the testis [14–16], only few studies dealt with use of shear-wave modes [17, 18].

While gray-scale and color Doppler modes are the mainstay for scrotal imaging, it is now established that simultaneous use of conventional modes, elastography, and CEUS increases the diagnostic capabilities of the technique. This approach is increasingly used in the clinical practice, since elastographic and contrast-specific modes are now available for imaging superficial tissues in the majority of equipment. The simultaneous use of different US techniques is called multiparametric US [19]. In this review article, the application of multiparametric US for scrotal imaging is illustrated, and limitations are discussed.

Examination technique

CEUS is performed after a preliminary gray-scale and color Doppler evaluation using contrast-specific modes, with contrast-enabled transducers. The power of the US beam is set to obtain minimum microbubble destruction with the available equipment. A low mechanical index (MI) is used to obtain minimum microbubble destruction. MI values vary depending on the characteristics of the equipment, transducer, and contrast mode. Generally, MI values of 0.08–0.05 are set, but there are machines requiring higher (up to MI $\leq$ 0.3) or lower (MI $\geq$ 0.02) acoustic pressures [20]. As a relatively small number of smaller microbubbles resonate at the frequency used for imaging superficial structures, a higher amount of contrast is required to obtain an adequate enhancement of the scrotal content, compared to abdominal organs. Typically, up to 4.8 mL contrast medium is injected using a 20-gage cannula, followed by a 10-mL saline solution flush.

A different examination technique is used depending on the particular clinical problem. Continuous observation is usually performed from the time of arrival of the microbubbles until they disappear. Images and cine clips of the entire CEUS examination are stored digitally. In most of cases, CEUS is performed on a target lesion identified at US. An imaging plane is fixed, and the lesion investigated from the time of appearance up to disappearance of microbubbles. If the enhancement characteristics of the testes have to be compared, a ''spectacle'' view of both testes is obtained with a transverse scan plane. If CEUS is performed to identify ischemic areas or abscess formation, a sweep on the entire affected testis, or on both testes, is performed.

With strain elastography, lesion is assessed by applying a gentle pressure adjusted according to a visual indicator for compression strain on the video screen. The stiffness at elastography of the lesion is compared to the surrounding tissue and displayed by color coding. When most of the testis is involved, the contralateral testis is used for comparison. Semi-quantitative measurement of the elasticity score in relation to healthy testicular tissue can be obtained [21].

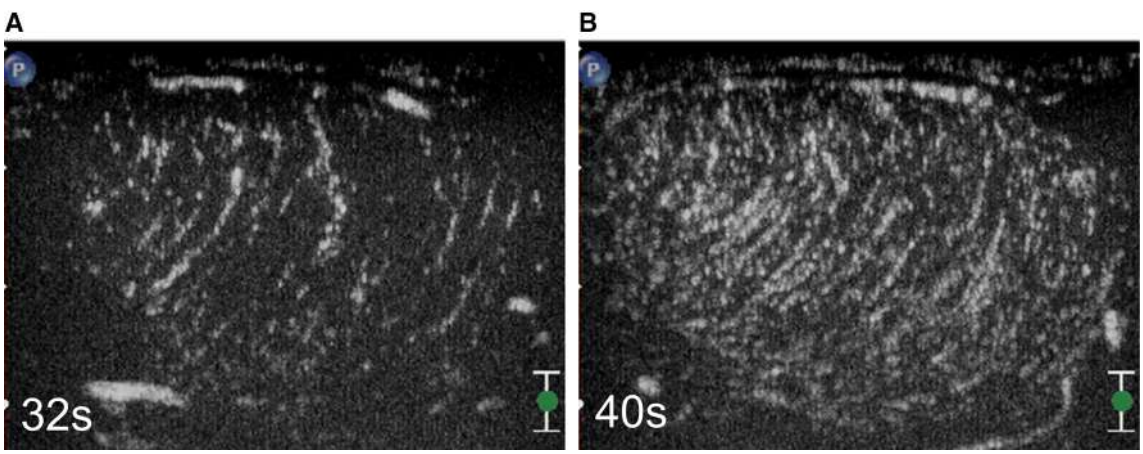

Fig. 1. Normal testicular anatomy at CEUS. Testicular arteries enhance first (**A**) followed within few seconds by complete fill-in of the parenchyma (**B**).

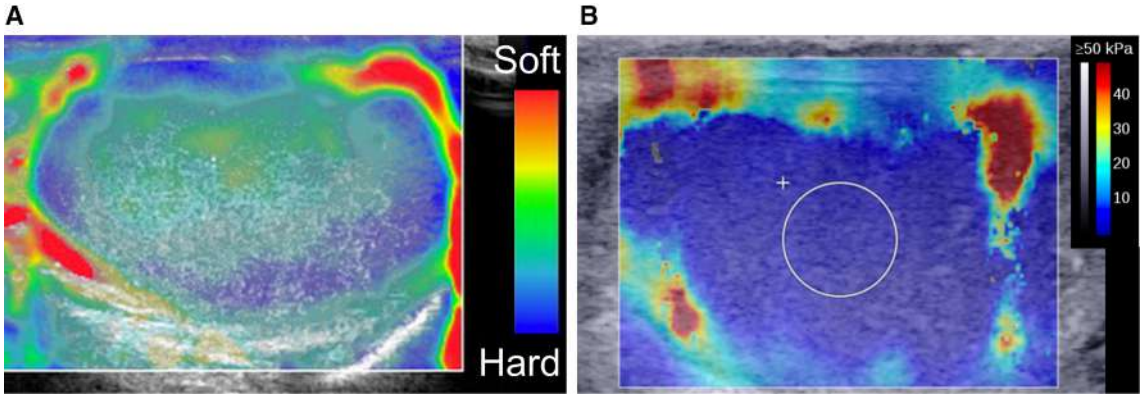

Fig. 2. Normal testicular anatomy at strain and at shear-wave elastography. **A** Strain elastography. Stiff regions are displayed in blue. **B** Shear-wave elastography. Stiff regions are displayed in red. The testis is homogeneously soft with a subalbugineal stiffer rim. The measure in the central portion of the testis in the shear-wave image shows normal average elasticity value of 2.2 kPa.

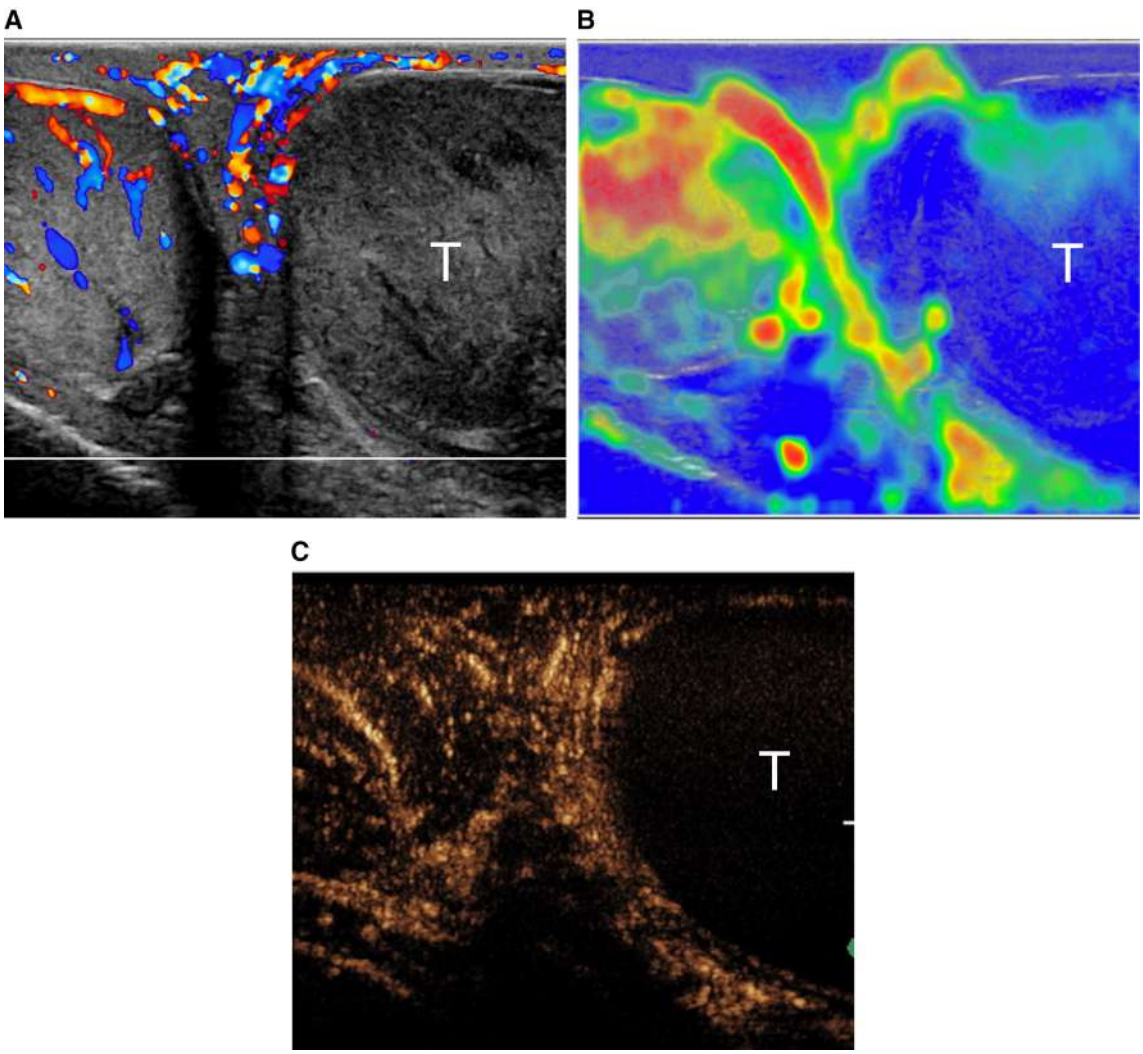

Fig. 3. Patient with longstanding high-degree testicular torsion investigated with multiparametric US. **A** Color Doppler US shows avascular, hypoechoic inhomogenous left testis (T).**B** Strain elastography shows the left testis (T) stiffer than the contralateral. **C** CEUS confirms lack of vascularity of the left testis (T).

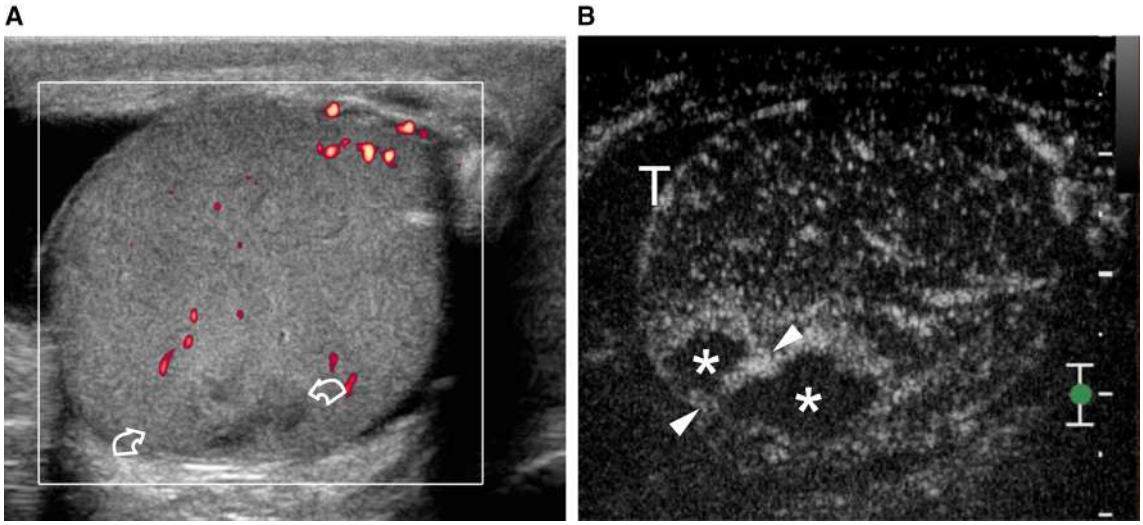

Fig. 4. A 52-year-old man with right segmental testicular infarction. **A** Color Doppler US image shows inhomogeneous lesion (curved arrows) lacking color signals. The testis appears globally hypovascular. **B** CEUS image shows two adjacent ischemic lobules (asterisks) separated by an intervening area of viable parenchyma (arrowheads). The vascularization of the remaining portions of the testis is normal.

In our practice, shear-wave elastography is preferably conducted in the transverse plane to standardize the technique and reduce measurement variation. Images are generated without compression, because pressure can modify elastographic stiffness values. Three measurements are obtained in the center of the testis and the average considered as the final result [17, 22]. Red means stiff by convention, and blue a soft tissue. The data acquisition procedure takes approximately 2–3 min [17].

Normal anatomy

After microbubble administration, the testis and epididymis enhance quickly and intensively. Enhancement typically fades within 2 min [23, 24]. As shown in the animation (CLIP#1), arteries enhance first, followed within few seconds by complete fill-in of the parenchyma, while scrotal wall enhancement is less pronounced (Fig. 1).

Normal testis is relatively soft at elastography with a stiffer subalbugineal ring which appears stiffer both on strain and shear-wave modes. This is possibly due to a higher number of connective septa arising from the tunica albuginea (Fig. 2). Shear-wave velocity measurements have been done in healthy man for determination of standard values. Trottmann et al. [22] investigated 66 volunteers of different ages (range: 20–86 years old). Mean shear-wave velocity values differed between the center and the periphery of the testis, but were not dependent from age. Conclusions were that shear-wave elastography is feasible in the assessment of testicular stiffness, provided that measurements are performed in the same region.

High-degree testicular torsion

Testicular torsion or, more accurately, torsion of the spermatic cord, is not an all-or-none phenomenon, but a complex condition with a spectrum of clinical and sonographic presentations [25]. In lesser degrees of torsion, the arterial supply can be initially maintained, as the high pressure within the testicular artery prevents complete compression and closure in the spermatic cord. In higher degree torsion, arterial and venous flows in the affected testis are absent. High-degree testicular torsion (also called complete torsion) is therefore defined when the degree of rotation is high enough to acutely halt testicular blood flow [26]. Low-degree torsion (also called partial torsion) is diagnosed when intratesticular flow is still present [27].

An animal study shows that a torsion of the spermatic cord of 450° or more is necessary to cause disappearance of both arterial and venous flows in the testis [26].

Microbubble contrast agents are extremely effective in assessing organ perfusion with the possibility to detect, in principle, echoes from individual bubbles [28]. Since 1996, Coley et al. [29] and O'Hara et al. [30] suggested use of CEUS for the diagnosis of testicular ischemic changes. Considering these experimental studies, Paltiel et al. claim use of CEUS for suspected testicular torsion in small testes, like in prepuberal children, in whom conventional Doppler modes do not ensure an optimal assessment of vascular flow [31]. These experimental studies, however, dealt with use of microbubbles to increase Doppler signal with conventional color Doppler modes. Recent high-end equipment has much higher sensitivity for slow flows, which are detected also in

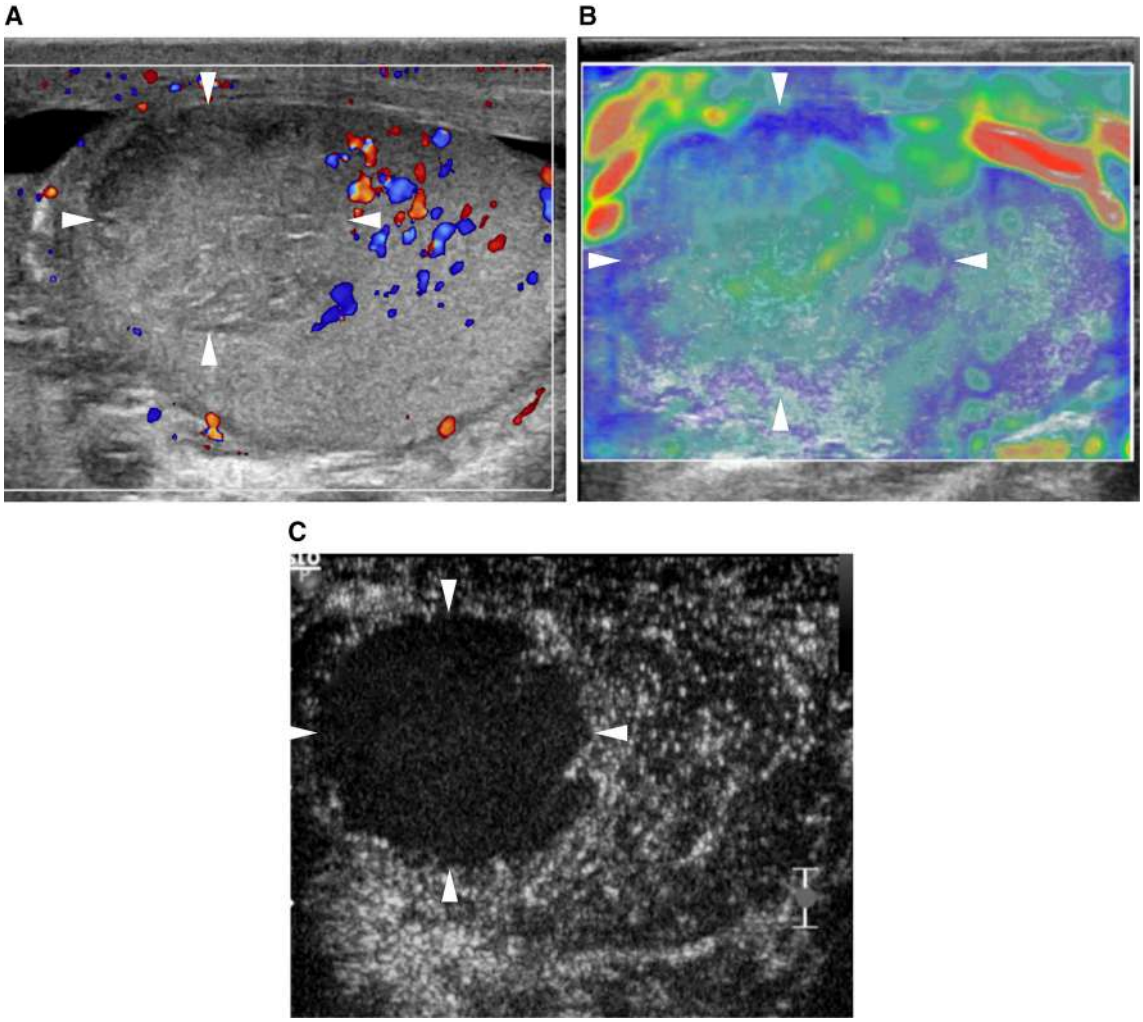

Fig. 5. Segmental testicular infarction in a patient presenting with right acute scrotal pain lasting for 2 h. **A** Color Doppler ultrasonography reveals a slightly inhomogenous, barely visible area (arrowheads) in the upper pole of the testis in which Doppler signals are lacking. **B** Strain elastography shows an area (arrowheads) with the same stiffness of the parenchyma and a slightly stiffer peripheral zone (arrowheads). **C** CEUS shows a completely avascular lesion (arrowheads).

prepuberal boys without need for contrast agent injection. In men, testicular torsion is investigated with CEUS in a limited number of case reports. Cosgrove et al. and Catalano et al. altogether reported on seven patients with high-degree testicular torsion, respectively, investigated with CEUS [32], [33]. Microbubble injection did not add significantly to conventional Doppler modes. Other investigations drew similar conclusions [23, 34, 35].

In patients with testicular torsion, elastographic changes are consistent with finding at palpation. The parenchyma becomes edematous, with increased consistency at palpation, and a stiffer appearance at elastography (Fig. 3).

Elastographic evaluation may have a prognostic value for estimation of testicular parenchymal damage. According to the result in rabbit of Zhang et al., shear-wave elastography is a method for testicular spermatogenesis evaluation after torsion [36]. These experimental findings, however, have not been validated in men, yet.

Low-degree testicular torsion

Diagnosis of low-degree testicular torsion is challenging, and remains controversial. Only two cases evaluated with CEUS have been reported in men [33, 34]. Experimental studies in rabbit show that evaluation of time–intensity curves after microbubble injection could perform better than conventional Doppler modes [29, 31]. In the clinical practice, however, diagnosis of low-degree torsion is obtained combining detection on the symptomatic side of monophasic waveforms, increased resistance index with decreased diastolic flow velocities, diastolic flow reversal, or post-stenotic flows associated with the "whirlpool sign," i.e., demonstration of the funicular

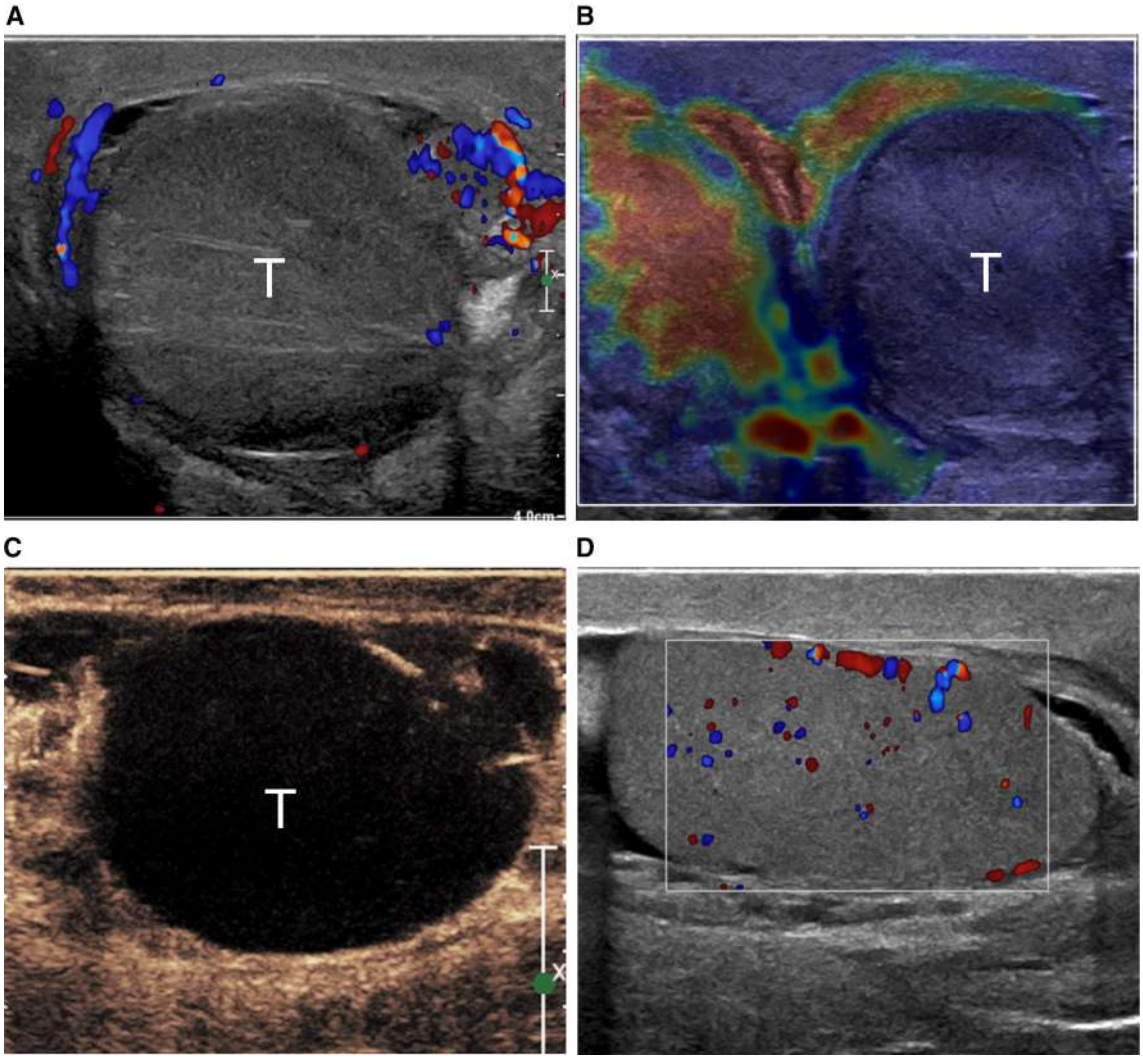

Fig. 6. Patient with post-inflammatory infarction of the left testis investigated with multiparametric US. **A** Color Doppler US shows avascular, hypoechoic inhomogenous left testis (T). **B** Strain elastography shows the left testis (T) stiffer than the contralateral right testis. **C** CEUS confirms lack of enhancement of the left testis (T). **D** The contralateral right testis is normal.

vessels wrapping around the central axis of the twisted spermatic cord [37].

Segmental testicular infarction

Segmental testicular infarction presents clinically with acute scrotal pain. Early after the onset of symptoms, infarction might be barely visible on gray-scale US, while later it is usually hypoechoic. Hyperechoic areas consistent with hemorrhage may be present. Regardless of gray-scale appearance, segmental testicular infarction is invariably hypovascular or avascular at color Doppler interrogation. The differential diagnosis from a hypovascular tumor may be problematic in rounded lesions and when vascularity is not completely absent [37]. CEUS proved effective in differentiating segmental testicular infarction from hypovascular tumors when appearance at conventional Doppler modes is equivocal.

While a minority of small testicular tumors may not show flow on color Doppler interrogation, virtually all testicular tumors display enhancement on CEUS, with the exception of any cystic component and regions of necrosis [20]. As shown in Fig. 4-5, and in CLIP#2, CEUS is able to confirm the lack of enhancement of the lesion, showing distinct non-enhancing parenchymal lobules, occasionally separated by normally vascularized parenchyma [38].

Subacute segmental infarction typically shows a perilesional rim enhancement which progressively disappears during the follow-up. Later on, the lesion decreases in size, takes a wedge-shaped appearance, and eventually disappears, sometimes leaving a parenchymal scar. Follow-up is

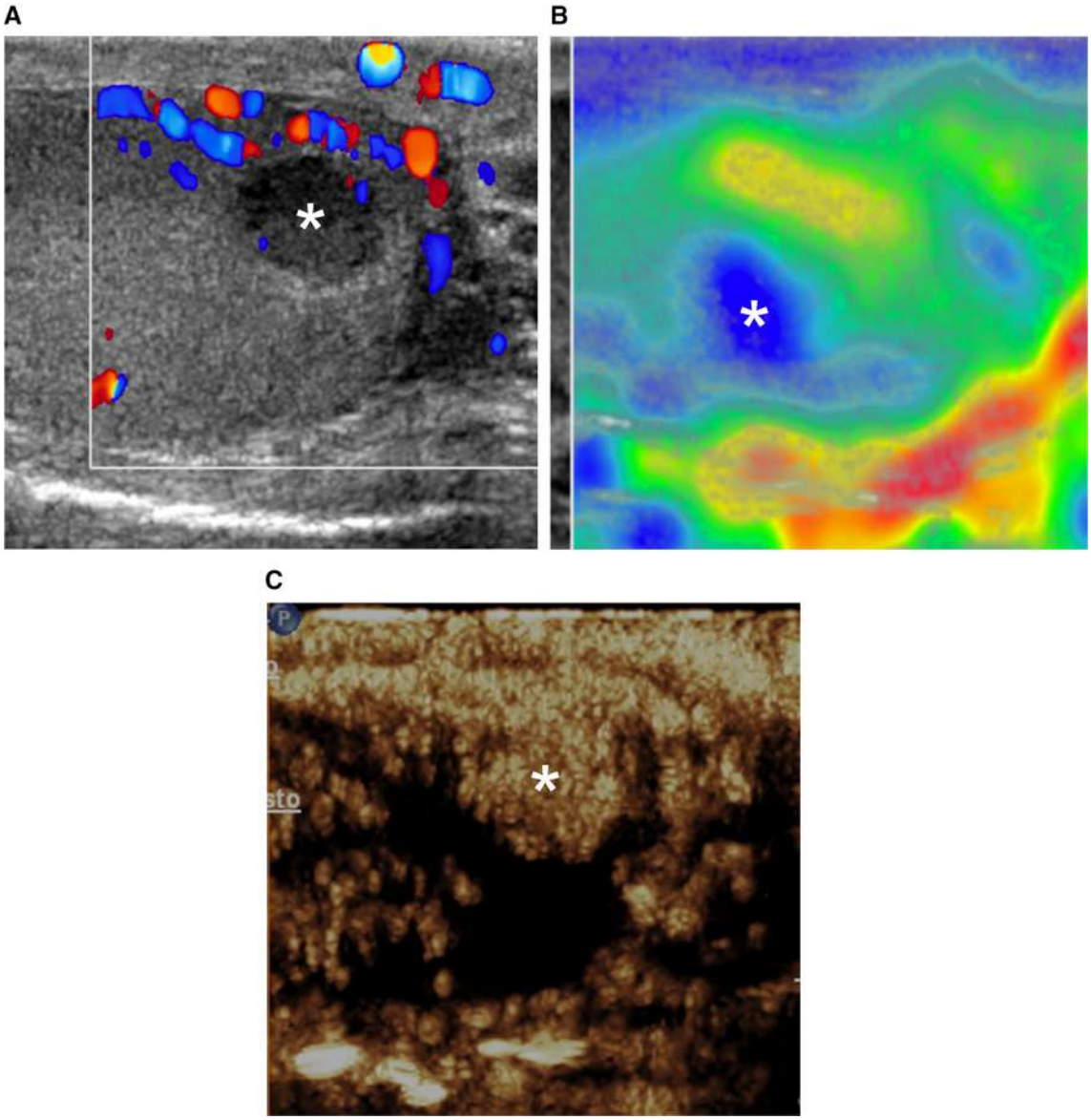

Fig. 7. Histologically proved seminoma. **A** Color Doppler US fails to detect lesion vascularity (asterisk). **B** Strain elastography shows a stiff lesion (encoded blue, asterisk). **C** CEUS shows a hypervascular lesion (asterisk).

always necessary to document the evolution of the lesion. Changes in lesion shape, vascular features, and size reduction during the follow-up confirm the diagnosis [38].

At elastography, early after the onset of pain segmental testicular infarction can be stiff at the periphery and soft in the center, likely reflecting the presence of edema and hemorrhagic changes (Fig. 4). Later on, the lesion is usually soft [18, 39].

Global testicular infarction

In rare cases, a complete infarction of a testis is identified not caused by torsion of the spermatic cord. As shown in CLIP#3 and in Fig. 6, a relatively common cause is post-inflammatory global infarction, a rare complication of severe epididymo-orchitis with impaired venous outflow leading to venous infarction. Other possible reasons are systemic embolization and vasculitides. CEUS is effective in confirming the absence of flows within the testicular parenchyma [40]. In the clinical practice, however, enough clinically useful information is usually obtained with conventional Doppler modes. The ischemic testis is usually hard at palpation and stiff at elastography. Soft areas are identified as necrosis and colliquation take place.

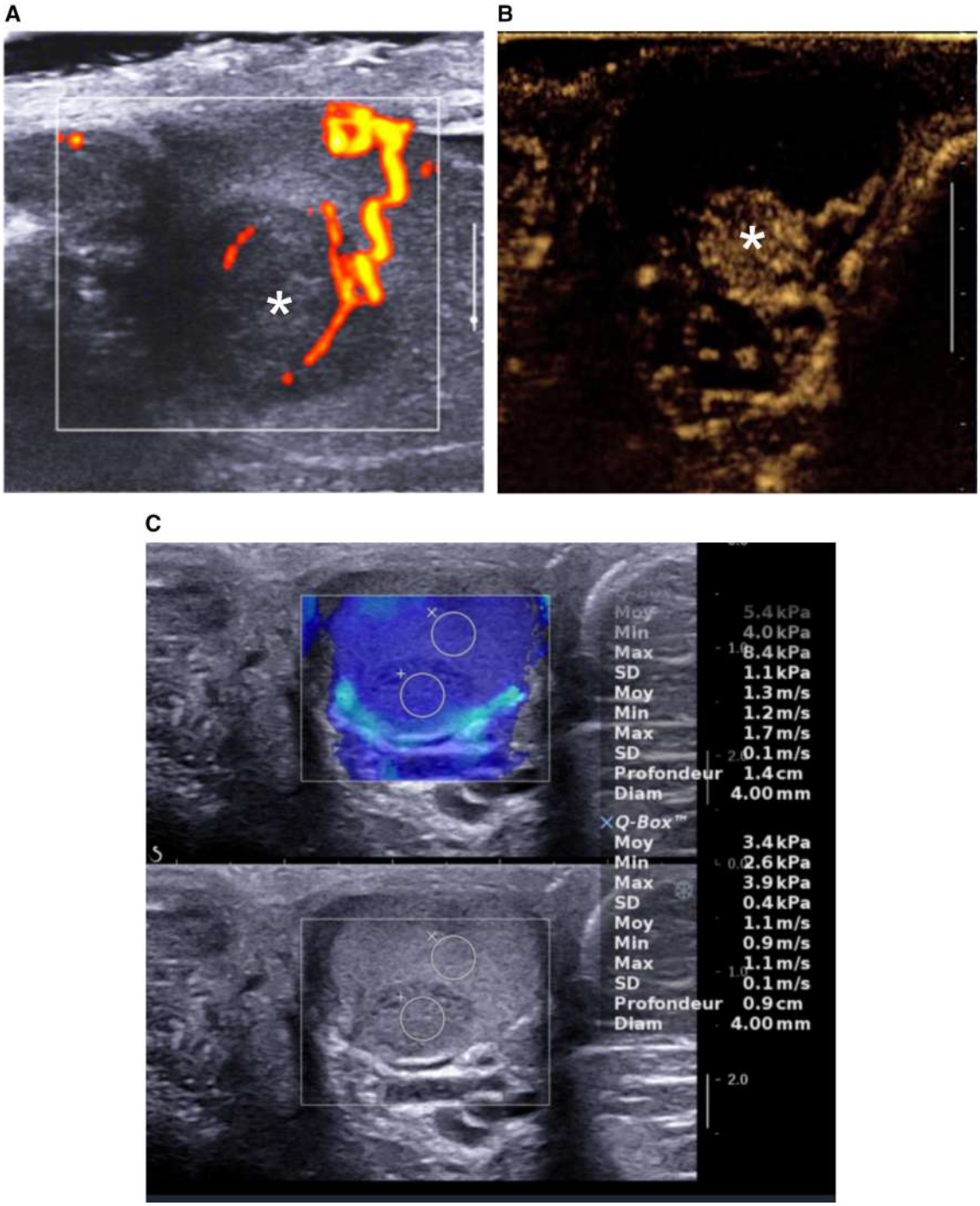

Fig. 8. Non-palpable Leydig-cell tumor identified incidentally in a patient investigated for infertility. **A** Color Doppler US shows a vascularized hypoechoic testicular nodule (asterisk). **B** CEUS image obtained early after the arrival of microbubbles shows a hypervascular nodule with early enhancement (asterisk). **C** Shear-wave elastography shows that, although it was non-palpable, the tumor is stiffer than the parenchyma (average stiffness: 5.4 vs. 3.4 kPa for the tumor and for the parenchyma, respectively).

Tumors

Using latest generation US equipment, the vast majority of testicular tumors display vascularity at color Doppler interrogation. Small tumors, however, and tumors with small vessels and slow flows may present with lack of Doppler flow. Horstman et al. reported that while color signals were present in 95% of tumors larger than 1.6 cm, Doppler flow was lacking in 86% of tumors less than

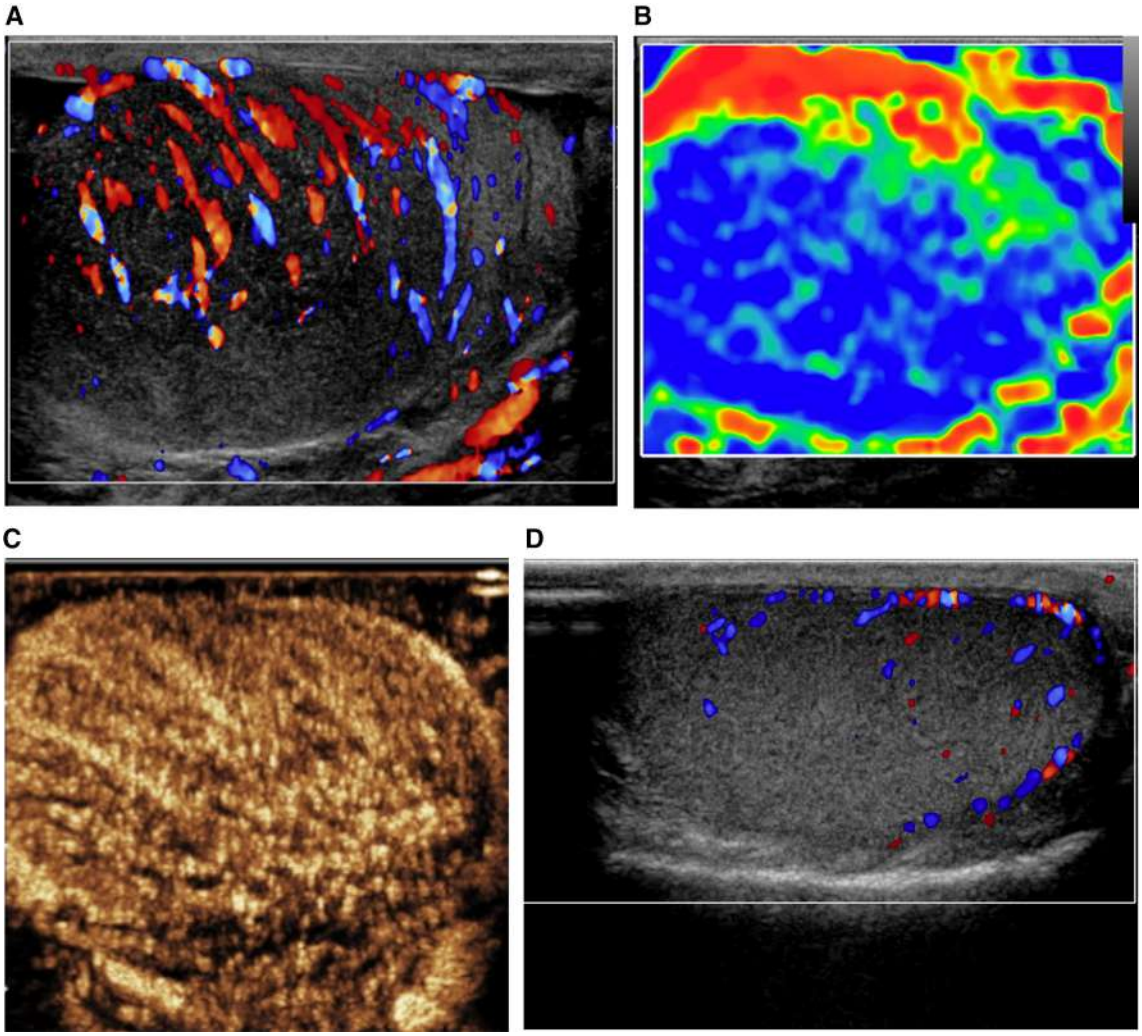

Fig. 9. Histologically proved diffuse large-B-Cell lymphoma of the left testis. **A–C** left testis. **A** Color Doppler US shows enlarged left testis with increased vascularity. No distinct masses are seen. **B** Strain elastography shows increased stiffness of the entire left testis (encoded blue). **C** CEUS confirms color Doppler findings, showing a globally hypervascular left testis, consistent with diffuse tumor infiltration. **D** Color Doppler interrogation of the normal right testis.

1.6 cm [41]. Although with modern equipment the sensitivity of Doppler modes is increased, characterization of lesions lacking Doppler flow remains challenging. In a recent analysis, Ma et al. show that a substantial proportion of hypoechoic testicular lesions lacking Doppler signals are malignant [42].

Current evidence shows that virtually all testicular and extratesticular tumors enhance at CEUS making differentiation with non-enhancing, likely benign lesions feasible [19, 24, 43–45] (Fig. 7). Both benign and malignant lesions enhance (Figs. 7 and 8).

In patients with testicular tumors, CEUS helps identifying particular patterns of vascularization. In primary testicular tumors, intralesional vessels usually display a tortuous pattern on both color Doppler and CEUS, described as "crossing" appearance [46]. Exceptions are infiltrative neoplasms such as lymphoma, granulocytic sarcoma, and plasmocytoma, which appear as solitary or multiple hypervascular lesions, or as diffuse infiltration of the entire testis [47, 48]. In most of cases, a non-branching linear pattern is seen in the intratumoral blood vessels, which is confirmed at CEUS (Fig. 9). These features are appreciable also in extratesticular infiltrative neoplasms, such as lymphoma of the spermatic cord, epididymis, and scrotal wall [49, 50]. Lesions are hard at palpation and with increased stiffness at elastography [48].

Several investigations attempted evaluation of time–intensity curves after microbubble contrast injection to differentiate benign from malignant solid testicular neoplasms, especially seminoma from leydigoma [44, 51, 52]. Although these results are promising, quantification remains a research tool. Indeed, both qualitative and quantitative CEUS analyses overlap between different histological types.

There are few studies with conflicting results in terms of the diagnostic performance of elastography in the

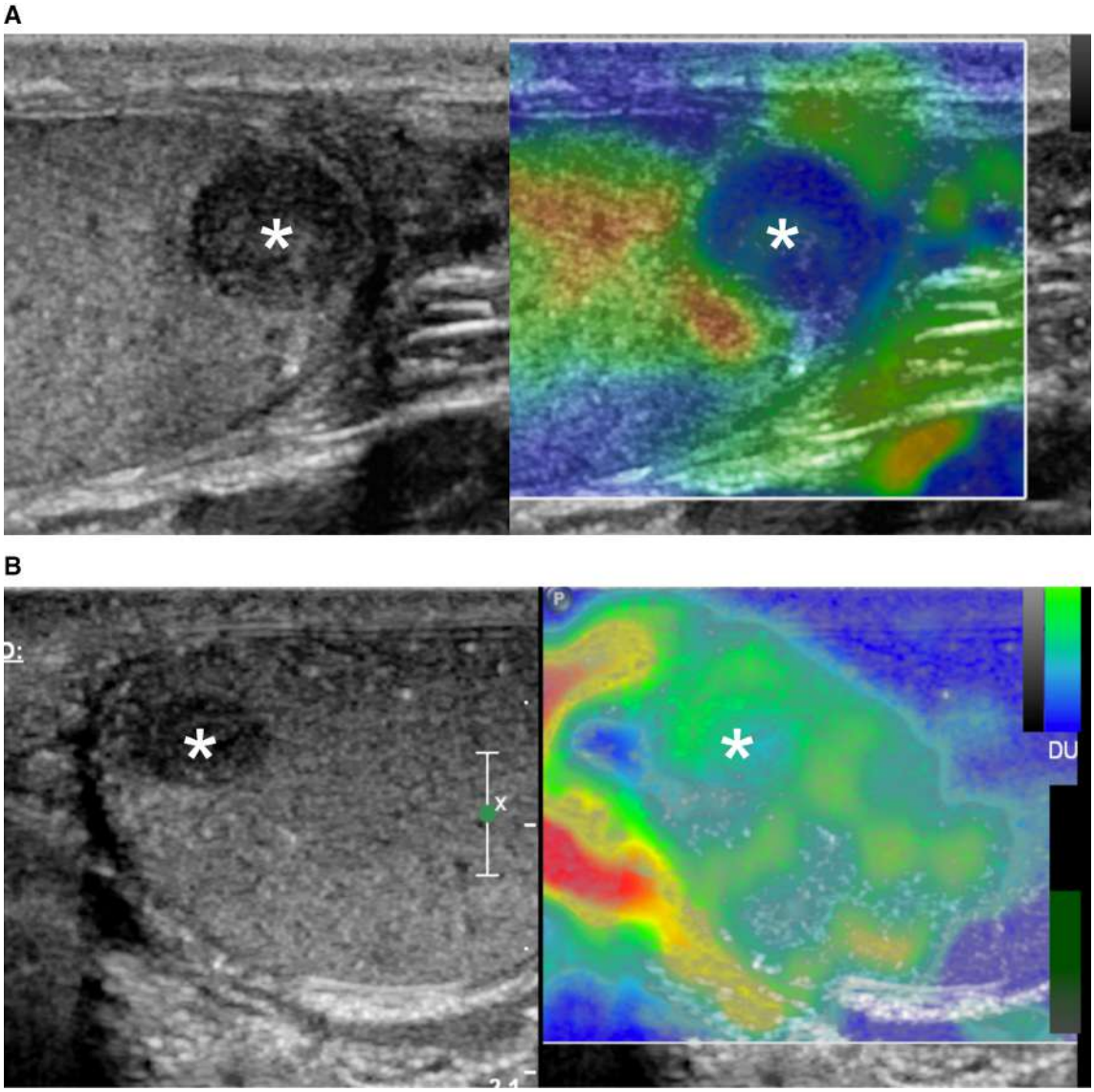

Fig. 10. Histologically proved pure seminomas. Features at strain elastography. **A** Palpable seminoma stiff at elastography (asterisk, encoded in blue). **B** Non-palpable seminoma soft at elastography (asterisk, encoded in green).

evaluation of the testicular lesions. Some of them [15, 19, 53, 54] claim that a very high percentage of malignant lesions, approaching 100%, appears stiff at elastography. Other investigations, however, demonstrated that malignant lesions can be soft, while a number of non-neoplastic lesions are stiff, including cysts, hematoma, infarction, rete testis, and scars [55]. Moreover, lesions can change in consistency over time. In our experience, lesion position matters. Characterization of subalbugineal findings as stiff or soft may be difficult at elastography because the normal testicular parenchyma is stiffer in that region. Peripheral lesions, however, are easily palpated during the physical examination of the patient. Current evidence suggests that lesions stiff at elastography are more likely to be malignant, and "soft" lesions more likely benign, but overlapping is consistent (Figs. 10 and 11). When the different investigations are considered together, the pooled sensitivity and specificity of elastography for characterization of testicular lesions as benign or malignant vary from 59%–98% and 25%–38%. Elastography can therefore increase the potential of multiparametric ultrasonography in scrotal lesion characterization, but alone is not able to differentiate malignant from benign lesions [21].

Complex cystic lesions

Cysts of the epididymis, tunica albuginea, and testis are a very common cause of scrotal swelling [56]. While simple cysts are invariably benign, any lesion complexity raises concern for a cystic tumor [43, 57, 58]. Amorphous material such as blood clot, mucoid or keratinous fluid

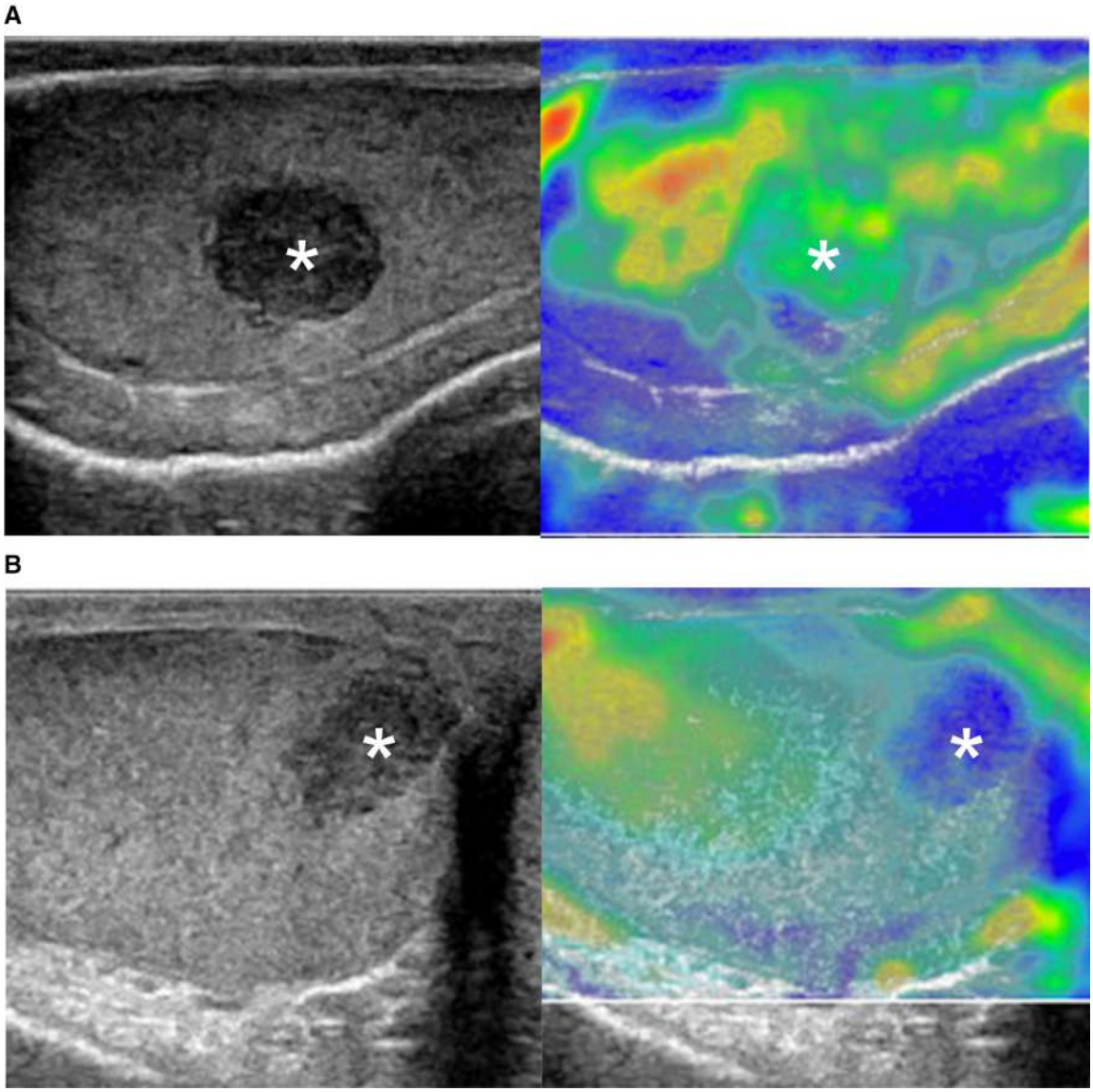

Fig. 11. Histologically proved leydigomas. Features at strain elastography. **A** Non-palpable leydigoma soft at elastography (asterisk, encoded in green). **B** Palpable leydigoma stiff at elastography (asterisk, encoded in blue).

may present as hypomobile, echogenic content mimicking vegetations. Mature teratomas, in particular, should be considered in the differential diagnosis. Virtually all tumors are vascularized at CEUS, enclosed teratomas, while non-tumor complex cysts and epidermoid cysts are avascular (Fig. 12).

Diagnosis of epidermoid cyst is clinically relevant. These lesions have not malignant potential and can be followed up or treated with a testis sparing enucleation rather than orchiectomy. Layers of keratinized squamous epithelium often give to epidermoid cysts the typical "onion ring" pattern, consisting in alternating rings of low and high echogenicity. This pattern, however, is lacking in many cases making characterization difficult. Characterization is improved for lesions stiff at elastography which lack vascularity at CEUS [59].

Inflammation

Epididymo-orchitis is the most common cause of acute scrotal pain in adults. Diagnosis is based on clinical features and presentation at color Doppler ultrasonography. In the vast majority of cases, epididymo-orchitis presents with increased vascularity. A severe epididymo-orchitis, however, may cause tissue edema with venous compression and parenchymal ischemia which favors abscess formation. When post-inflammatory ischemia develops, the testis is hypovascular, despite clinical signs

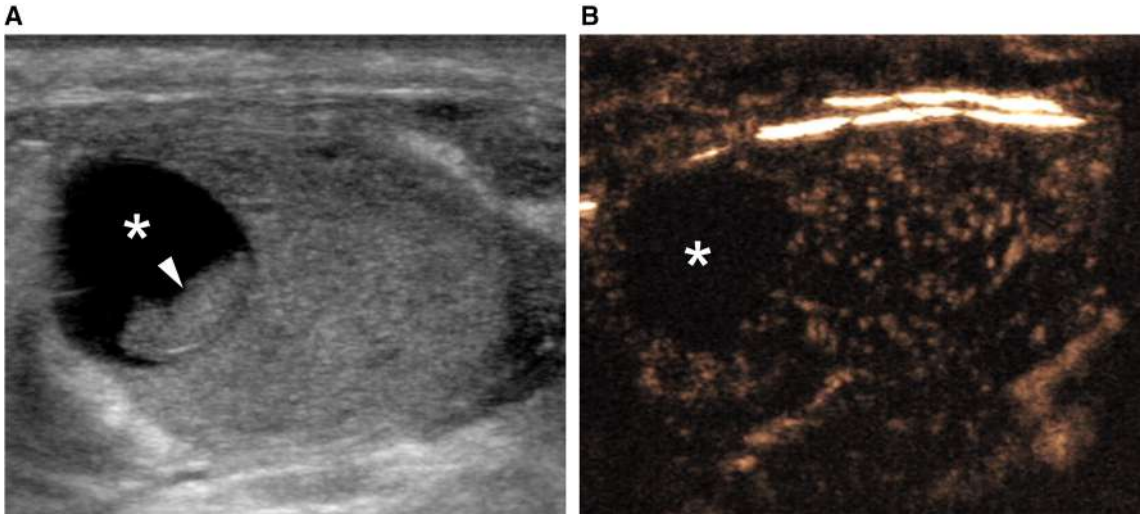

Fig. 12. Incidentally detected complex testicular cyst. **A** Gray-scale ultrasonography shows a complex cyst in the upper pole of the testis (asterisk) containing echogenic material mimicking a vegetation (arrowhead). **B** CEUS shows the absence of vascularized vegetations within the cyst. The cyst disappeared during the follow-up (not shown).

of severe inflammation. High resistance parenchymal flows and/or diastolic flow reversal are recorded at Doppler spectral analysis. Aggressive medical treatment with antibiotics and anti-inflammatory medications is needed in post-inflammatory ischemia to reduce parenchymal edema, to increase testis vascularity, and prevent abscess formation and/or venous testicular infarction. CEUS is able to visualize ischemic changes and abscess formation in the testis and epididymis [35, 37, 60]. As shown in CLIP#4 and in Figs. 13 and 14, impending abscess formation presents with markedly hypovascular areas with indistinct margins, while overt infarction is avascular, rounded or oval, often surrounded by a hypervascular rim of enhancement [23, 61]. The examination can be repeated during the follow-up to investigate the response to medical therapy.

In our practice, elastography does not add significantly to clinical examination, conventional Doppler modes, and CEUS. Epididymo-orchitis is stiff at elastography, while abscesses are usually softer (Fig. 15). At elastography, impending abscess formation can be stiff at the periphery and with inhomogeneous stiffness in the center, likely reflecting the presence of small colliquation areas. Overt abscesses are prevalently softer than the surrounding tissue (Fig. 16), sometimes stiffer at the periphery [55].

Traumas

In patients with scrotal trauma, the extent of hematomas and hemorrhagic areas within the testis is often underestimated with conventional ultrasonographic modes. Early after the trauma, the echogenicity of the hematoma can be similar to the normal testis and testicular vascularity is globally reduced in the injured testis due to edema and blood extravasation. CEUS is highly sensitive to reveal parenchymal vascularization and its changes in the injured testis [24, 34]. Unlike gray-scale US, CEUS is able to depict fracture lines, intratesticular hematomas, and to differentiate viable from non-viable parenchyma [23] (Fig. 17). This information helps planning the clinical and surgical management of the patient.

Spontaneous testicular hematoma

Testicular hematomas are commonly encountered in patients with scrotal traumas. Rarely, hematomas develop also spontaneously, or could follow spontaneous bleeding of previously undetected intratesticular aneurysms and arteriovenous malformations. Patients present with acute scrotal pain. The lesion mimics a tumor at gray-scale ultrasonography, but lacks Doppler flow and enhancement at CEUS [37, 62]. Differentiation from a hypovascular tumor requires contrast agent administration and is important, since spontaneous hematoma is managed conservatively provided a firm preoperative diagnosis is made. A presumptive diagnosis of spontaneous testicular hematoma can be made putting the clinical presentation and ultrasonographic modes together, and confirmed by rapid change in shape and appearance during the follow-up, an evolution not encountered in tumors (Fig. 18). MRI confirms the diagnosis showing that the lesion displays characteristic signal intensity of blood [63]. When in fluid, hematoma is similar to cyst at elastography, while organized hematomas are echogenic or with mixed appearance [21, 55]

Infertility

In infertile patients, changes of testicular size and echogenicity are often non-specific. CEUS has currently

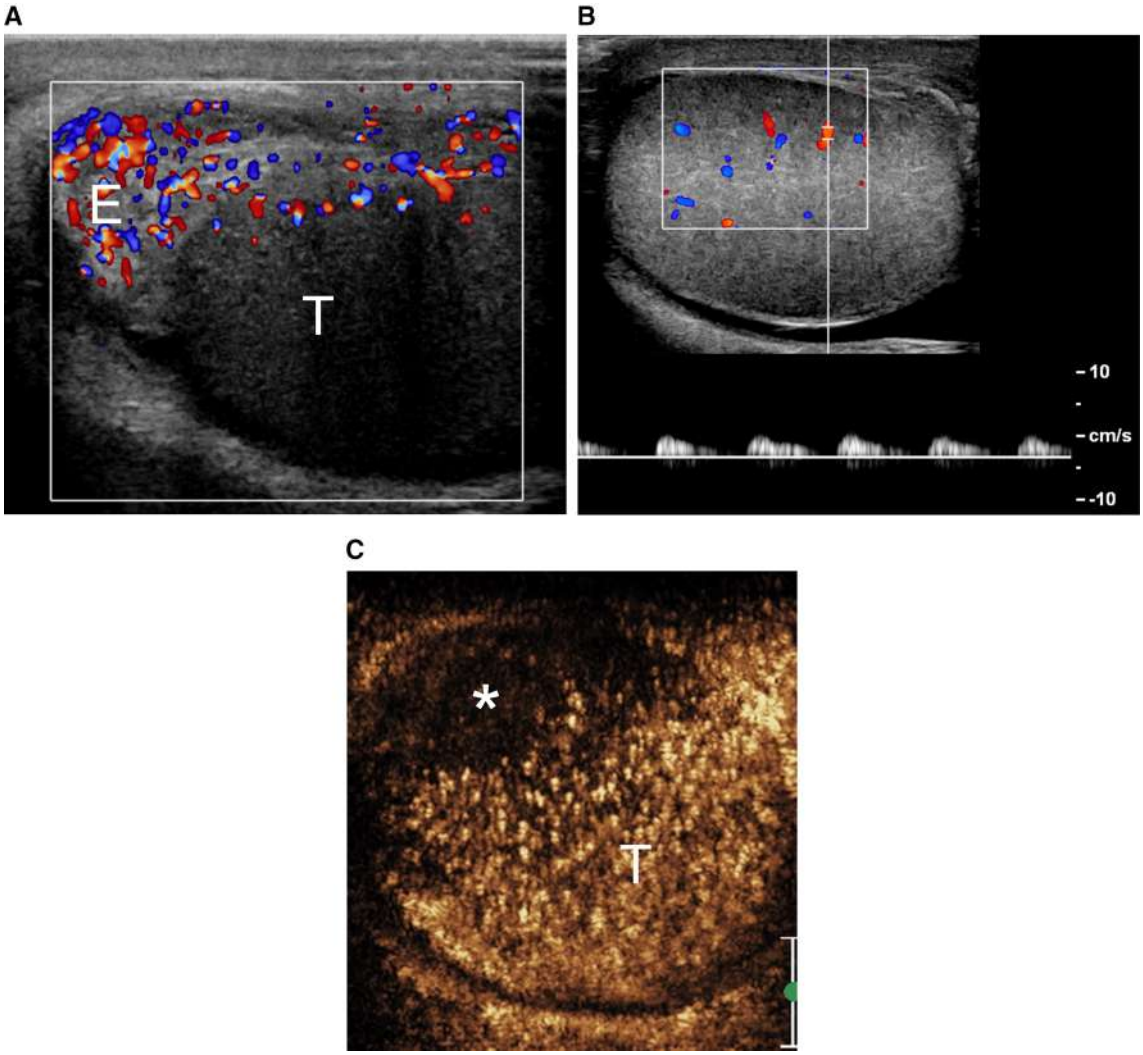

Fig. 13. Post-inflammatory testicular ischemia in a patient with severe epididymo-orchitis. **A** Color Doppler ultrasonography shows hypoechoic, hypovascular testis (T) and enlarged, hypervascular epididymis (E). **B** Spectral Doppler analysis shows high resistance testicular flows, consistent with ischemia. **C** CEUS shows an ischemic area (asterisks) in the upper pole and middle portion of the testis (T) consistent with impending abscess formation.

no established role in infertile patients. Rarely, it can be used in markedly inhomogeneous testes to improve identification of small nodules. Use of elastography is undergoing investigation in an attempt to find new clinically useful independent parameters. The elasticity pattern of the testis seems to be related to the volume and function [64]. Elastography seems promising to differentiate azoospermia from different causes. Rocher et al. found a significant difference between patients with non-obstructive azoospermia and Klinefelter syndrome, compared to both non-obstructive azoospermia in other patients and to obstructive azoospermia [17]. The clinical impact of these findings in the current practice is, however, questionable because of substantial number of overlapping values. Technical optimization is necessary to improve differentiation between normal and infertile patients.

Varicocele

There are investigations exploring the role of CEUS and elastographic modes in patients with varicocele. Current evidence shows that varicocele can affect fertility, since semen improvement is observed after varicocele correction [65, 66]. One hypothesis is that the hydrostatic pressure may exceed pressure in the intratesticular arterial microcirculation causing a relative hypoxia of the testicular tissues and ischemic damage [67]. Caretta et al. evaluated with CEUS in 90 patients with left varicocele, 50 with oligospermia, and 40 with normozoospermia

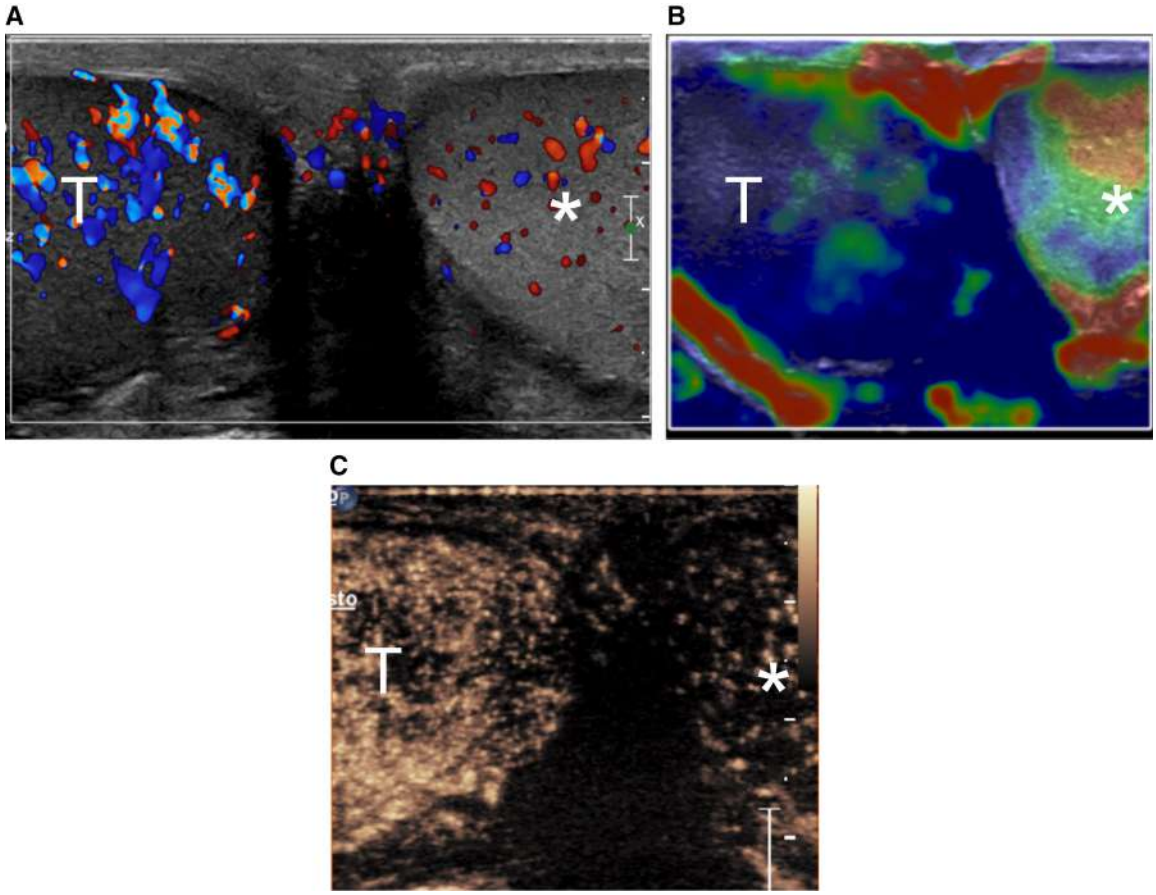

Fig. 14. Severe epididymo-orchitis in a patient presenting with right testicular pain and swelling. "Spectacle" view of both testes obtained with a transverse plane. **A** Color Doppler ultrasonography reveals a hypoechoic hypervascular right testis (T). The contralateral left testis (asterisk) displays normal vascularity. **B** Strain elastography axial image showing a stiffer right testis (T) compared to the contralateral one (asterisk). Stiff regions are encoded in blue. **C** CEUS shows intense end early enhancement of the right testis (T) compared to the left testis (asterisk). Small non-enhancing areas are identified in the right testis, consistent with small abscesses.

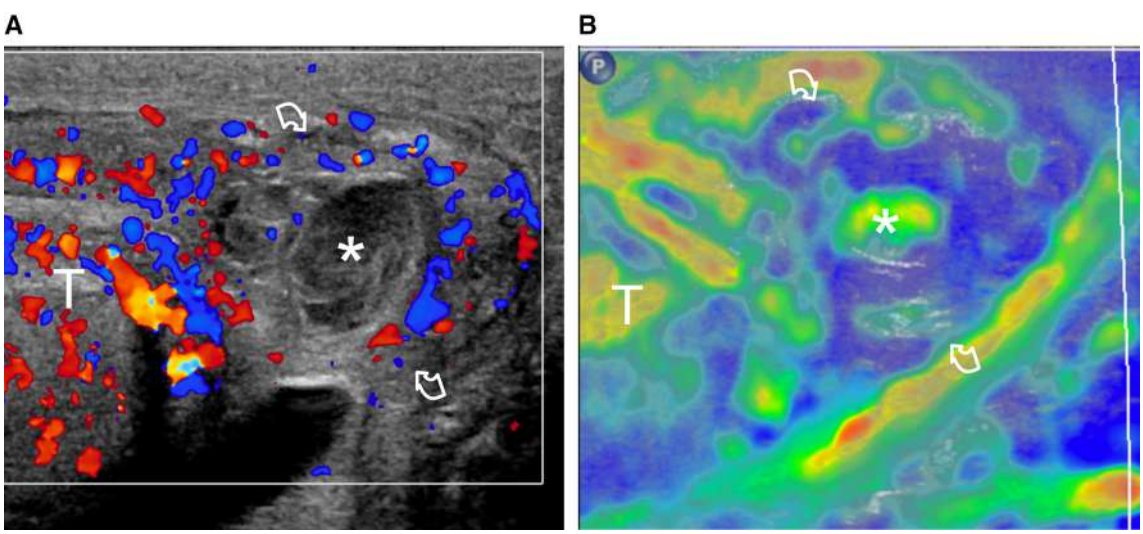

Fig. 15. Epididymo-orchitis complicated with abscess formation. **A** Color Doppler US shows hypervascular testis (T) and epididymis (curved arrows). An area lacking color signals is identified in the tail of the epididymis (asterisk), consistent with an abscess. **B** Strain elastography shows a globally stiff epididymal tail (curved arrows, encoded in blue), with a softer colliquative area (asterisk).

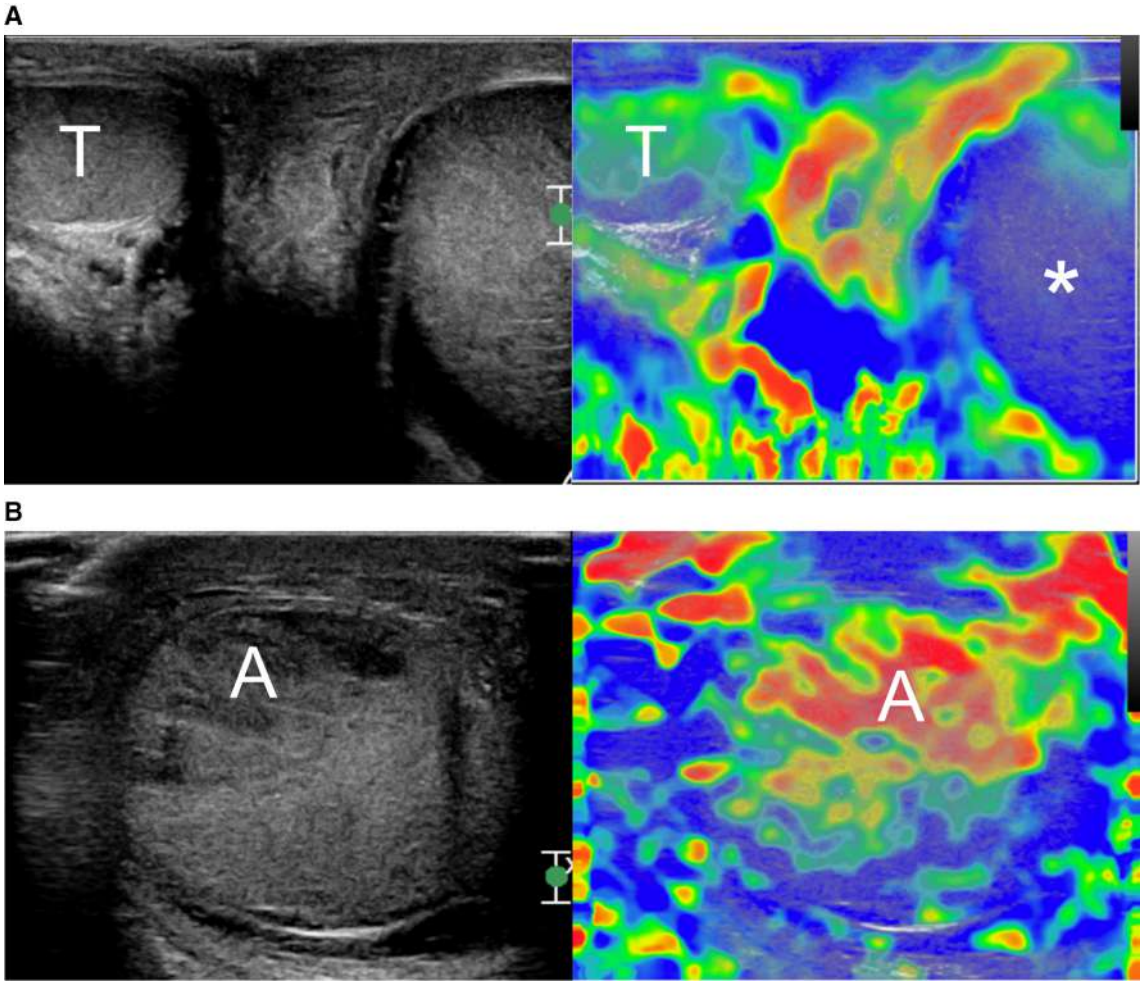

Fig. 16. Post-inflammatory left testicular ischemia with abscess formation in a patient with severe epididymo-orchitis. **A** Strain elastography axial image showing a homogeneously stiff left testis (asterisk, encoded in blue), compared to the contralateral testis (T). **B** Follow-up examination obtained one week later shows the presence of soft areas in the upper pole of the left testis consistent with colliquation of the parenchyma (A, encoded in red). Abscess formation is appreciable also on the gray-scale reference image by the presence of a hypoechoic, inhomogeneous area with ill-defined margins (A), corresponding to the soft region identified at elastography.

[68]. They found a linear correlation between the total sperm count and left mean transit time. A mean transit time greater than 36 s was an independent predicting parameter for oligospermia with 78% sensitivity and 58% specificity. Recent studies suggest that elastography could play a role to predict testicular damage in patients with varicocele. According to Camoglio et al., testes with varicocele are significantly stiffer at elastography than the contralateral ones, and there is a positive correlation between parenchymal stiffness at elastography and the duration of spermatic vein reflux [16]. Also, it has been shown that shear-wave elastography could have a role to predict semen parameter improvement after varicocelectomy [69]. These results are very promising, but still experimental and need to be confirmed in larger studies before clinical application could be considered.

Therapeutic applications

A perspective in ultrasonography research is use of new targeted microbubbles carrying bioactive materials such as genes or drugs to specific sites. Diagnostic and therapeutic applications can be prospected. When microbubbles reach the target site, intracellular delivery can occur with different mechanisms. Substances with small molecular size can enter the cell with the contribution of endocytosis. Sonoporation allows uptake of larger molecules and plasmids [70]. With sonoporation, low-frequency ultrasound irradiation is used to generate transient pore formation in the cell membrane with the aim to obtain a reversible increase in its permeabilization [71]. It is a cavitation phenomenon, markedly increased in the presence of microbubbles. Microbubbles augment

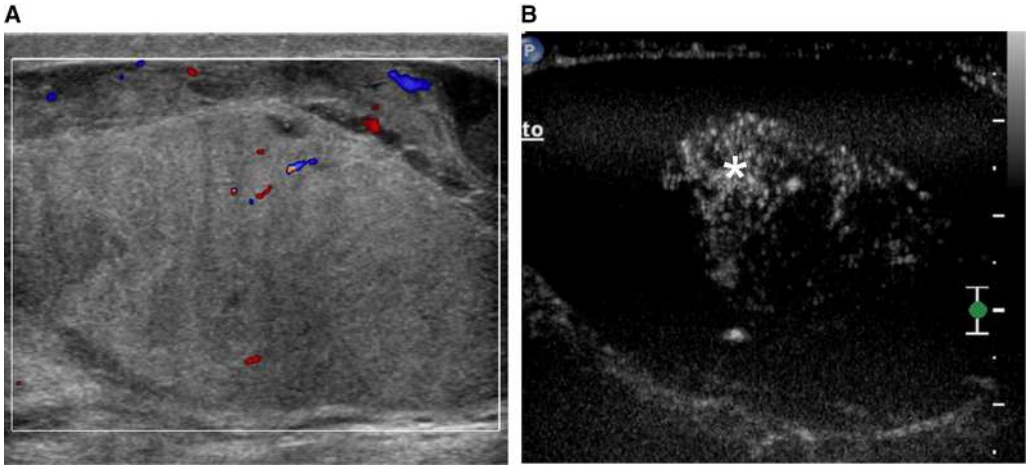

Fig. 17. Testicular rupture. **A** Color Doppler ultrasonography shows contour irregularities of the testis and nearly complete absence of vascularization of the injured parenchyma. **B** CEUS shows that only a small portion of the parenchyma (asterisk) is still viable. The testis was removed at surgery.

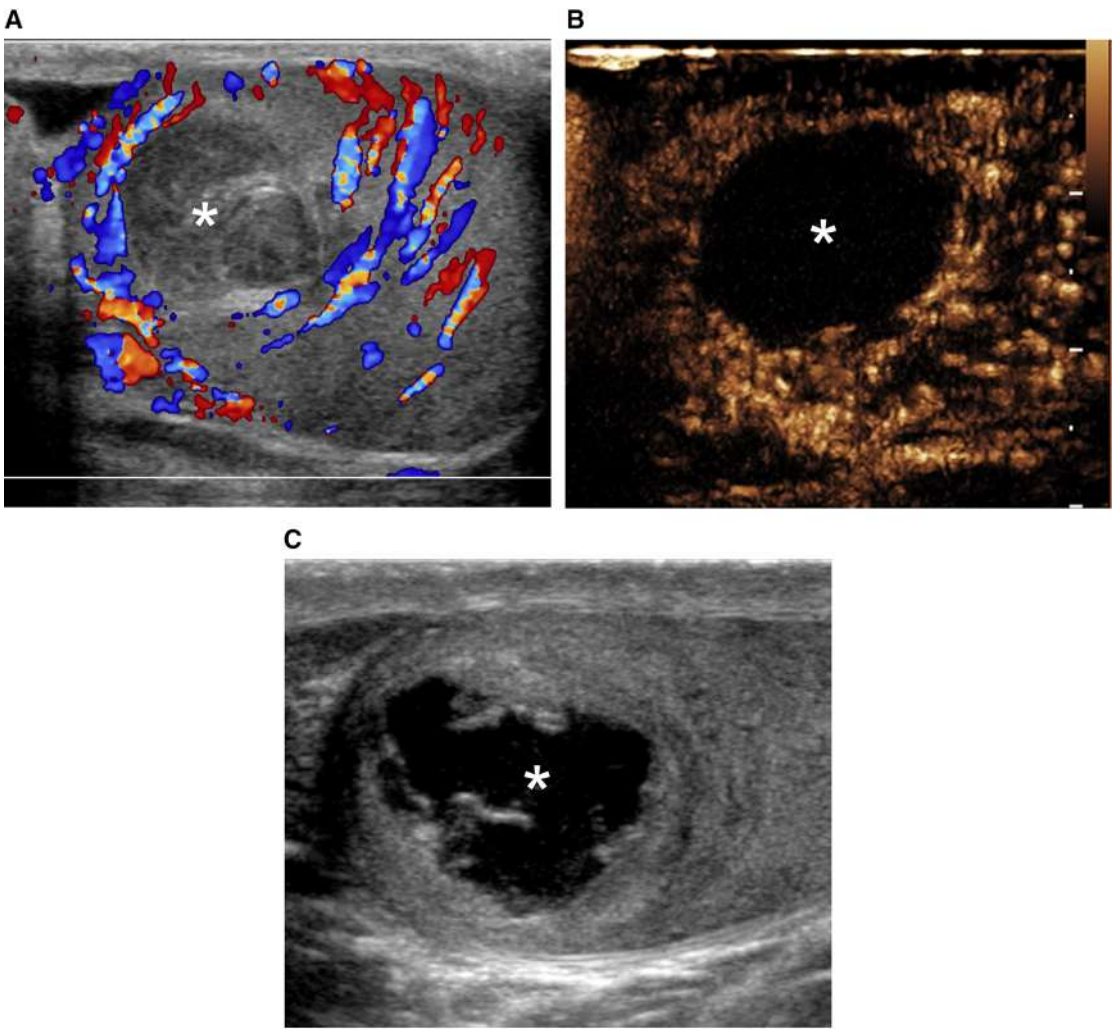

Fig. 18. Spontaneous intratesticular hematoma in a patient presenting with abrupt onset of severe left testicular pain and swelling and no history of trauma. **A** Color Doppler ultrasonography reveals a hypoechoic avascular lesion (asterisk). **B** CEUS confirms lack of lesion vascularity (asterisk). **C** After one week, lesion appearance changed, showing a complex cystic appearance due to blood clot lysis. Hematoma was confirmed with characteristic appearance of blood at MR imaging (not shown).

delivery of bioactive substances to the testis as well. Bekeredjian et al. investigated rats receiving luciferase without microbubbles and rats receiving intravenous injection of luciferase-loaded microbubbles while ultrasonography was applied to the right testis. The testes that received ultrasonography and luciferase-loaded microbubbles showed about twofold greater luciferase activity compared with testes without ultrasonography or without microbubbles [72].

Conclusions

Multiparametric US is now established as the imaging modality of choice for scrotal diseases. The use of high-frequency gray-scale US and Doppler modes is the mainstay. Contrast-enhanced ultrasonography is increasingly recognized as a valuable problem-solving technique in selected cases. Compared to palpation, elastography offers a more objective evaluation of tissue consistency, but the information provided is basically the same. Potential clinical applications of shear-wave elastography include work-up of infertile patients.

Compliance with ethical standards

Funding The authors receive no funding for this work.

Conflict of interest All authors declare that they have no conflict of interest.

Ethical approval All procedures performed in studies involving human participants were in accordance with the ethical standards of the institutional committee and with the 1964 Helsinki declaration and its later amendments. Informed consent was obtained from all individuals who had contrast agent administration.

References

1. Dalla Palma L, Bertolotto M (1999) Introduction to ultrasound contrast agents: physics overview. Eur Radiol 9(3):S338–S342
2. Bertolotto M, Bartolotta TV, Calderan L, et al. (2006) Contrast enhanced ultrasonography for focal liver lesions characterization: clinical perspective. Curr Med Imaging Rev 2(3):373–383. https://doi.org/10.2174/157340506777934561
3. Piscaglia F, Nolsoe C, Dietrich CF, et al. (2012) The EFSUMB guidelines and recommendations on the clinical practice of contrast enhanced ultrasound (CEUS): update 2011 on non-hepatic applications. Ultraschall Med 33(1):33–59. https://doi.org/10.1055/s-0031-1281676
4. Bertolotto M, Serafini G, Sconfienza LM, et al. (2014) The use of CEUS in the diagnosis of retinal/choroidal detachment and associated intraocular masses-preliminary investigation in patients with equivocal findings at conventional ultrasound. Ultraschall Med 35(2):173–180. https://doi.org/10.1055/s-0032-1330321
5. Rubenthaler J, Paprottka K, Marcon J, et al. (2016) Comparison of magnetic resonance imaging (MRI) and contrast-enhanced ultrasound (CEUS) in the evaluation of unclear solid renal lesions. Clin Hemorheol Microcirc 64(4):757–763. https://doi.org/10.3233/CH-168034
6. Barr RG, Peterson C, Hindi A (2014) Evaluation of indeterminate renal masses with contrast-enhanced US: a diagnostic performance study. Radiology 271(1):133–142. https://doi.org/10.1148/radiol.13130161
7. Kim TK, Noh SY, Wilson SR, et al. (2017) Contrast-enhanced ultrasound (CEUS) liver imaging reporting and data system (LI-RADS) 2017: a review of important differences compared to the CT/MRI system. Clin Mol Hepatol 23(4):280–289. https://doi.org/10.3350/cmh.2017.0037
8. Piscaglia F, Bolondi L, Italian Society for Ultrasound in M, Biology Study Group on Ultrasound Contrast A (2006) The safety of Sonovue in abdominal applications: retrospective analysis of 23188 investigations. Ultrasound Med Biol 32(9):1369–1375. https://doi.org/10.1016/j.ultrasmedbio.2006.05.031
9. Cochran ST, Bomyea K, Sayre JW (2001) Trends in adverse events after IV administration of contrast media. AJR Am J Roentgenol 176(6):1385–1388. https://doi.org/10.2214/ajr.176.6.1761385
10. Hunt CH, Hartman RP, Hesley GK (2009) Frequency and severity of adverse effects of iodinated and gadolinium contrast materials: retrospective review of 456,930 doses. AJR Am J Roentgenol 193(4):1124–1127. https://doi.org/10.2214/AJR.09.2520
11. Girometti R, Stocca T, Serena E, Granata A, Bertolotto M (2017) Impact of contrast-enhanced ultrasound in patients with renal function impairment. World J Radiol 9(1):10–16. https://doi.org/10.4329/wjr.v9.i1.10
12. Bamber J, Cosgrove D, Dietrich CF, et al. (2013) EFSUMB guidelines and recommendations on the clinical use of ultrasound elastography. Part 1: basic principles and technology. Ultraschall Med 34(2):169–184. https://doi.org/10.1055/s-0033-1335205
13. Cosgrove D, Piscaglia F, Bamber J, et al. (2013) EFSUMB guidelines and recommendations on the clinical use of ultrasound elastography. Part 2: Clinical applications. Ultraschall Med 34(3):238–253. https://doi.org/10.1055/s-0033-1335375
14. Goddi A, Sacchi A, Magistretti G, Almolla J, Salvadore M (2012) Real-time tissue elastography for testicular lesion assessment. Eur Radiol 22(4):721–730. https://doi.org/10.1007/s00330-011-2312-2
15. Aigner F, De Zordo T, Pallwein-Prettner L, et al. (2012) Real-time sonoelastography for the evaluation of testicular lesions. Radiology 263(2):584–589. https://doi.org/10.1148/radiol.12111732
16. Camoglio FS, Bruno C, Peretti M, et al. (2017) The role of sonoelastography in the evaluation of testes with varicocele. Urology 100:203–206. https://doi.org/10.1016/j.urology.2016.08.005
17. Rocher L, Criton A, Gennisson JL, et al. (2017) Testicular shear wave elastography in normal and infertile men: a prospective study on 601 patients. Ultrasound Med Biol 43(4):782–789. https://doi.org/10.1016/j.ultrasmedbio.2016.11.016
18. Kantarci F, Cebi Olgun D, Mihmanli I (2012) Shear-wave elastography of segmental infarction of the testis. Korean J Radiol 13(6):820–822. https://doi.org/10.3348/kjr.2012.13.6.820
19. Auer T, De Zordo T, Dejaco C, et al. (2017) Value of multiparametric US in the assessment of intratesticular lesions. Radiology 285(2):640–649. https://doi.org/10.1148/radiol.2017161373
20. Sidhu PS, Piscaglia F, Bartels E, et al. (2018) The EFSUMB guidelines and recommendations for the clinical practice of contrast enhanced ultrasound (CEUS) in non-hepatic applications: update 2017. Ultraschall Med-Eur J Ultrasound 33(1):33–59
21. Schroder C, Lock G, Schmidt C, Loning T, Dieckmann KP (2016) Real-time elastography and contrast-enhanced ultrasonography in the evaluation of testicular masses: a comparative prospective study. Ultrasound Med Biol 42(8):1807–1815. https://doi.org/10.1016/j.ultrasmedbio.2016.03.026
22. Trottmann M, Marcon J, D'Anastasi M, et al. (2016) Shear-wave elastography of the testis in the healthy man-determination of standard values. Clin Hemorheol Microcirc 62(3):273–281. https://doi.org/10.3233/CH-162046
23. Badea R, Lucan C, Suciu M, Vasile T, Gersak M (2016) Contrast enhanced harmonic ultrasonography for the evaluation of acute scrotal pathology. A pictorial essay. Med Ultrason 18(1):110–115. https://doi.org/10.11152/mu.2013.2066.181.esy
24. Valentino M, Bertolotto M, Derchi L, et al. (2011) Role of contrast enhanced ultrasound in acute scrotal diseases. Eur Radiol 21(9):1831
25. Cassar S, Bhatt S, Paltiel HJ, Dogra VS (2008) Role of spectral Doppler sonography in the evaluation of partial testicular torsion. J Ultrasound Med 27(11):1629–1638
26. Lee FT Jr, Winter DB, Madsen FA, et al. (1996) Conventional color Doppler velocity sonography versus color Doppler energy sonography for the diagnosis of acute experimental torsion of the spermatic cord. AJR Am J Roentgenol 167(3):785–790. https://doi.org/10.2214/ajr.167.3.8751701

27. Mernagh JR, Caco C, De Maria J (2004) Testicular torsion revisited. Curr Probl Diagn Radiol 33(2):60–73. https://doi.org/10.1016/j.cpradiol.2003.11.004
28. Wilson SR, Burns PN (2010) Microbubble-enhanced US in body imaging: what role? Radiology 257(1):24–39. https://doi.org/10.1148/radiol.10091210
29. Coley BD, Frush DP, Babcock DS, et al. (1996) Acute testicular torsion: comparison of unenhanced and contrast-enhanced power Doppler US, color Doppler US, and radionuclide imaging. Radiology 199(2):441–446. https://doi.org/10.1148/radiology.199.2.8668791
30. O'Hara SM, Frush DP, Babcock DS, et al. (1996) Doppler contrast sonography for detecting reduced perfusion in experimental ischemia of prepubertal rabbit testes. Acad Radiol 3(4):319–324
31. Paltiel HJ, Kalish LA, Susaeta RA, et al. (2006) Pulse-inversion US imaging of testicular ischemia: quantitative and qualitative analyses in a rabbit model. Radiology 239(3):718–729. https://doi.org/10.1148/radiol.2393050210
32. Cosgrove DO, Kiely P, Williamson R, Blomley MJ, Eckersley RJ (2000) Ultrasonographic contrast media in the urinary tract. BJU Int 86(1):11–17
33. Catalano O, Lobianco R, Sandomenico F, Mattace Raso M, Siani A (2004) Real-time, contrast-enhanced sonographic imaging in emergency radiology. Radiol Med 108(5–6):454–469
34. Moschouris H, Stamatiou K, Lampropoulou E, Kalikis D, Matsaidonis D (2009) Imaging of the acute scrotum: is there a place for contrast-enhanced ultrasonography? International braz j urol 35(6):692–705
35. Yusuf GT, Sidhu PS (2013) A review of ultrasound imaging in scrotal emergencies. J Ultrasound 16(4):171–178. https://doi.org/10.1007/s40477-013-0033-x
36. Zhang X, Lv F, Tang J (2015) Shear wave elastography (SWE) is reliable method for testicular spermatogenesis evaluation after torsion. Int J Clin Exp Med 8(5):7089–7097
37. Bertolotto M, Cantisani V, Valentino M, Pavlica P, Derchi LE (2016) Pitfalls in imaging for acute scrotal pathology. Semin Roentgenol 51(1):60–69. https://doi.org/10.1053/j.ro.2016.02.012
38. Bertolotto M, Derchi LE, Sidhu PS, et al. (2011) Acute segmental testicular infarction at contrast-enhanced ultrasound: early features and changes during follow-up. AJR Am J Roentgenol 196(4):834–841. https://doi.org/10.2214/AJR.10.4821
39. Patel KV, Huang DY, Sidhu PS (2014) Metachronous bilateral segmental testicular infarction: multi-parametric ultrasound imaging with grey-scale ultrasound, Doppler ultrasound, contrast-enhanced ultrasound (CEUS) and real-time tissue elastography (RTE). J Ultrasound 17(3):233–238. https://doi.org/10.1007/s40477-014-0098-1
40. Jaffer OSSPS (2013) Contrast-enhanced ultrasonography of the testes. Ultrasound Clin 8:509–523
41. Horstman WG, Melson GL, Middleton WD, Andriole GL (1992) Testicular tumors: findings with color Doppler US. Radiology 185(3):733–737. https://doi.org/10.1148/radiology.185.3.1438754
42. Ma W, Sarasohn D, Zheng J, Vargas HA, Bach A (2017) Causes of avascular hypoechoic testicular lesions detected at scrotal ultrasound: can they be considered benign? AJR Am J Roentgenol 209(1):110–115. https://doi.org/10.2214/AJR.16.17333
43. Cantisani V, Bertolotto M, Weskott HP, et al. (2015) Growing indications for CEUS: the kidney, testis, lymph nodes, thyroid, prostate, and small bowel. Eur J Radiol 84(9):1675–1684. https://doi.org/10.1016/j.ejrad.2015.05.008
44. Rocher L, Ramchandani P, Belfield J, et al. (2016) Incidentally detected non-palpable testicular tumours in adults at scrotal ultrasound: impact of radiological findings on management Radiologic review and recommendations of the ESUR scrotal imaging subcommittee. Eur Radiol 26(7):2268–2278. https://doi.org/10.1007/s00330-015-4059-7
45. Drudi FM, Maghella F, Martino G, et al. (2016) Detection of small testicular masses in monorchid patients using US, CPDUS, CEUS and US-guided biopsy. J Ultrasound 19(1):25–28. https://doi.org/10.1007/s40477-015-0158-1
46. Sidhu PS, Sriprasad S, Bushby LH, Sellars ME, Muir GH (2004) Impalpable testis cancer. BJU Int 93(6):888. https://doi.org/10.1111/j.1464-410X.2004.4737d.x
47. Bertolotto M, Derchi LE, Secil M, et al. (2015) Grayscale and color Doppler features of testicular lymphoma. J Ultrasound Med 34(6):1139–1145. https://doi.org/10.7863/ultra.34.6.1139
48. Kachramanoglou C, Rafailidis V, Philippidou M, et al. (2017) Multiparametric sonography of hematologic malignancies of the testis: grayscale, color Doppler, and contrast-enhanced ultrasound and strain elastographic appearances with histologic correlation. J Ultrasound Med 36(2):409–420. https://doi.org/10.7863/ultra.16.02013
49. Bertolotto M, Borsato A, Derchi LE (2014) Lymphoma of the spermatic cord: sonographic appearance. J Clin Ultrasound 42(8):509–512. https://doi.org/10.1002/jcu.22198
50. Conzi R, Damasio MB, Bertolotto M, et al. (2017) Sonography of scrotal wall lesions and correlation with other modalities. J Ultrasound Med 36(10):2149–2163. https://doi.org/10.1002/jum.14257
51. Isidori AM, Pozza C, Gianfrilli D, et al. (2014) Differential diagnosis of nonpalpable testicular lesions: qualitative and quantitative contrast-enhanced US of benign and malignant testicular tumors. Radiology 273(2):606–618. https://doi.org/10.1148/radiol.14132718
52. Drudi FM, Valentino M, Bertolotto M, et al. (2016) CEUS time intensity curves in the differentiation between leydig cell carcinoma and seminoma: a multicenter study. Ultraschall Med 37(2):201–205. https://doi.org/10.1055/s-0034-1398841
53. Pozza C, Gianfrilli D, Fattorini G, et al. (2016) Diagnostic value of qualitative and strain ratio elastography in the differential diagnosis of non-palpable testicular lesions. Andrology 4(6):1193–1203. https://doi.org/10.1111/andr.12260
54. Schurich M, Aigner F, Frauscher F, Pallwein L (2009) The role of ultrasound in assessment of male fertility. Eur J Obstet Gynecol Reprod Biol 144(1):S192–S198. https://doi.org/10.1016/j.ejogrb.2009.02.034
55. Huang DY, Sidhu PS (2012) Focal testicular lesions: colour Doppler ultrasound, contrast-enhanced ultrasound and tissue elastography as adjuvants to the diagnosis. Br J Radiol 85(1):S41–S53. https://doi.org/10.1259/bjr/30029741
56. Valentino M, Bertolotto M, Ruggirello M, et al. (2011) Cystic lesions and scrotal fluid collections in adults: ultrasound findings. J Ultrasound 14(4):208–215. https://doi.org/10.1016/j.jus.2011.10.008
57. Bhatt S, Rubens DJ, Dogra VS (2006) Sonography of benign intrascrotal lesions. Ultrasound Q 22(2):121–136
58. Winter TC (2009) There is a mass in the scrotum-what does it mean?: evaluation of the scrotal mass. Ultrasound Q 25(4):195–205. https://doi.org/10.1097/RUQ.0b013e3181c6b42d
59. Patel K, Sellars ME, Clarke JL, Sidhu PS (2012) Features of testicular epidermoid cysts on contrast-enhanced sonography and real-time tissue elastography. J Ultrasound Med 31(1):115–122
60. Lung PF, Jaffer OS, Sellars ME, et al. (2012) Contrast-enhanced ultrasound in the evaluation of focal testicular complications secondary to epididymitis. AJR Am J Roentgenol 199(3):W345–W354. https://doi.org/10.2214/AJR.11.7997
61. Cokkinos DD, Antypa E, Kalogeropoulos I, et al. (2013) Contrast-enhanced ultrasound performed under urgent conditions. Indications, review of the technique, clinical examples and limitations. Insights. Imaging 4(2):185–198. https://doi.org/10.1007/s13244-012-0209-5
62. Gaur S, Bhatt S, Derchi L, Dogra V (2011) Spontaneous intratesticular hemorrhage: two case descriptions and brief review of the literature. J Ultrasound Med 30(1):101–104
63. Tsili AC, Bertolotto M, Turgut AT, et al. (2018) MRI of the scrotum: recommendations of the ESUR Scrotal and Penile Imaging Working Group. Eur Radiol 28(1):31–43. https://doi.org/10.1007/s00330-017-4944-3
64. Correas JM, Drakonakis E, Isidori AM, et al. (2013) Update on ultrasound elastography: miscellanea. Prostate, testicle, musculoskeletal. Eur J Radiol 82(11):1904–1912. https://doi.org/10.1016/j.ejrad.2013.05.031
65. Liguori G, Trombetta C, Ollandini G, et al. (2009) Predictive factors of better improvement in semen quality after sclerotization of varicocele: preliminary report. JAS 16:47–53
66. Liguori G, Ollandini G, Pomara G, et al. (2010) Role of renospermatic basal reflow and age on semen quality improvement after sclerotization of varicocele. Urology 75(5):1074–1078. https://doi.org/10.1016/j.urology.2009.10.068

67. Gat Y, Zukerman ZVI, Bahcar GN, Feldberg D, Gornish M (2003) Adolescent varicocele: is it a unilateral disease? Pediatric Urology 62(4):742–746
68. Caretta N, Palego P, Schipilliti M, et al. (2010) Testicular contrast harmonic imaging to evaluate intratesticular perfusion alterations in patients with varicocele. J Urol 183(1):263–269. https://doi.org/10.1016/j.juro.2009.08.140
69. Abdelwahab K, Eliwa AM, Seleem MM, et al. (2017) Role of preoperative testicular shear wave elastography in predicting improvement of semen parameters after varicocelectomy for male patients with primary infertility. Urology 107:103–106. https://doi.org/10.1016/j.urology.2017.04.026
70. Bertolotto MCO (2009) Contrast-enhanced ultrasound: past, present, and future. Ultrasound Clin 4(2009):339–367
71. Tomizawa M, Shinozaki F, Motoyoshi Y, et al. (2013) Sonoporation: gene transfer using ultrasound. World J Methodol 3(4):39–44. https://doi.org/10.5662/wjm.v3.i4.39
72. Bekeredjian R, Kuecherer HF, Kroll RD, Katus HA, Hardt SE (2007) Ultrasound-targeted microbubble destruction augments protein delivery into testes. Urology 69(2):386–389. https://doi.org/10.1016/j.urology.2006.12.004