UNIVERSITÀ DEGLI STUDI DI TRIESTE

Integrating the concept of field cancerization in the classification and risk assessment of cutaneous squamous cell carcinoma: proposal for a new classification and terminology of keratinocyte skin cancer.

This is the peer reviewed (post-print) version of the following article:

Original
Integrating the concept of field cancerization in the classification and risk assessment of cutaneous squamous cell carcinoma: proposal for a new classification and terminology of keratinocyte skin cancer / Conforti, C., Giuffrida, R., Pizzichetta, M.a., Di Meo, N., Magaton-Rizzi, G., Zalaudek, I.. - In: JOURNAL OF THE EUROPEAN ACADEMY OF DERMATOLOGY AND VENEREOLOGY. - ISSN 0926-9959. - STAMPA. - 33:9(2019), pp. e327-e330. [10.1111/jdv.15624]

Availability:
This version is available at: 11368/2942697 since: 2019-04-15T09:39:10Z

Publisher:

Published
DOI:10.1111/jdv.15624

Terms of use:

Some rights reserved. More details in the PostPrint rights section below.

License:
Digital Rights Management not defined

Publisher copyright

-.-

(Article begins on next page)

22 October 2026

arTs Università degli Studi di Trieste Archivio della ricerca – postprint

A total of six patients with GenPs, three women and three men with a mean age of 47 years, were reviewed. All cases had previously received classic systemic therapy and four had already received other biological agents. All patients received ixekizumab according to the recommended dosing for psoriasis.

Response to treatment was assessed using Psoriasis Area and Severity Index (PASI), Body Surface Area (BSA), static Physician's Global Assessment (sPGA), Static Physician's Global assessment of Genitalia (sPGA-G)[5] and Dermatology Life Quality Index (DLQI) scores before and 16 weeks into therapy.

Mean baseline PASI, BSA, sPGA and sPGA-G were 9.8, 8.5, 3.5 and 3.1, respectively. Patients showed significant improvement in these clinical scores as evidenced by their PASI, BSA, sPGA and sPGA-G scores at week 16, which were 1.1, 1, 0.83 and 0.5, respectively. Moreover, patients reported a significant reduction regarding their DLQI. Mean baseline DLQI was 17.3, and DLQI at week 16 was 3.16. All our patients also obtained significant reductions in genital itch and limitation of sexual activity (Fig. 1 and Table 1).

Genital involvement occurs in almost 40% of patients with moderate-to-severe psoriasis at some point in the course of the disease.[3] Itch and discomfort are the most common symptoms. On average, diagnosis of GenPs is made 10.5 years after diagnosis of body plaque psoriasis.[6,7]

Those affected by GenPs have significantly greater impairment in their health-related quality of life, with a reduction in sexual function. However, GenPs tends to be overlooked by clinicians, who do not always specifically enquire about relevant symptoms or routinely examine this site.[3] The diagnosis and treatment of GenPs may be difficult, and it is most often diagnosed at an advanced stage. Education on the symptoms and burden of GenPs may improve identification and treatment.[2,8]

The areas affected by inverse psoriasis are more susceptible to adverse effects from topical corticosteroids. Therefore other therapies could be a valuable addition to currently available topical agents.[8]

There are clinical trials for biologics in psoriasis that specifically recruit subjects with involvement of <10% BSA. These have provided evidence that patients with less extensive disease may also benefit from therapy with ixekizumab.[4]

In conclusion, GenPs can result in significant detriment of patients' physical and mental health, so effective treatments are necessary. It is also important to enquire patients about involvement of special sites, as GenPs is commonly overlooked. The evidence-based data with respect to the efficacy and safety of treatments for GenPs are limited.[8] Recent studies support the use of ixekizumab for psoriasis with involvement of this location as it yields very satisfactory results, as observed in our six cases.

Limitations of this study are the small sample size and short follow-up period. Given the promising results in our patients and good tolerability profile, we believe ixekizumab will probably have an important role in the treatment of GenPs. Larger observational studies are needed to confirm our real-world findings for ixekizumab. The potential role of other IL-17 antibodies in this context will require large, controlled clinical trials.

M. García-Legaz Martínez, Á. Martínez-Doménech,*
P. Hernández-Bel, J. Magdaleno-Tapial,
C. Valenzuela-Oñate, G. Pérez-Pastor,
J.L. Sánchez-Carazo, V. Alegre-de Miquel,
A. Pérez-Ferriols
Department of Dermatology, Consorci Hospital General Universitari de Valencia, València, Spain
*Correspondence: Á. Martínez-Doménech. E-mail: ag.martinezdomenech@gmail.com

References

1 Nestle FO, Kaplan DH, Barker J. Psoriasis. *N Engl J Med* 2009; **361**: 496–509.
2 Ryan C, Menter A, Guenther L *et al.* Efficacy and safety of ixekizumab in a randomized, double-blinded, placebo-controlled phase IIIb study of patients with moderate-to-severe genital psoriasis. *Br J Dermatol* 2018; **179**: 844–852.
3 Becher G, Burden AD. Ixekizumab in genital psoriasis. *Br J Dermatol* 2018; **179**: 811–812.
4 Papp KA, Leonari CL, Blauvelt A *et al.* Ixekizumab treatment for psoriasis: integrated efficacy analysis of three double-blinded, controlled studies (UNCOVER-1, UNCOVER-2, UNCOVER-3). *Br J Dermatol* 2018; **178**: 674–681.
5 Merola JF, Potts Bleakman A, Gottlieb A *et al.* The static physician's global assessment of genitalia: a clinical outcome measure for the severity of genital psoriasis. *J Drugs Dermatol* 2018; **18**: 793.
6 Ryan C , Sadlier M, De Vol E *et al.* Genital psoriasis is associated with significant impairment in quality of life and sexual functioning. *J Am Acad Dematol* 2015; **72**: 978–983.
7 Ji S , Zang Z, Ma H *et al.* Erectile dysfunction in patients with plaque psoriasis: the relation of depression and cardiovascular factors. *Int J Impot Res* 2016; **28**: 96–100.
8 Meeuwis KA, de Hullu JA, Massuger LF *et al.* Genital psoriasis: a systematic literature review on this hidden skin disease. *Acta Derm Venereol* 2011; **91**: 5–11.

Integrating the concept of field cancerization in the classification and risk assessment of cutaneous squamous cell carcinoma: proposal for a new classification and terminology of keratinocyte skin cancer

Dear Editor,

The term keratinocyte skin cancer (KC) stands as an umbrella for different stages within the progression of cutaneous

squamous cell carcinoma (cSCC).[1,2] Its earliest form is named actinic keratosis (AK), while for the *in situ* form different synonyms, namely intraepidermal carcinoma (IEC), Bowen's diseases (BD) and cutaneous squamous cell carcinoma *in situ* [cSCC(Tis)] or intraepithelial squamous cell carcinoma (iSCC) are used.[3] Instead, cSCC is histopathologically classified into well, moderately and poorly differentiated subtypes. The well-differentiated variant of cSCC is also referred to as keratoacanthoma (KA) although there is debate whether or not, both tumours represent different entities. The inconsistency and overlapping use of terminologies in naming KC is problematic as it introduces imprecisions in the classification and risk assessment of progression. Although several staging systems that have been proposed in the last years, they largely failed to accurately predict the prognosis of cSCC.[4] One of the reasons may be due to the inclusion of heterogeneous subtypes of KC based on the inconsistencies of definitions. Another problem may be related to the lack of considering other prognostic factors related to the overall context of the patients. The new 8th AJCC classification is the first to recognize cSCC arising on sun-exposed and to differentiate them from SCC of non-sun-exposed sites, which are excluded from the classification.[5]

In fact, although the majority of cSCC develop on chronically sun-exposed areas, a certain subset develops as solitary tumour on generally sun-protected or only intermittently exposed areas such as the trunk, upper legs, arms and genital area in the absence of surrounding AKs.[6,7] These tumours commonly meet the criteria of BD and KA and appear to have a lower potential for malignant progression compared with cSCC(Tis) or invasive cSCC arising on chronic sun damaged skin.

These data point towards the concept that different types of cSCC exist with regard to their pathogenesis, morphology, grow patterns and potential to metastasis.

For this reason, we propose a revised nomenclature by integrating the overall context of the patient, in order to improve

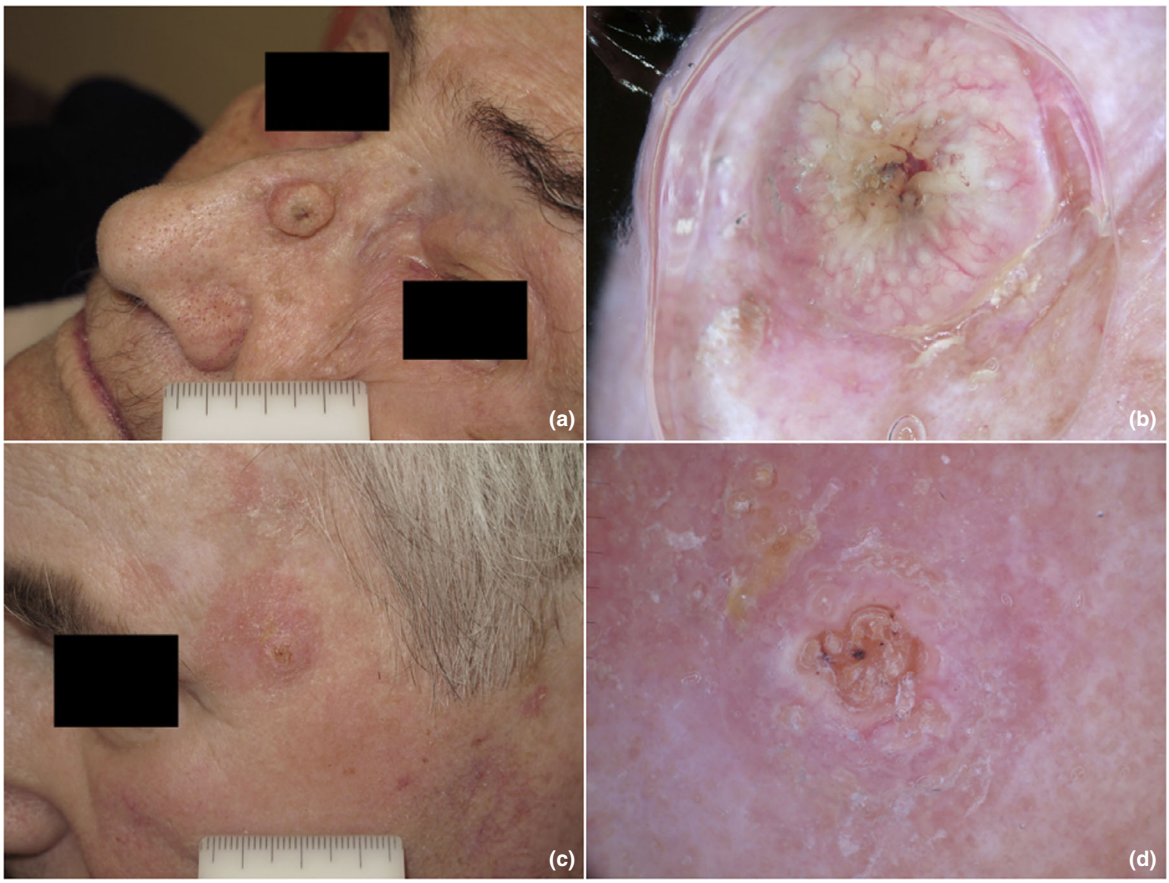

Figure 1 Clinical and dermatoscopic features of KA and well-differentiated SCC. Clinically KA is a solitary nodule not associated with actinic keratoses (a) while iSCC is usually a slow growing nodule associated with actinic keratoses or other signs of chronic sun exposure (c). The main dermatoscopic features of KA are radial or curved vessels with a central mass of keratin and a variable presence of haemorrhages (b); iSCC shows irregular vessels, structureless white areas, white circles and signs of keratin (d).

Figure 2 Clinical and dermatoscopic features of BD and SCC *in situ*. The real BD develops on no sun damage skin, and it is not surrounded by actinic keratosis (a); it also has low risk of progression. Dermatoscopically, BD shows glomerular vessels distributed in clusters, scaly surface and pigmented streak (b). In figure (c), there are two different skin cancers: the lesion in the right upper part of the picture is, in our vision, a iSCC, dermatoscopically represented in figure (d); it shows scaly surface, glomerular vessels and haemorrhages. It is not a BD because it arises in the context of field of cancerization, surrounded by AKS and near to a SCC (*). This supports a progressive behaviour of iSCC, not present in the classical BD.

the definition, identification, classification and prognosis of distinct forms of KC.

In the light of a presumably different malignant transformation risk between AK-associated and non-associated forms in the spectrum of KC, we propose using the term '*cSCC+-field*' for KC arising in the presence of AK within a field of cancerization. In our view, this group of tumours represent true 'carcinomas' with a low but definitive risk of progression and accordingly should be treated more aggressively. Vice versa we propose using '*cSCC-field*' for formerly as BD or KA determined lesions that develop *de novo* in the absence of AK or a field of cancerization.[8,9]

These tumours may be regarded more as 'acanthomas' than true carcinomas as they have neglectable risk for malignant progression. In fact, while in the pathogenesis of the former, UV exposure undoubtedly plays a major role, the latter form likely develops due to other pathways, such as HPV infections.[10] Of note, these different subgroups also exhibit distinct clinical and dermatoscopic features as illustrated in Figures 1 and 2.

In conclusion, we propose a new nomenclature of KC by integrating the concept of field cancerization in the classification of cSCC. Our proposal should be regarded conceptual as it is not based on formal studies. However, it provides a starting point for future research with regard to the classification, risk assessment, treatment approaches and further insights into the development of these different types of tumours in patients with and without associated areas of cancerization.

C. Conforti,[1,*] R. Giuffrida,[2] M.A. Pizzichetta,[3] N. Di Meo,[1] G. Magaton-Rizzi,[1] I. Zalaudek[1]

[1]Dermatology Clinic, Maggiore Hospital, University of Trieste, Trieste, Italy, [2]Section of Dermatology, Department of Clinical and Experimental Medicine, University of Messina, Messina, Italy, [3]Division of Oncology B, CRO Aviano National Cancer Institute, Aviano, Italy

*Correspondence: C. Conforti. E-mail: claudioconforti@yahoo.com

References

1 Boone MA, Suppa M, Marneffe A, Miyamoto M, Jemec GB, Del Marmol V. A new algorithm for the discrimination of actinic keratosis from normal skin and squamous cell carcinoma based on *in vivo* analysis of optical properties by high-definition optical coherence tomography. *J Eur Acad Dermatol Venereol* 2016; **30**: 1714–1725.
2 Cockerell CJ. Histopathology of incipient intraepidermal squamous cell carcinoma (actinic keratosis). *J Am Acad Dermatol* 2000; **42**: 11–17.
3 Fernandez Figueras MT. From actinic keratosis to squamous cell carcinoma: pathophysiology revisited. *J Eur Acad Dermatol Venereol* 2017; **31**: 5–7.
4 Roscher I, Falk RS, Vos L *et al.* Validating 4 staging systems for cutaneous squamous cell carcinoma using population-based data: a nested case-control study. *JAMA Dermatol* 2018; **154**: 428–434.
5 Cañueto J, Burguillo J, Moyano-Bueno D *et al.* Comparing the eighth and the seventh editions of the American Joint Committee on Cancer staging system and the Brigham and Women's Hospital alternative staging system for cutaneous squamous cell carcinoma: implications for clinical practice. *J Am Acad Dermatol* 2019; **80**: 106–113.e2.
6 Solus JF, Murphy GF, Kraft S. Cutaneous squamous cell carcinomas of the lower extremities show distinct clinical and pathologic features. *Int J Surg Pathol* 2016; **24**: 29–36.
7 Schmitz L, Gambichler T, Gupta G, Stücker M, Dirschka T. Actinic keratosis area and severity index (AKASI) is associated with the incidence of squamous cell carcinoma. *J Eur Acad Dermatol Venereol* 2018; **32**: 752–756.
8 Hodak E, Jones RE, Ackerman AB. Solitary keratoacanthoma is a squamous-cell carcinoma: three examples with metastases. *Am J Dermatopathol* 1993; **15**: 332–342; discussion 343–352.
9 Savage JA, Maize JC Sr. Keratoacanthoma clinical behavior: a systematic review. *Am J Dermatopathol* 2014; **36**: 422–429.
10 Ikenberg H, Gissmann L, Gross G, Grussendorf-Conen EI, zur Hausen H. Human papillomavirus type-16-related DNA in genital Bowen's disease and in Bowenoid papulosis. *Int J Cancer* 1983; **32**: 563–565.

Migraine is not the most common comorbidity in hidradenitis suppurativa patients

Editor

Migraine is the most common primary headache syndrome worldwide, affecting approximately 12% of the Caucasian population.[1] Migraine has been associated with various cardiovascular[2] and psychiatric comorbidities,[3] more recently inflammatory disorders such as psoriasis[4] and inflammatory bowel disease.[5] As hidradenitis suppurativa (HS) shares common comorbidity risks, we sought to investigate the possible link between migraine and HS. We explored the prevalence of migraine in patients that attended a tertiary care hospital (Department of Dermatology, Helsinki University Hospital, Finland) and reviewed retrospectively all the attending patients with HS diagnosis between January and December 2018. Age, age at onset and at diagnosis, family history, smoking, comorbidities, Hurley stages and affected body sites were inquired in each patient. As the study was based on medical report data with no direct patient contact, no ethical committee statement was required.

Table 1 Characteristics of HS patients with and without migraine

	Migraine *n* (%)	No migraine *n* (%)	$P < 0.05$ Chi-square or Mann–Whitney *U*-test
Total (N)	21	146	
Gender			
Men (%)	2 (9.5)	68 (46.6)	0.001
Women (%)	19 (90.5)	78 (53.4)	
Mean age (years, SD)	33.0 (11.3)	39.2 (14.0)	NS
Mean age at diagnosis (years, SD)	28.4 (12.9)	34.9 (12.8)	NS
Mean age at first symptoms (years, SD)	17.0 (7.8)	27.4 (11.8)	0.001
Familial history of HS*	2/7 (28.6)	24/56 (42.8)	NS
Hurley†			
Hurley I	7 (63.6)	27 (37.5)	NS
Hurley II	3 (27.3)	30 (41.6)	
Hurley III	1 (9.1)	15 (20.8)	
Smoking history			
Ever smokers	13/20 (65)	105/138 (76.1)	NS
Active smokers	10 (50)	72 (52.1)	NS
BMI mean (SD)	33.5 (5.9)	32.3 (8.1)	NS
Comorbidities			
Weight			
Overweight and obesity	18 (85.7)	103 (70.5)	NS
Obesity	13 (61.9)	72 (49.3)	NS
Hypertension	1 (4.8)	36 (24.6)	0.04
Dyslipidaemia	2 (9.5)	16 (10.9)	NS
Thyroid disease	3 (14.3)	15 (10.3)	NS
Diabetes type 2	1 (4.8)	25 (17.2)	NS
Asthma	4 (19.0)	20 (13.7)	NS
Acne	5 (23.8)	41 (28.1)	NS
Autoimmune and inflammatory disorders			
Psoriasis	4 (19.0)	9 (6.2)	0.04
Inflammatory bowel disease (total)‡	1 (4.8)	6 (4.1)	NS
Inflammatory joint disease (total)§	5 (23.8)	7 (4.8)	0.002
Spondyloarthropathy	3 (14.3)	3 (2.0)	0.005
Psychiatric diseases¶	12 (57.4)	48 (32.9)	0.03
Anxiety	4 (19.0)	24 (16.4)	NS
Depression	6 (28.6)	33 (22.6)	NS
Bipolar disorder	4 (19.0)	4 (2.7)	0.001

*Family history could be obtained in 63 patients.
†11 vs. 77 patients.
‡Includes Crohn's disease and ulcerative colitis.
§Includes reactive, rheumatoid, psoriatic arthritis and spondyloarthropathy.
¶Includes also schizophrenia, hyperactivity, binge eating disorder, anorexia, post-traumatic stress disorder, compulsive disorder. Several diagnoses can apply to a patient.
NS, not significant; SD, standard deviation.