UNIVERSITÀ DEGLI STUDI DI TRIESTE

Very High-Resolution Ultrasound of the Distal Median Nerve

This is the peer reviewed (post-print) version of the following article:

Original
Very High-Resolution Ultrasound of the Distal Median Nerve / Ridolfi, M., Caruso, P., Buoite Stella, A., Manganotti, P.. - In: CLINICAL NEUROPHYSIOLOGY. - ISSN 1388-2457. - 131:6(2020), pp. 1267-1271. [10.1016/j.clinph.2020.03.013]

Availability:
This version is available at: 11368/2961586 since: 2020-06-14T14:56:01Z

Publisher:

Published
DOI:10.1016/j.clinph.2020.03.013

Terms of use:

Some rights reserved. More details in the PostPrint rights section below.

License:
Digital Rights Management not defined

Publisher copyright

-.-

(Article begins on next page)

23 October 2026

arTs Università degli Studi di Trieste
Archivio della ricerca – postprint

Very high-resolution ultrasound of the distal median nerve

Mariana Ridolfi, Paola Caruso, Alex Buoite Stella, Paolo Manganotti *

Clinical Unit of Neurology, Department of Medicine, Surgery and Health Sciences, Cattinara University Hospital ASUGI, University of Trieste, Strada di Fiume, 447 – 34149 Trieste, Italy

ARTICLE INFO

Accepted 6 March 2020

Keywords:
Peripheral nervous system
Median nerve
Nerve ultrasound
Very-high-resolution ultrasonography device

HIGHLIGHTS

- Nerve ultrasound (US) is emerging for the study of peripheral neuropathy.
- Standard ultrasound may not be able to detect fascicles of the nerve.
- Very-high-resolution US quantifies fascicles and assesses the digital nerve branches.

ABSTRACT

Objective: A very high-resolution (70 MHz) ultrasound device (VHRUS) has recently been approved for use in humans. The aim of this study was to use VHRUS to collect data on healthy subjects to propose some reference values for the digital branches of the median nerves of the hand.
Methods: A VHRUS with 70 MHz linear array transducer was used to measure the cross sectional area of the median nerve at the wrist (CSA_w) and digital branches (CSA_f), largest and smallest fascicles, the fascicles number (N_{fasc}), the fascicle density (FD), the flattening ratio (FR) and CSA_w/CSA_f.
Results: Data from 20 healthy subjects were obtained for both hands. The median nerve at the wrist and digital branches were properly identified without anatomical alterations. No differences were found between the right and the left hand. In the dominant hand, CSA_w was 9.35 mm^2 (4.57–12.35) and N_{fasc} was 24 (18–38). FD and FR were respectively 2.94 (2.47–4.91) and 2.74 (1.70–4.90).
Conclusion: VHRUS technology can visualize the median nerves at the wrist, their internal structure and their small branches at the fingers, providing both a qualitative and quantitative assessment. Results from this study provide preliminary reference values in a young healthy sample.
Significance: Most conventional ultrasound devices are not able to properly visualize the distal branches of the median nerve. In contrast, VHRUS allows to detect and measure smaller structures of the nerve, assisting in clinical practice.

1. Introduction

Nerve ultrasound (US) represents an emerging technique for the study of peripheral neuropathy (Suk et al., 2013), and in daily clinical practice, the diagnostic evaluation of the peripheral neuropathy is usually supported by nerve conduction study (NCS). However, NCS can be uncomfortable, not universally accessible, and it does not provide a direct assessment of the anatomy of the affected nerve. Nerve US is a non-invasive repeatable technique, cost-effective, and it causes minimal discomfort for the patient. Additionally, it provides high-resolution morphological information of the nerve and surrounding structures which might improve the diagnosis and the decision-making phase of a therapeutic course (Padua et al., 2012; Podnar, 2018). However, it should be accounted that a major limitation is given by the sonographer experience since it might influence US examination's sensitivity.

Technological improvements have been made to improve the overall diagnostic capability of US. Conventional nerve US is typically performed using probes with a frequency varying between 7 and 20 MHz (Goedee et al., 2013), which allows imaging at depths of 2–6 cm but with a resolution of ~500 μm, and may not be sufficiently accurate to visualize the small anatomical structures within a nerve, such as its fascicles (Viviano et al., 2018; Puma et al., 2019). Indeed, standard ultrasound devices might be applied restrictedly to fascicles >1 mm^2 (Grimm et al., 2017). The study of

* Corresponding author at: Clinical Unit of Neurology, Department of Medicine, Surgery and Health Sciences, Cattinara University Hospital ASUGI, University of Trieste, Strada di Fiume, 447 – 34149, Trieste, Strada di Fiume 447, 34100 Trieste, Italy.
E-mail address: pmanganotti@units.it (P. Manganotti).

nerve fascicles may be of great clinical relevance to identify different subtypes of polyneuropathy in which fascicles may be characterized by peculiar alterations (Grimm et al., 2017; Zanette et al., 2018). Additionally, with standard US it may be complicated to identify small nerve branches, such as the sensory terminal digital branches deriving from the palmar division of the median nerve, associated with many nerve disorders (traumatic and iatrogenic nerve injury in the palm of the hand and fingers) (Tagliafico et al., 2008; Zanette et al., 2016). Recently, a very-high-resolution ultrasonography (VHRUS) device has been approved for use in humans. VHRUS include transducers with ultrahigh-frequencies of 48 MHz and 70 MHz, therefore allowing a good quality of more superficial imaging (focal depth 5 mm and image depth (max) 10.0 mm) with a higher resolution power (axial and lateral resolution of 30 μm and 65 μm respectively) compared to standard US (Cartwright et al., 2017). Since the novelty of the device, at the best of the authors' knowledge only one study used VHRUS to determine the quality of imaging of the internal structure of the median nerve at the wrist. Nevertheless, in this study the digital branches of the nerve were not analyzed (Cartwright et al., 2017). Therefore, the aim of the present study was to document whether VHRUS could reliably evaluate the tiny anatomy of the median nerve at the wrist and at the meta-carpal level for each finger in healthy subjects, focusing on nerve fascicles, and providing reference values for the digital branches of the median nerves in the hand.

2. Methods

2.1. Participants

Twenty healthy subjects were invited to participate in the study. Demographic information obtained from each participant included age, sex, body mass, height, and race. Body mass index (BMI) was calculated for each participant (kg/m^2). Participants were excluded if they reported recent traumas or surgical interventions, presence of pain or alterations of sensitivity, or if they were diagnosed with neurological or musculoskeletal diseases. All the participants gave written informed consent before inclusion in the study. All the procedures were performed according to the guidelines of the Declaration of Helsinki and with Institutional Review Board and regional Ethics Board (CEUR) approval.

2.2. Protocol and measurements

All the participants underwent selective median and proper digital nerve ultrasounds at the wrist during a single VHRUS assessment session. US was performed using a ultrahigh-frequency ultrasound device (Vevo MD, Fujifilm VisualSonics, Canada) with a 70 MHz linear array transducer, with an axial resolution of 30 μm, image width (Max) of 9.7 mm and image depth (Max) of 10.0 mm (focal depth 5 mm, median depth 7 mm). Wrist and fingers VHRUS assessment was performed with the participant in a supine neutral position resting on a table. The nerve assessment was performed in the transverse and in the longitudinal plane. The median nerve was assessed at the location immediately proximal to the tunnel just before the nerve dips deeply to enter the carpal tunnel, and then at the fingers in correspondence of the distal part of metacarpals/proximal phalanx (Fig. 1). Four of the seven digital nerve branches were analyzed for better quality and reliability according to the ultrasonographer experience. Sonographic criteria for nerve identification were based on the detection of the fascicular echotexture, according to criteria described in literature (Cartwright et al., 2017). All images acquisition and measurements were performed by the same single ultrasonographer for all participants, and two raters independently counted

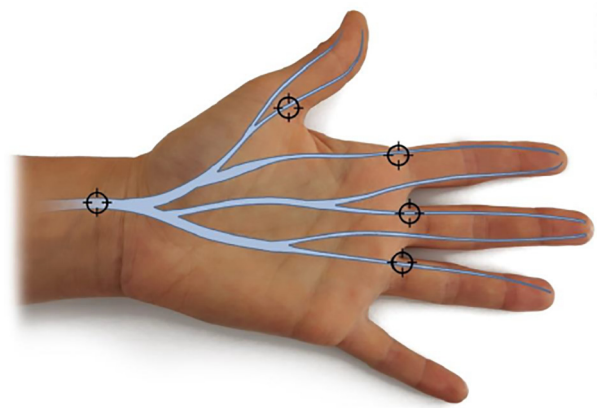

Fig. 1. Representation of selected nerves and branches for the axial scan of the median nerve at the wrist and at the fingers.

the number of fascicles within each nerve. Quantitative analysis was provided by measuring the structures cross sectional area (CSA) with the appropriate device tool. CSA (mm^2) of the whole nerve was determined using the trace function to outline the nerve along the inner border of the epineurium. Additionally, the CSA of the largest and smallest fascicles (CSA_{fasc} large, CSA_{fasc} small) was measured with the same protocol. Fascicle density (FD), i.e. the fascicles number per mm^2, was calculated by dividing the number of fascicles by the median nerve area (Cartwright et al., 2017). The flattening ratio (FR) was defined as the ratio of the major-to-minor axes of the median nerve. The ratio between the median nerve CSA from proximal to the tunnel at the wrist (CSA_w) to the fingers (CSA_f) was expressed as CSA_w divided by CSA_f for each finger (CSA_w/CSA_f). Finally, the presence of intraneural vascularity at any part of the nerve was assessed with the same 70 MHz probe, muscle setting, at a depth 0f 2–7 mm, a pulse repetition frequency of 10 cm/s and power color Doppler mode.

2.3. Statistical analysis

All analyses were conducted using IBM SPSS Statistics (v.22.0, Chicago, IL, USA). Continuous variables were presented as medians (ranges) and means. Inclusion of both medians and means was provided according to previous literature (Cartwright et al., 2017). Categorical variables as counts and percentages (%). The Wilcoxon signed-rank test was performed to compare nerves from the right and the left side of the same participant. A bivariate correlation analysis was used to determine the degree of correlation between age, sex, body mass, height, BMI and parameters measured, using Person correlation coefficient. A value of $p < 0.05$ was considered significant.

3. Results

Twenty healthy volunteers (males 55%; females 45%) were included in the study. Demographic characteristics (age, body mass, height and BMI) are summarized in Table 1. Among them,

Table 1
Participants' demographics. Data are presented as medians (range).

Personal Characteristics	n = 20
Females [n (%)]	9 (45)
Age [y]	27.2 (20.0–41.0)
Body Mass [kg]	66.1 (52.0–115.0)
Height [cm]	175.2 (157–197)
BMI [kg/m^2]	21.7 (17.5–29.6)

Table 2
Participants' VHRUS outcomes the right (dominant) and left (non-dominant) hand. Data are presented as medians (range) and means.

Outcomes	Right n = 20	Left n = 20
CSA_w (mm^2)	9.35 (4.57–12.35) 8.70	7.84 (5.71–11.49) 8.25
CSA_{fasc} large (mm^2)	0.48 (0.22–0.70) 0.47	0.46 (0.22–0.76) 0.50
CSA_{fasc} small (mm^2)	0.04 (0.02–0.09) 0.05	0.04 (0.03–0.09) 0.05
Nf_{asc} (count)	24 (18–38) 26	25 (18–34) 25
FD	2.94 (2.47–4.91) 3.09	3.03 (2.28–4.05) 3.12
FR	2.74 (1.70–4.90) 3.00	3.33 (1.51–5.63) 3.47
CSA_f 1 (mm^2)	0.66 (0.35–1.13) 0.69	0.72 (0.44–1.30) 0.75
CSA_f 2 (mm^2)	0.64 (0.32–1.38) 0.70	0.62 (0.34–0.93) 0.63
CSA_f 3 (mm^2)	0.58 (0.27–1.42) 0.67	0.56 (0.38–1.13) 0.63
CSA_f 4 (mm^2)	0.59 (0.32–0.91) 0.67	0.56 (0.26–0.89) 0.56
CSA_w/CSA_f 1	12.79 (6.11–26.91) 13.47	11.62 (5.39–21.99) 11.81
CSA_w/CSA_f 2	12.80 (8.92–23.73) 13.36	13.77 (6.48–24.27) 13.86
CSA_w/CSA_f 3	13.06 (6.86–29.59) 14.46	13.75 (8.13–17.90) 13.66
CSA_w/CSA_f 4	14.42 (5.98–29.81) 15.08	14.75 (8.30–23.98) 15.55

Notes: cross sectional area proximal to the tunnel inlet at the wrist (CSA_w, mm^2), cross sectional area of the largest (CSA_{fasc} large) and smallest (CSA_{fasc} small) fascicle in the median nerve at the wrist (mm^2), number of fascicles in the median nerve at the wrist (N_{fasc}, count), fascicle density (FD), flattening ratio (FR), cross sectional area of the digital branches of the median nerve (CSA_f 1, 2, 3, 4, mm^2), ratio between the CSA_w and CSA_f of the digital branches of the median nerve.

seventeen (85%) were right-handed. Anatomic anomalies were no detected in all included participants. All median nerves at the wrist and at the meta-carpal level for each finger (and corresponding fascicles) were completely visualized in their distinct architecture and well defined from the surrounding tissue. Median CSA_w was 9.35 mm^2 (4.57–12.35) in the right hand and 7.84 mm^2 (5.71–11.49) in the left hand. Median CSA_{fasc} large and CSA_{fasc} small were 0.48 mm^2 (0.22–0.70) and 0.04 mm^2 (0.02–0.09) respectively for the right hand, and 0.46 mm^2 (0.22–0.76) and 0.04 mm^2 (0.03–0.09) for the left hand. The median fascicle count for all median nerves was 24 and 25 at the right and left side of the body, respectively. The median CSA of the four branches (1, 2, 3, 4) at the fingers were 0.66, 0.64, 0.58, 0.59 mm^2 and 0.72, 0.62, 0.56, 0.56 mm^2 at right and left side, respectively. No significant differences were found between the same branch in the left or right side of the body. VHRUS outcomes for the right (dominant) and left (non-dominant) hand are shown in Table 2. Color Doppler signals were not observed in any of the measured nerves. Correlation analysis suggested no significant associations between age, sex, body mass, height, BMI and VHRUS measures. Fig. 2 shows an example of acquired images of the median nerve at the wrist and its digital branches. A comparison between the VHRUS and the conventional US is provided in Fig. 3 showing the same digital branch of one subject.

4. Discussion

Findings from this study suggest that the use of VHRUS for the assessment of peripheral nerve is able to detect and visualize nervous structures with a greater quality compared to the standard US, helping to the define the number and the size of its internal fascicles, and providing a trustworthy quantitative assessment of CSA. Additionally, VHRUS is found to be able to visualize also the small digital branches of the median nerve, commonly not observed or observed with poor quality, with the use of standard US. It was possible to properly evaluate fascicles numbers and fascicle echogenicity, to identify eventual nerve innervation, and to measure nerve diameters and the ratio between major and minor diameters. Finally, it was possible to observe the nerve's terminal digital branches, distal to the carpal tunnel, suggesting additional information about some anatomical structure often involved in trauma or during surgery (Tagliafico et al., 2008; Zanette et al., 2018).

The results presented in this study are in line with previously reported values (both with standard US and in some cases with VHRUS). Indeed, mean CSA at the wrist was 8.70 mm^2 (4.57–12.35) in the right hand and 8.25 mm^2 (5.81–11.49) in the left median nerve. These data are in line with previous results using

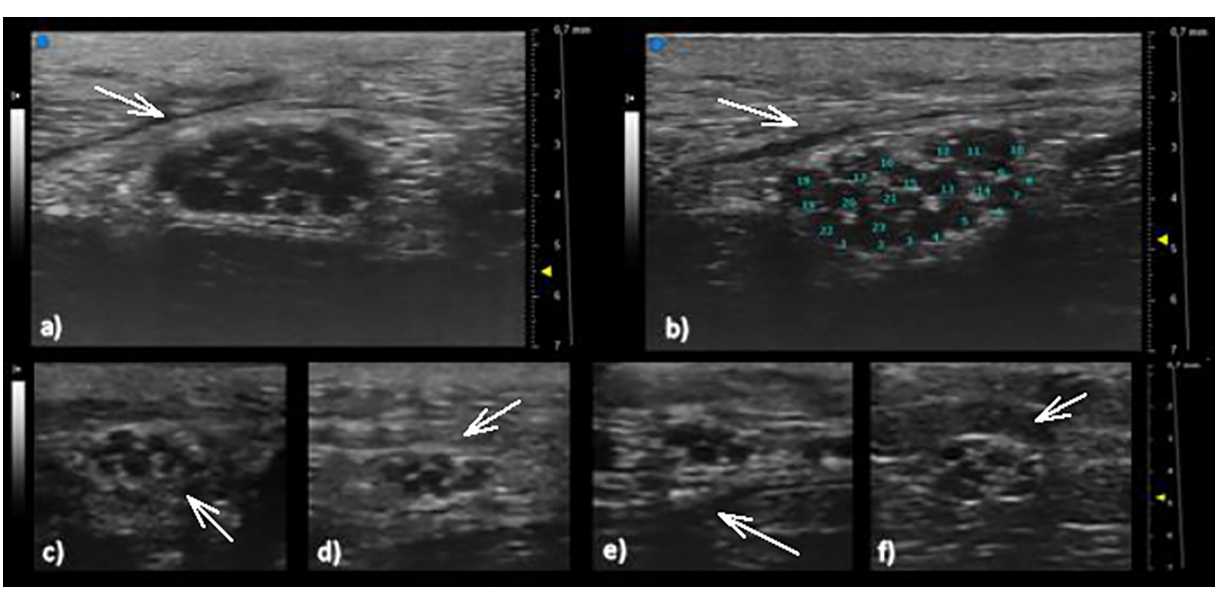

Fig. 2. Left median nerve. (a) Nerve at the wrist; (b) nerve fascicles count; (c) (d) (e) (f) digital nerve branches at the first, second, third and fourth finger.

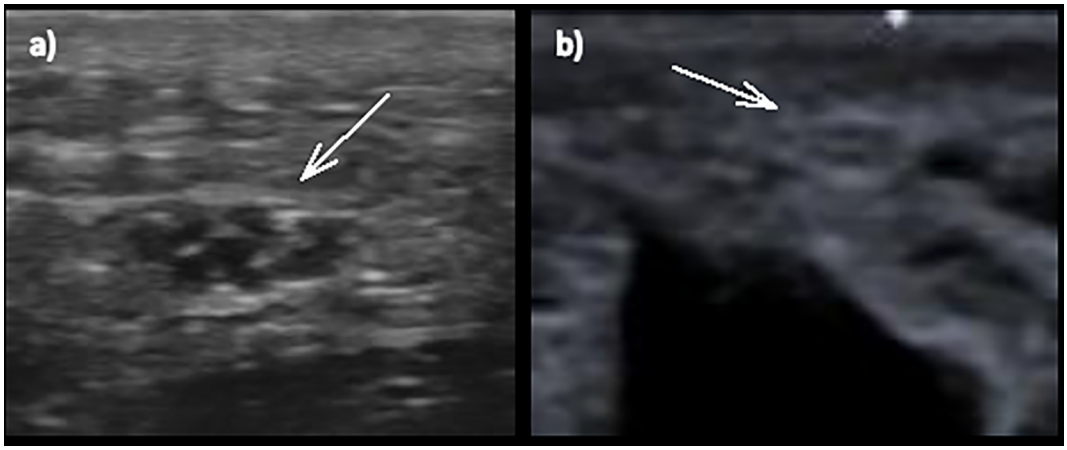

Fig. 3. Digital median branch: (a) VHRUS (70 MHz); (b) Conventional (18 MHz) nerve ultrasound. VHRUS: very high-resolution ultrasound.

an 18 MHz linear array transducer suggesting a mean CSA of 8.43 mm^2 (4.29–12.57) (Kerasnoudis et al., 2013). Slightly higher values were found in a study that used a 70 MHz linear transducer on 20 healthy volunteers, suggesting mean CSA of 10.79 mm^2 (7.00–17.84) and 10.88 mm^2 (7.42–16.38) at the right and left side respectively (Cartwright et al., 2017). Nevertheless, it should be considered that in the above mentioned study were included participants with bifid median nerves, which have been shown to have a relatively higher CSA compared to non-bifid median nerves (Bayrak et al., 2008). Such anatomical anomalies were not present in our sample. The high resolution of VHRUS allows visualizing the sensory terminal digital branches deriving from the palmar division of the median nerve, permitting to distinguish the hyperechoic rim of the single branches and the surrounding structures. Results from this study on healthy subjects reported normal values of CSA and a normal ratio between the CSA of the median nerve at wrist and CSA of the single digital branches.

Besides CSA, previous studies have assessed nerve fascicles. Fascicles and changes in fascicle size have been reported in trauma and different neuropathies; however, identification and quantitative assessment of fascicles characteristics may be complex with the standard US. Indeed, standard probes may overestimate the mean fascicle size since it may be represented by the sum of several indistinguishable smaller fascicles (Viviano et al., 2018). VHRUS has been recently used to measure fascicles CSA of median and ulnar nerves of patients with chronic inflammatory demyelinating polyneuropathy (CIDP) (Puma et al., 2019). In this study, the authors indicated that VHRUS may better characterize fascicles size and morphology, and to assess nerve vascularization, compared to an 18–20 MHz high frequency ultrasound. Therefore, VHRUS may assist clinicians and researchers to better identify the hypoechoic margin of the fascicles, distinguishing in more detail the borders and providing a better definition of these structures.

In this study we reported characteristics of the largest and smallest fascicles within each median nerve at the wrist. The mean fascicle number and the mean fascicle density found in this study were slightly higher than the values reported in previous research with VHRUS (Cartwright et al., 2017). However, the authors reported subgroup differences between subjects with or without bifid median nerves and persistent median arteries that may have affected the overall median. Other factors that may have clinical relevance and that may be examined with US are the nerve diameters and the ratio between major and minor diameters (i.e, FR). FR was previously measured in patients with carpal tunnel syndrome (CTS) with 12–17 MHz transducers, finding CTS patients were characterized by significantly flatter nerves at the tunnel inlet compared to control healthy subjects (Ng et al., 2018). Nevertheless, to the authors' knowledge no data are present for FR measured with VHRUS besides those suggested in the present study on healthy subjects. Additionally, VHRUS may be a valuable tool for identifying peri- and endoneural vascularization. Being nerve vascularization a possible marker for inflammation (Puma et al., 2019) may explain the absence of color Doppler signals in our sample of young healthy adults.

4.1. Limitation and future perspectives

The median age of the included sample was 27 y, therefore representing a potential limitation to the generalizability of the study, since the present results should be considered only for healthy young adults, whereas caution should be taken when translated to very young or very old persons. Moreover, the relatively small size of the sample and the assessment of only 4 of the 7 digital nerve branches represent further limitations of the study. Nevertheless, these preliminary results provide the basis for future studies, suggesting reference values that should be confirmed in future studies on larger samples and in well-defined age categories.

5. Conclusions

Results from this study provide preliminary reference values for young healthy subjects, encouraging the diffusion of VHRUS in the field of traumatology and neuropathies, both in the acute phase and during the post-treatment. Additionally, since nerve CSA may be normal in some neuropathies, the study of small branches and single fascicles may help clinicians to find early signs of the disease. Since the recent development of the high-resolution devices, more research is needed to explore alterations due to individual characteristics, ageing, or different diseases progression.

Ethical Publication Statement

We confirm that we have read the Journal's position on issues involved in ethical publication and affirm that this report is consistent with those guidelines.

Disclosure of Conflicts of Interest

None of the authors has any conflict of interest to disclose.

References

Bayrak IK, Bayrak AO, Kale M, Turker H, Diren B. Bifid median nerve in patients with carpal tunnel syndrome. J Ultrasound Med. 2008;27:1129–36.

Cartwright MS, Baute V, Caress JB, Walker FO. Ultrahigh-frequency ultrasound of fascicles in the median nerve at the wrist. Muscle Nerve 2017;56:819–22.

Goedee HS, Brekelmans GJF, van Asseldonk JTH, Beekman R, Mess WH, Visser LH. High resolution sonography in the evaluation of the peripheral nervous system in polyneuropathy - a review of the literature. Eur J Neurol 2013;20:1342–51.

Grimm A, Winter N, Rattay TW, Härtig F, Dammeier NM, Auffenberg E, et al. A look inside the nerve – Morphology of nerve fascicles in healthy controls and patients with polyneuropathy. Clin Neurophysiol 2017;128:2521–6.

Kerasnoudis A, Pitarokoili K, Behrendt V, Gold R, Yoon M-S. Cross sectional area reference values for sonography of peripheral nerves and brachial plexus. Clin Neurophysiol 2013;124:1881–8.

Ng AWH, Griffith JF, Lee RKL, Tse WL, Wong CWY, Ho PC. Ultrasound carpal tunnel syndrome: additional criteria for diagnosis. Clin Radiol 2018;73:214.e11–18.

Padua L, Liotta G, Di Pasquale A, Granata G, Pazzaglia C, Caliandro P, et al. Contribution of ultrasound in the assessment of nerve diseases. Eur J Neurol 2012;19:47–54.

Podnar S. Contribution of ultrasonography to the evaluation of peripheral nerve disorders. Neurophysiol Clin 2018;48:119–23.

Puma A, Azulay N, Grecu N, Suply C, Panicucci E, Cambieri C, et al. Comparison of high-frequency and ultrahigh-frequency probes in chronic inflammatory demyelinating polyneuropathy. J Neurol 2019;266:2277–85.

Suk JI, Walker FO, Cartwright MS. Ultrasonography of peripheral nerves. Curr Neurol Neurosci Rep 2013;13:328.

Tagliafico A, Pugliese F, Bianchi S, Bodner G, Padua L, Rubino M, et al. High-resolution sonography of the palmar cutaneous branch of the median nerve. AJR Am J Roentgenol 2008;191:107–14.

Viviano SL, Chandler LK, Keith JD. Ultrahigh frequency ultrasound imaging of the Hand: A new diagnostic tool for hand surgery. Hand (N Y). 2018;13:720–5.

Zanette G, Fabrizi GM, Taioli F, Lauriola MF, Badari A, Ferrarini M, et al. Nerve ultrasound findings differentiate Charcot-Marie-Tooth disease (CMT) 1A from other demyelinating CMTs. Clin Neurophysiol 2018;129:2259–67.

Zanette G, Lauriola MF, Tamburin S. Electrodiagnosis of lesions of median and ulnar nerve hand sensory branches: A case series. J Clin Neurophysiol 2016;33:454–7.