UNIVERSITÀ DEGLI STUDI DI TRIESTE

Endomyocardial fibrosis of the right ventricle: A case report of successful surgery

This is the peer reviewed (post-print) version of the following article:

Original
Endomyocardial fibrosis of the right ventricle: A case report of successful surgery / Negri, F., Fabris, E., Mase, M., Vitrella, G., Mina, C., Turrisi, M., Liotta, R., Gentile, G., Pilato, M., Sinagra, G., Clemenza, F.. - In: JOURNAL OF CARDIAC SURGERY. - ISSN 0886-0440. - 35:2(2020), pp. 460-463. [10.1111/jocs.14378]

Availability:
This version is available at: 11368/2964660 since: 2020-05-16T20:49:52Z

Publisher:

Published
DOI:10.1111/jocs.14378

Terms of use:

Some rights reserved. More details in the PostPrint rights section below.

License:
Digital Rights Management not defined

Publisher copyright

-.-

(Article begins on next page)

22 October 2026

arTs Università degli Studi di Trieste
Archivio della ricerca – postprint

Endomyocardial fibrosis of the right ventricle: A case report of successful surgery

Francesco Negri MD[1] | Enrico Fabris MD[2] | Marco Masè MD[2,3] | Giancarlo Vitrella MD[2] | Chiara Minà MD[4] | Marco Turrisi MD[4] | Rosa Liotta MD[4] | Giovanni Gentile MD[4] | Michele Pilato MD[4] | Gianfranco Sinagra MD, FESC[2,3] | Francesco Clemenza MD[4]

[1]Cardiovascular Department, Azienda Sanitaria Universitaria Integrata di Udine, Udine, Italy

[2]Cardiovascular Department, Cardiomyopathy Center, Azienda Sanitaria Universitaria Integrata di Trieste, Trieste, Italy

[3]Postgraduate School in Cardiovascular Disease, University of Trieste, Italy

[4]IRCCS-ISMETT Istituto Mediterraneo per i Trapianti e Terapie ad Alta Specializzazione, Palermo, Italy

Correspondence
Francesco Negri, Cardiovascular Department, Azienda Sanitaria Universitaria Integrata di Udine, Italy, Via Zermenese 42, 31100 Treviso, Italy.
Email: francesco_negri@yahoo.it

Abstract

Aims: The case we report, shows a successful treatment of right ventricle endomyocardial fibrosis.

Materials and Methods: Surgical therapy by endocardial decortication seems to be beneficial for many patients with advanced disease who are in functional-therapeutic class III or IV. The operative mortality rate is high, but successful surgery has a clear benefit on symptoms and seems to favourably affect survival as well.

KEYWORDS

cardiomyopathies, cardiomyopathy, endomyocardial fibrosis, heart failure, tricuspid insufficiency

1 | INTRODUCTION

A 42-year-old man, native of Ghana, was admitted to the ED for fatigue, following an episode of fever. Echocardiography showed moderate dilation of the right ventricle (RV) with partial obliteration of the RV apex and diffuse hypokinesia determining mild systolic dysfunction. Mild tricuspid regurgitation and mild bi-atrial dilation were present; conversely, the left ventricle was normal.

Holter-ECG, cycle ergometer stress-test as well as cardiac right and left catheterization showed no abnormalities. To determine the nature of the mass partially obliterating the RV apex, an endomyocardial biopsy was performed. Biopsy specimens histological examination revealed coarse thickening of the endocardium (Figure 1 panel A) with evidence of interstitial fibrosis (Figure 1 panel B), diffuse calcification, also in the form of ossification (Figure 1 panel C), fragmentation and derangement of reticular and elastic fibers (Figure 1 panel D) and hypertrophic cardiomyocytes with involution of the contractile system, sometimes with a "fern leaf" morphology (Figure 1 panel E).

A diagnosis of endomyocardial fibrosis (EMF) without signs of inflammatory activity was made. The patient was discharged on ACE-inhibitor, diuretics, ASA, and warfarin. During the following years, the patient was clinically stable.

At the age of 62 years, he was admitted to the hospital for acute heart failure. Echocardiography showed the progression of RV dilation with moderate systolic dysfunction (TAPSE 7 mm, S′ 0.07 m/s) along with the presence of severe tricuspid regurgitation (online video 2 and Figure 2 panel B). The RV apex was still partially obliterated by a thick hyperechogenic mass (Figure 2 panel A). To accurately define cardiac chamber dimensions and function, a cardiac magnetic resonance (CMR) was performed. CMR showed right atrial dilatation (planimetric area 46 cm^2), severe tricuspid regurgitation, RV dilation (iEDV: 98 mL/m^2) with partial obliteration of RV apex (Figure 3 panel A,B). Laboratory blood tests showed no sign of ongoing inflammation with a normal white cell count. A new endomyocardial biopsy confirmed the previous diagnosis of EMF without signs of inflammatory activity. After the Heart Team discussion, the patient underwent cardiac surgery. Following the

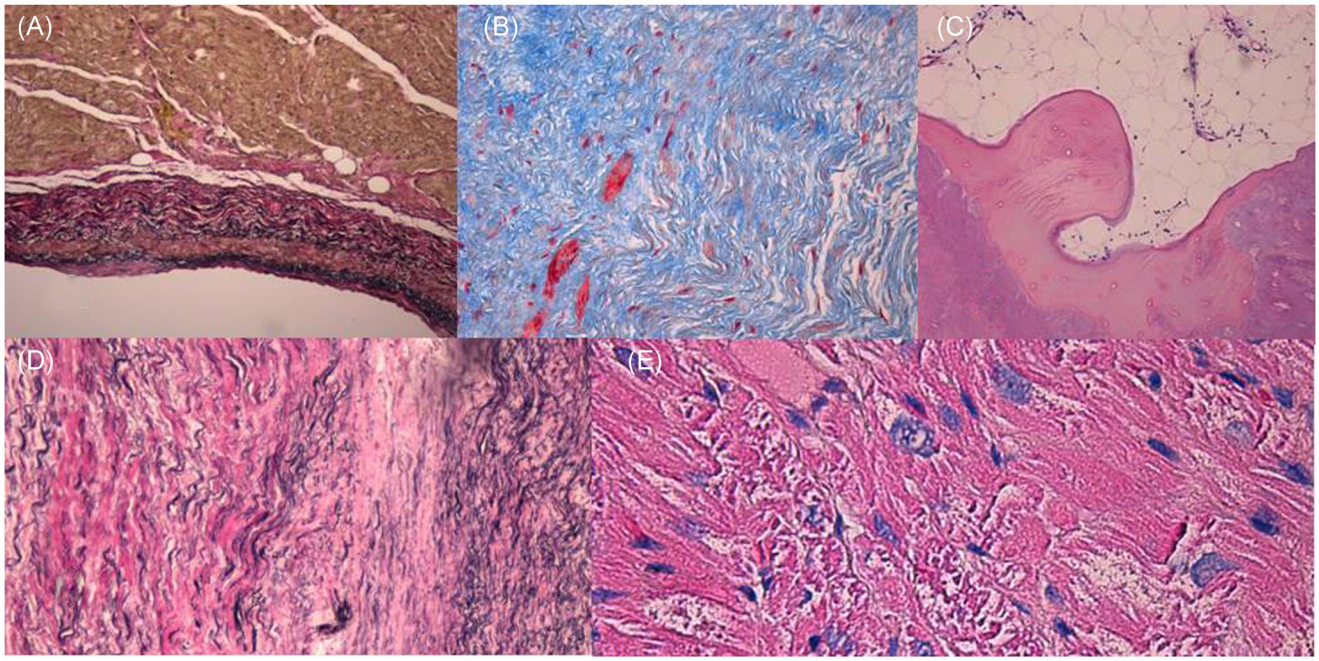

FIGURE 1 Coarse thickening of the endocardium (panel A) with evidence of interstitial fibrosis (panel B), diffuse calcification (also in the form of ossification) (panel C), fragmentation and derangement of reticular and elastic fibers (panel D); hypertrophic cardiac myocytes with involution of the contractile system, sometimes with a fern leaf morphology (panel E)

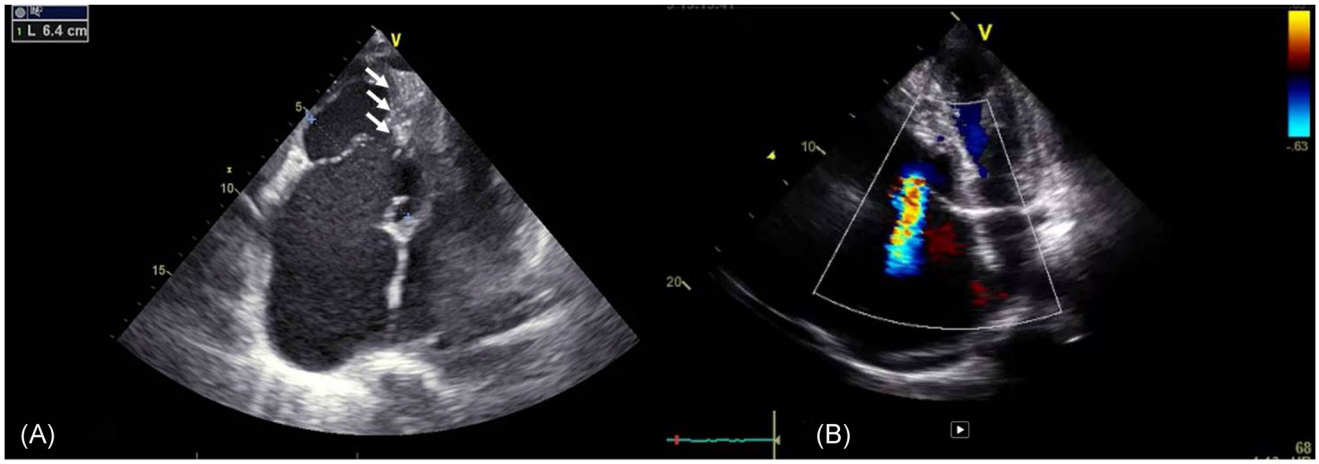

FIGURE 2 Panel A, Transthoracic echocardiography shows the partial obliteration of the RV apex (white arrows) and the severe RV dilatation (RV basal diameter 6.4 cm). Panel B, Transthoracic echocardiography shows severe tricuspid regurgitation due to failure of tricuspid leaflet coaptation

institution of cardiopulmonary bypass (CPB) via aortobicaval cannulation, the patient's heart was arrested with cold, crystalloid cardioplegia. After sternotomy and subsequent right atriotomy, RV decortication of calcific-fibrotic endomyocardial tissue was performed with the unbridling of the right ventricular wall and papillary muscles (Figure 4 panel A). Severe tricuspid regurgitation was treated with anterior leaflet repair and annuloplasty using a 36-mm flexible ring (Figure 4 panel B). The resolution of myocardial restriction was obtained after the procedure. Ultimately, the right atrial dimension was reduced and left appendage amputated. The CPB and arrest times were 120 and 80 minutes, respectively.

At 1-year follow-up the patient was asymptomatic. Echocardiography showed an important reduction of right atrial dimension, and complete resolution of tricuspid regurgitation (Figure 5 panel A,B).

2 | DISCUSSION

EMF is a condition characterized by biventricular, right or less frequently left ventricular endomyocardial deposition of fibrous tissue. An active, usually relapsing inflammatory phase is followed by a chronic stage that eventually leads to restrictive physiology and

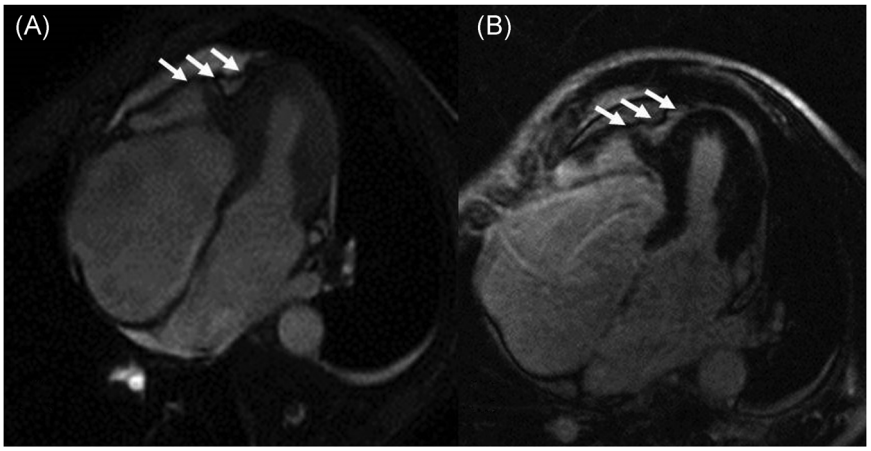

FIGURE 3 Panel A, Balanced steady-state free precession (bSSFP) imaging, 4-chamber view: partial obliteration of right ventricular apex; Panel B, the same imaging after late gadolinium enhancement

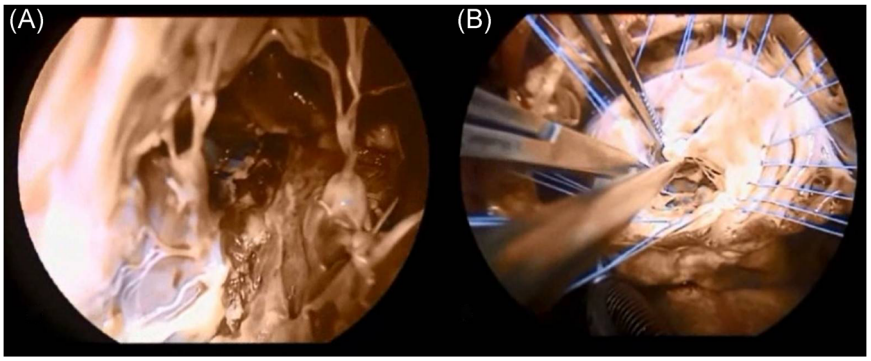

FIGURE 4 Panel A, Ventricular surgical view, shows calcific-fibrotic endomyocardial tissue involving the right ventricular endomiocardial and the papillary muscles. Panel B, Atrial view repair of the anterior leaflet and applying an annuloplasty with 36 mm flexible ring

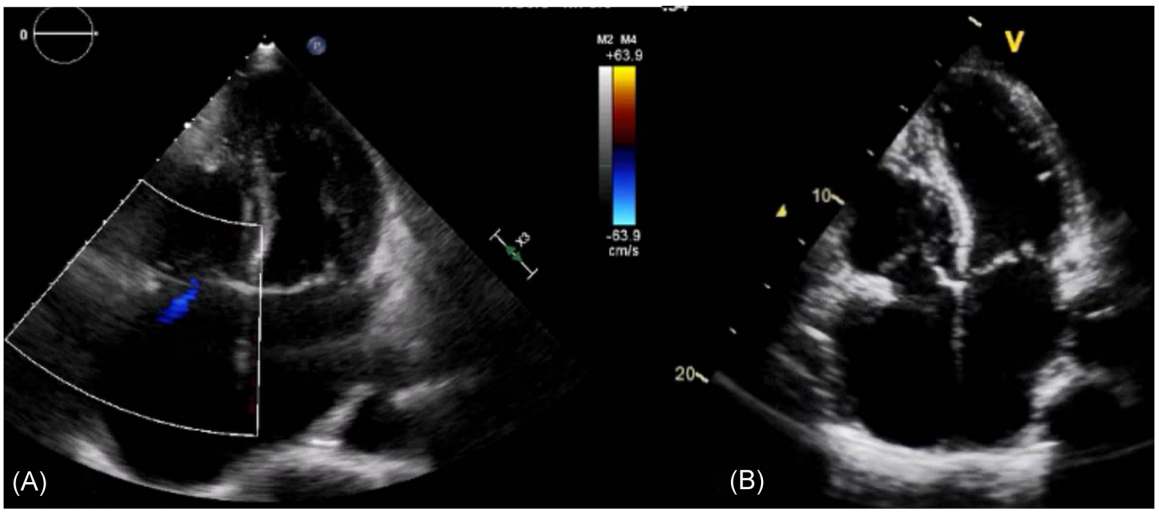

FIGURE 5 Panel A and B Transthoracic echocardiography at 1-year follow-up from the procedure

ventricular dysfunction. EMF etiology is unknown. Genetic and environmental factors have been claimed to be part of its pathogenesis. Typical of tropical latitudes, due to the increasing international migration flow form these regions, EMF prevalence in developed countries is raising.[1]

In our case report, we presented a typical case of EMF. As in other studies, we did not witness stigmata of inflammation or eosinophilia on EMB specimens; it has been argued that at the final stages of disease, the active inflammatory process is extinct.[2] Medical management consists of symptomatic treatment of heart failure: diuretics, angiotensin-converting enzyme inhibitor as well as anticoagulation or aspirin due to increased risk of ventricular thrombosis.[3]

Immunosuppression treatment is reserved on top of optimal medical heart failure treatment only in the subset of patients with an active phase of EMF.[1]

Only a small series on surgical option have been published,[4,5] and no controlled data are available. However, endomyocardial decortication with valve repair or replacement can relieve patient's symptoms, especially in subjects in advanced heart failure and severe valvular regurgitation, offering the chance of

long-term survival in spite of high perioperative mortality (up to 20%).[1,4] Valve sparing techniques are less commonly carried out since the valvular apparatus is often involved in the disease process.[6] Depending on the ventricle involved, local expertise and location of fibrosis, transarterial, transapical, or transaortic access can be used.[7] In our case, the surgical procedure resulted in clinical and functional improvement. This was confirmed on the echocardiographic examination which showed resolution of tricuspid regurgitation and re-establishment of a normal proportion in the dimension of the right chambers. Given that, questions remain about appropriate timing and long-term prognosis of such strategies.

ORCID

Francesco Negri

REFERENCES

1. Grimaldi A, Mocumbi AO, Freers J, et al. Tropical endomyocardial fibrosis: natural history, challenges, and perspectives. *Circulation*. 2016; 133(24):2503-2515.
2. Chopra P, Narula J, Talwar KK, Kumar V, Bhatia ML. Histomorphologic characteristics of endomyocardial fibrosis: an endomyocardial biopsy study. *Hum Pathol*. 1990;21(6):613-616.
3. Pereira NL, Grogan M, Dec GW. Spectrum of restrictive and infiltrative cardiomyopathies. *J Am Coll Cardiol*. 2018;71(10):1149-1166.
4. Yangni-Angate KH, Meneas C, Diby F, Diomande M, Adoubi A, Tanauh Y. Cardiac surgery in Africa: a thirty-five-year experience on open heart surgery in Cote d'Ivoire. *Cardiovasc Diagn Ther*. 2016;6(suppl 1):S44-S63.
5. Moraes F, Lapa C, Hazin S, Tenorio E, Gomes C, Moraes CR. Surgery for endomyocardial fibrosis revisited. *Eur J Cardiothorac Surg*. 1999; 15(3):309-313.
6. Schneider U, Jenni R, Turina J, Turina M, Hess OM. Long-term follow up of patients with endomyocardial fibrosis: effects of surgery. *Heart*. 1998;79(4):362-367.
7. Joshi R, Abraham S, Kumar AS. New approach for complete endocardiectomy in left ventricular endomyocardial fibrosis. *J Thorac Cardiovasc Surg*. 2003;125(1):40-42.