

The electrocardiogram in the diagnosis and management of patients with dilated cardiomyopathy

Gherardo Finocchiaro^{1*}, Marco Merlo², Nabeel Sheikh¹, Giulia De Angelis², Michael Papadakis³, Iacopo Olivetto⁴, Claudio Rapezzi^{5,6}, Gerald Carr-White¹, Sanjay Sharma³, Luisa Mestroni⁷, and Gianfranco Sinagra²

¹Cardiothoracic Centre, Guy's and St Thomas' Hospital, London, UK; ²Cardiovascular Department, A.O.U. Ospedali Riuniti, Trieste, Italy; ³Cardiology Clinical and Academic Group St George's, University of London, London and St George's University Hospital NHS Foundation Trust, London, UK; ⁴Cardiomyopathy Unit, Careggi University Hospital, Florence, Italy; ⁵Cardiology, University of Ferrara and Maria Cecilia Hospital, Cotignola, Italy; ⁶GVM Care & Research, Cotignola, Italy; and ⁷Cardiovascular Institute and Adult Medical Genetics Program, University of Colorado Anschutz Medical Campus, Aurora, CO, USA

Received 22 November 2019; revised 12 March 2020; accepted 14 March 2020; online publish-ahead-of-print 3 April 2020

The term dilated cardiomyopathy (DCM) defines a heterogeneous group of cardiac disorders, which are characterized by left ventricular or biventricular dilatation and systolic dysfunction in the absence of abnormal loading conditions or coronary artery disease sufficient to cause global systolic impairment. In approximately one third of cases, DCM is familial with a genetic pathogenesis and various patterns of inheritance. Although the electrocardiogram (ECG) has been considered traditionally non-specific in DCM, the recently acquired knowledge of the genotype–phenotype correlations provides novel opportunities to identify patterns and abnormalities that may point toward specific DCM subtypes. A learned ECG interpretation in combination with an appropriate use of other ECG-based techniques including ambulatory ECG monitoring, exercise tolerance test and imaging modalities, such as echocardiography and cardiovascular magnetic resonance, may allow the early identification of specific genetic or acquired forms of DCM. Furthermore, ECG abnormalities may reflect the severity of the disease and provide a useful tool in risk stratification and management. In the present review, we discuss the current role of the ECG in the diagnosis and management of DCM. We describe various clinical settings where the appropriate use and interpretation of the ECG can provide invaluable clues, contributing to the important role of this basic tool as cardiovascular medicine evolves.

Keywords Electrocardiogram • Dilated cardiomyopathy • Diagnosis • Management

Introduction

Dilated cardiomyopathy (DCM) is currently defined by the presence of left ventricular (LV) or biventricular dilatation and systolic dysfunction in the absence of abnormal loading conditions or coronary artery disease sufficient to cause global systolic impairment.¹ Dilated cardiomyopathy is an umbrella definition that encompasses multiple disorders where myocardial abnormality is not related to coronary or valvular or congenital heart disease and cannot be explained by abnormal haemodynamic conditions.² Besides being very generic, the term DCM may be downright inaccurate, as chamber dilatation is often absent: indeed, the term 'dilated' has recently been questioned. This nosographic complexity builds on a significant genetic heterogeneity with mutations found to be linked

to the disease in at least 50 different individual genes and a polymorphic clinical presentation with arrhythmias and heart failure being the most common manifestation.¹

Recent technological advances in cardiovascular imaging, particularly the increasingly widespread use of cardiovascular magnetic resonance (CMR), offer an opportunity for deep phenotypic and aetiological definition through tissue characterization, allowing the identification of among others oedema, fibrosis, or infiltration. Yet, in this complex landscape full of rapidly developing diagnostic technologies, the electrocardiogram (ECG) retains an extremely powerful role in the assessment of patients with DCM, which can provide diagnostic red flags useful to orient the following phases of the diagnostic work-up, prognostic stratification criteria and information that can direct appropriate decision making.

*Corresponding author. Guy's and St. Thomas's Hospital, Westminster Bridge Road, Lambeth, London SE1 7EH, UK. Email: gherardo.finocchiaro@nhs.net

In this review, we will discuss the several reasons why the ECG is still a paramount piece of the puzzle in diagnosis, risk stratification and management of DCM. Following an overview of abnormalities involving each segment of the ECG, individual diseases characterized by specific patterns are discussed in detail.

Methods

The authors approached the topic formulating the research question: what is the role of ECG in diagnosis and management of DCM? Therefore a systematic search through the web-based engine PubMed was conducted in order to identify all studies meeting the eligibility criteria. The most relevant studies answering the main research question were selected. Finally, results were presented systematically taking into account the complexity of the disease and the various aetiologic backgrounds.

Systematic approach in ECG interpretation

Electrocardiographic abnormalities characterize the majority of patients with DCM, with abnormal ECG features reported in more than 80% of the cases (Table 1).^{3–10} Despite the traditional opinion that ECG abnormalities in DCM are non-specific, in contrast with other cardiomyopathies, such as hypertrophic cardiomyopathy (HCM) or arrhythmogenic right ventricular cardiomyopathy (ARVC), recent advances in the understanding of genotype–phenotype correlations provide the opportunity to recognize specific ECG patterns that are typical of certain genetic or acquired forms of DCM.⁵ As the ECG is rarely normal in DCM, ECG abnormalities should trigger the initiation of a diagnostic work-up. However, when interpreting the ECG of patients with cardiomyopathies, the approach should be ‘cardiomyopathy-oriented’, i.e. abandoning classical concepts derived from the world of ischaemic and hypertensive heart disease, and focusing on specific ‘red flags’ (Table 2)^{1,11–19} that should be carefully integrated in the broader clinical and familial context.

P wave

Atria are often dilated in DCM, reflecting raised filling pressures and/or associated valvular abnormalities. This may be reflected on the ECG with P-wave changes suggestive of left and/or atrial enlargement.²⁰ While isolated right atrial enlargement is uncommon,^{3,5,6} left atrial enlargement is seen in a variable proportion of patients and is often considered a marker of long-standing disease.^{3,5–7} Atrial fibrillation (AF) is a common pathway for all forms of DCM following progression to heart failure. Early onset of AF in young individuals, however, may suggest specific DCM aetiologies, mainly of genetic origin¹² (Table 2).

PR interval

First-degree and/or advanced atrio-ventricular (AV) blocks can be found in patients with DCM¹; conduction abnormalities, especially in young patients, suggest a specific genetic background often associated with neuromuscular diseases, laminopathy, or ion channel disorder. Conduction abnormalities are also relatively common in acquired conditions such as cardiac sarcoidosis and Chagas disease.²¹

Table 1 Main electrocardiographic features in dilated cardiomyopathy

ECG feature	No.	Males (%)	Mean LVEF (%)	Prevalence (%)
LVH ^a				17–69
Roberts et al., 1987 ³	152	72	–	39
Momiyama et al., 1994 ⁴	45	–	–	69
Merlo et al., 2019 ⁵	414	71	32	17
LA enlargement				17–51
Roberts et al., 1987 ³	152	72	–	35
Wilensky et al., 1988 ⁶	56	82	–	51
Kamiyama et al., 1997 ⁷	41	71	–	51
Merlo et al., 2019 ⁵	414	71	32	17
LBBB				23–28
Grimm et al., 2003 ⁸	343	78	31	28
Merlo et al., 2019 ⁵	414	71	32	23
Abnormal Q waves				26–36
Wilensky et al., 1988 ⁶	56	82	–	36
Merlo et al., 2019 ⁵	414	71	32	26
AF				3–25
Roberts et al., 1987 ³	152	72	–	25
Wilensky et al., 1988 ⁶	56	82	–	14
Aleksova et al., 2010 ⁹	539	73	30	10
Merlo et al., 2019 ⁵	414	71	32	3
First degree AV block				10–23
Hamby et al., 1868 ¹⁰	60	–	–	18
Roberts et al., 1987 ³	152	72	–	23
Merlo et al., 2019 ⁵	414	71	32	10
Inferior T-wave inversion				
Merlo et al., 2019 ⁵	414	71	32	14
Anterolateral T-wave inversion				
Merlo et al., 2019 ⁵	414	71	32	13
RBBB				2–6
Roberts et al., 1987 ³	152	72	–	6
Wilensky et al., 1988 ⁶	56	82	–	6
Merlo et al., 2019 ⁵	414	71	32	2
RA enlargement				3–6
Roberts et al., 1987 ³	152	72	–	6
Wilensky et al., 1988 ⁶	56	82	–	3
Merlo et al., 2019 ⁵	414	71	32	4

AF, atrial fibrillation; AV, atrio-ventricular; LA, left atrial; LBBB, left bundle branch block; LVEF, left ventricular ejection fraction; LVH, left ventricular hypertrophy; RA, right atrial; RBBB, right bundle branch block.

^aBased on Sokolow–Lyon or Cornell voltage criteria.

QRS complex

Loss of vital myocardium and diffuse LV fibrosis may both lead to reduced QRS amplitude, especially in the precordial leads.^{3,5,10} Low QRS voltages may also reflect fat infiltration, such as in arrhythmogenic cardiomyopathy due to desmosomal gene mutations, with involvement of the left as well as the right ventricle.^{21,22} When LV hypertrophy (LVH) voltage criteria (either Sokolow–Lyon or Cornell) are met in patients with DCM, a hypertensive aetiology should be excluded.^{3–5}

Left bundle branch block (LBBB) is found in roughly one third of patients with DCM,²³ sometimes preceding the structural phenotype,

and carries an adverse prognostic value; LBBB can be the result of a discrete lesion within the his bundle, as suggested by Narula²⁴ explaining why pacing at the distal His bundle can improve electrical end echocardiographic desynchronization in patients with LBBB.²⁵ Many patients with a diagnosis of LBBB have a combination of LVH and left anterior fascicular block rather than true LBBB.²⁶ True LBBB should be diagnosed if QRS duration is ≥ 140 ms (130 ms in women), there is a QS or rS pattern in V1-V2 and mid-QRS notching or slurring in ≥ 2 of leads V1, V2, V5, V6, I, aVL. After cardiac resynchronization therapy (CRT), this morphology is associated with a better echocardiographic response and survival than other intraventricular delays.²⁷

Right bundle branch block (RBBB) is generally uncommon in patients with DCM (2–6%)^{3,5,6} but it is frequently found in patients with neuromuscular disease due to pathogenic variants in the dystrophin gene.²⁸

Q waves

The lack of consensus regarding the definition of a pathological Q wave, with multiple proposed diagnostic criteria, constitutes a source of confusion. Q-wave duration ≥ 40 ms or an absolute depth of >3 mm are considered pathological criteria by some, whereas others recommend an amplitude $\geq 25\%$ of the ensuing R wave.²⁰ Q waves may be observed in DCM in the absence of ischaemic heart disease and are more common in the anterior and lateral leads.^{5,6} As discussed below, cardiac involvement in muscular dystrophies is often characterized by posterior or inferior Q waves, which reflect transmural myocardial fibrosis.²⁹

ST segment/T-wave abnormalities

Repolarization abnormalities are common in DCM, and generally reflect LV impairment. T-wave inversion (TWI), especially in the lateral leads, is a recognized feature of certain genetic forms (for example filamin C or desmosomal disease).¹³ In contrast to HCM, where striking repolarization abnormalities (such as deep TWI especially in the lateral leads) are common, TWI in DCM is less deep and not associated with voltage criteria for LVH.^{14,30}

QT interval

The QTc interval is generally normal in DCM. A short QT interval has been associated with primary carnitine deficiency which may cause DCM.³¹ QT variability at prolonged monitoring has been shown to be of potential use in sudden cardiac death (SCD) risk stratification in patients with DCM.³²

Ventricular premature beats

Ventricular premature beats (VPBs) may be found in up to 40% of patients with DCM.³³ Frequent VPBs may promote LV systolic dysfunction and in some cases it may be challenging to establish whether VPBs are the main driving force of LV systolic dysfunction (tachycardiomyopathy), an arrhythmic manifestation of an underlying cardiomyopathy, or an innocent by-stander. There is no consensus regarding the burden of VPBs considered to be sufficient to cause LV systolic dysfunction; however, a high burden has been variably defined as ranging from $>10\,000$ to $25\,000$ VPBs/day and as $>10\%$ to 24% of total heart-beats during the 24 h.¹⁹ The type and not only the burden of VPBs is relevant in the differential diagnosis between forms of DCM. Moreover, certain VPBs morphologies are commonly identified

in athletes and are considered benign. These include infundibular and fascicular morphologies. On the contrary, other morphologies of VPBs such as LBBB/intermediate or superior axis or RBBB/intermediate or superior axis and wide QRS may be a sign of underlying myocardial disease.³⁴

An 'arrhythmogenic' subset of genetic DCM, epitomized by lamin A/C and desmosomal forms of DCM, is characterized by complex and polymorphic ventricular arrhythmias (including frequent VPBs) early in the course of the disease, heralding increased risk of SCD.¹² The presence of VPBs and/or non-sustained ventricular tachycardia (NSVT) does not generally dictate the choice of protecting a patient with DCM phenotype with an implantable cardioverter-defibrillator (ICD) in primary prevention. However, the presence of frequent arrhythmias, especially if associated with pathogenic variants in desmosomal genes and/or myocardial fibrosis at CMR, may suggest a high risk of SCD and therefore an ICD should be considered in this setting.

The development of ventricular arrhythmias at the exercise tolerance test, including an increase in VBPs or development of NSVT during exercise, may be a sign of an arrhythmogenic phenotype with underlying desmosomal pathogenic variants.¹

Supraventricular arrhythmias

The identification of AF through ambulatory monitoring is an important aspect of management of DCM and may dictate important choices as commencement of anticoagulation therapy for stroke prevention.¹ The detection of paroxysmal supraventricular arrhythmias in young patients with DCM should prompt investigation for familial LMNA cardiomyopathy.¹²

In summary, from a practical standpoint, when approaching a patient with unexplained LV dilatation and/or systolic dysfunction, a systematic analysis of the ECG from the beginning of the P wave to the end of the T wave may provide invaluable clues that may point toward the diagnosis of specific subtypes with implications for management and prognosis.

The ECG in specific genetic forms of dilated cardiomyopathy

Some ECG features are clues of specific genetic DCM subtypes, as certain disease-causing genes are associated with characteristic ECG abnormalities³⁵ (Table 2 and Figure 1) that may have diagnostic as well as prognostic value for the patients and their relatives. For example, pathogenic variants in certain genes (lamin A/C, filamin C, desmosomal genes and phospholamban) may express an arrhythmogenic phenotype, which should lead to early decisions on ICD implantation in primary prevention. In the following lines, we describe ECG patterns in some of the most common DCM-associated genotypes.

Titin

Truncating variants in the gene for the sarcomeric protein titin (TTN) have been identified as the most common genetic cause of DCM and found in 10% to 20% of cases.³⁶ A typical ECG pattern of patients harbouring pathogenic variants in TTN has not been described. A recent study³⁷ on one of the largest cohorts to date, showed that patients with TTN truncating variants had a higher prevalence of AF and ventricular arrhythmias than DCM patients with other aetiologies, while the prevalence of LBBB and conduction abnormalities was lower.

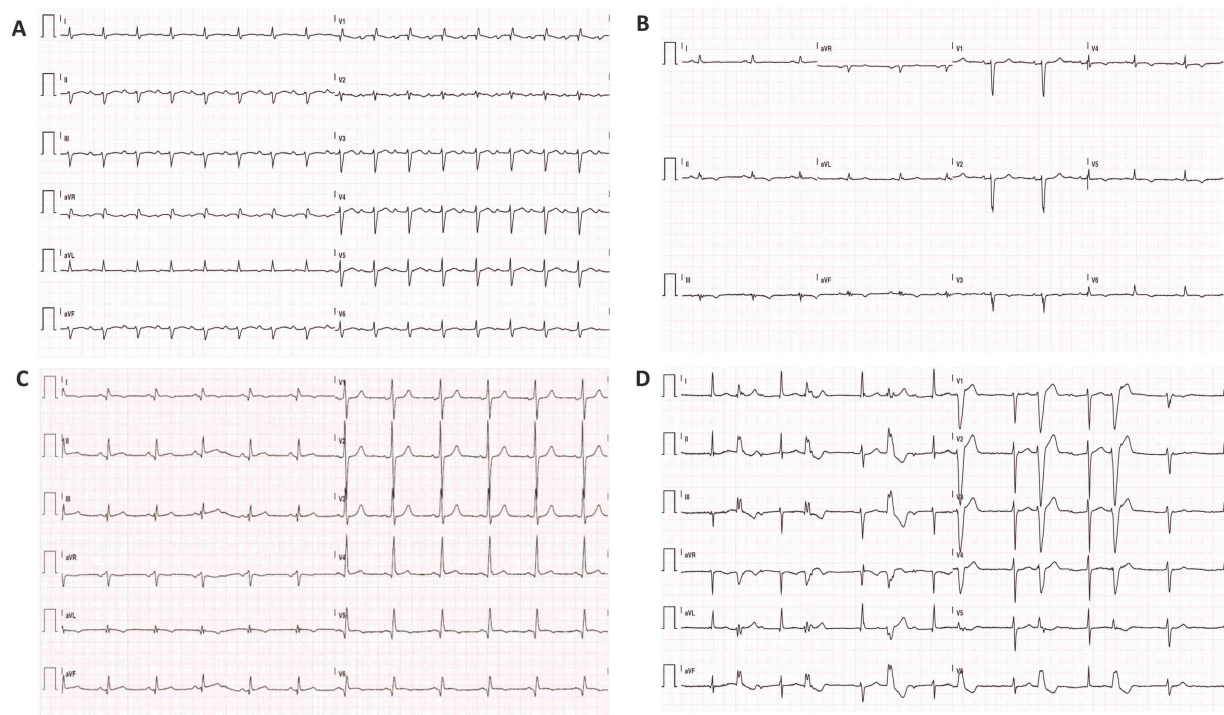


Figure 1 Electrocardiograms of dilated cardiomyopathy patients with underlying pathogenic variants. (A) First degree atrio-ventricular block and right bundle branch block with left anterior hemiblock in a carrier of an *LMNA* pathogenic variant. (B) Low voltages in the limb leads and inferolateral T-wave inversion in a carrier of an *FLNC* pathogenic variant. (C) Inferolateral pseudo-necrosis in a carrier of a *DMD* pathogenic variant. (D) First-degree atrio-ventricular block and frequent ventricular premature beats in a carrier of an *SCN5A* pathogenic variant.

Lamin A/C

Variants of the lamin A/C gene (*LMNA*) are found in up to 8% of DCM cases.³⁸ Early conduction disease, manifesting as sinus bradycardia, sinus node arrest, AV blocks (first or second degree AV block, later progressing to complete heart block) or LBBB are relatively common in this form of DCM.¹ Such findings often precede the development of an overt dilated phenotype (Figure 1A). These patients exhibit a high prevalence of supraventricular arrhythmias, in particular AF (present in almost half of the patients at their first presentation), but also atrial flutter and atrial tachycardia.³⁹ Frequent VPBs and episodes of NSVT may also be found at the ECG or at ambulatory monitoring. Risk of SCD and progression to refractory heart failure is common in this genetic subset.

Similar to the *LMNA* variants, variants in the emerin gene (*EMD* or *STA*), responsible for Emery–Dreifuss muscular dystrophy, frequently lead to conduction disturbances⁴⁰ and supraventricular arrhythmias.⁴¹

Filamin C

Filamin C is an intermediate filament that cross-links polymerized actin, contributing to anchoring cellular membrane proteins to the cytoskeleton. Filamin C gene (*FLNC*) variants account for about 4% of DCM cases.^{13,16,38} Repolarization abnormalities, especially TW1 in the precordial or inferolateral leads are a common finding in patients with *FLNC* variants.¹⁴ Approximately 25% of carriers show low voltages

in the limb leads¹⁴ (Figure 1B) and frequent VPBs and NSVT are common.¹⁴

Dystrophin

The dystrophin gene (*DMD*) is located on the short arm of the X chromosome and shows an X-linked pattern of inheritance. Cardiac involvement is present in approximately 90% of the cases of Duchenne's muscular dystrophy and 70% of Becker's muscular dystrophy.¹ The ECG in DCM due to *DMD* pathogenic variants classically mimics a posterior, inferior and/or lateral myocardial infarction, with abnormal Q waves in leads I, aVL and V6 or in leads II, III and aVF, associated with high-voltage R waves in leads V1 and V2, which is due to the progressive accumulation of a transmural scar in the posterolateral region of the left ventricle⁴² (Figure 1C). Short PR interval and sinus tachycardia are also frequent, along with right-axis deviation and RBBB.⁴³

Desmin

Desmin is a cytoskeletal protein which forms muscle-specific intermediate filaments.

Pathogenic variants in the gene encoding desmin (*DES*) cause a wide spectrum of phenotypes of different cardiomyopathies, skeletal myopathies, and mixed skeletal and cardiac myopathies. Desmin variants account for 1–2% of all cases of DCM.¹ ECG abnormalities are common in this setting (up to 60% of the cases).⁴⁴ Conduction abnormalities are frequently observed (AV blocks and RBBB), followed by supraventricular and ventricular arrhythmias.⁴⁴

Table 2 Electrocardiographic 'red flags' for genetic forms of dilated cardiomyopathy

Red flag	Gene	Reported prevalence
Sinus node disease ^{1,11}		
Sinus bradycardia or sinus node arrest	LMNA	13%
	SCN5A	–
AV block (various degree)	LMNA	45–77%
	EMD	–
	DES	–
	SCN5A	–
Conduction system disease ^{11,12}		
Short PR interval	DMD	35%
RBBB	DMD	–
	DES	–
Depolarization abnormalities ^{13–15}		
Low voltages	FLNC	36%
	DSP	–
	PLN	46%
Inferolateral Q waves	DMD	13%
Repolarization abnormalities ^{16,17}		
T-wave inversion	FLNC	62%
	DSP	–
Supraventricular arrhythmias ^{1,18}		
AF	LMNA	36–76% ^a
	EMD	–
	DES	–
	SCN5A	–
Atrial flutter	LMNA	–
	EMD	–
Atrial tachycardia	LMNA	–
	EMD	–
Sinus tachycardia	DMD	–
Ventricular arrhythmias ^{11,13,14,16,19}		
Frequent VPBs	LMNA	–
	FLNC	70%
	DES	–
	DSP	–
	SCN5A	–
NSVT	LMNA	37%
	FLNC	83%
	DES	–
	DSP	–
	SCN5A	–

AF, atrial fibrillation; AV, atrio-ventricular; DES, desmin; DMD, dystrophin; DSP, desmoplakin; EMD, emerin; FLNC, filamin C; LMNA, lamin A/C; NSVT, non-sustained ventricular tachycardia; PLN, phospholamban; RBBB, right bundle branch block; SCN5A, cardiac sodium channel type 5 α -subunit; VPB, ventricular premature beat.

^aThe number refers to the prevalence of any supraventricular arrhythmia.

Cardiac sodium channel type 5 α -subunit

Cardiac sodium channel type 5 α -subunit (SCN5A) encodes the major sodium channel expressed in the heart. Variants in SCN5A gene have been associated with primary arrhythmia syndromes, including the long QT and Brugada syndromes and missense variants have been described also in familial DCM. SCN5A variants lead to various

phenotypical expressions, including isolated conduction defects, NSVT and familial, early-onset AF, which may be associated with LV systolic dysfunction^{11,45} (Figure 1D).

Desmosomal genes

Although desmosomal variants have been historically associated with ARVC, recent studies have shown that ARVC is often characterized by LV involvement with forms that are phenotypically very similar to DCM.^{13,21} A recent study reported desmosomal genes pathogenic variants in 3.5% of patients with DCM.¹³ The ECG in patients harbouring variants in desmosomal genes may be characterized by low voltages on both limb and precordial leads, delayed ventricular depolarization and repolarization abnormalities including TWI that may extend to the lateral leads (V5–V6)⁴⁶ (Figure 2). Low voltages are due to the typical subepicardial distribution of fibrofatty replacement within the left ventricle, often circumferential, preventing electrical transmission from the inner layers. Patients with DCM harbouring desmosome gene variants often develop ventricular arrhythmias and are at risk of SCD.¹³

RNA-binding motif 20

RNA-binding motif 20 (RBM20) is an RNA-binding protein expressed highly in both atria and ventricles involved in alternative splicing process. DCM in RBM20 variants is frequently associated with early onset, severe heart failure, and arrhythmic potential.¹ Although RBM20 mouse models showed a prolonged PR and heart rate-corrected QT interval, these features are not exhibited in humans and a typical ECG pattern has not been described. A genetic diagnosis is important as a distinct propensity to sustained ventricular arrhythmias has been observed in patients harbouring RBM20 variants.⁴⁷

Phospholamban

The PLN gene encodes phospholamban, a protein responsible for inhibition of sarco-/endoplasmic reticulum Ca²⁺-ATPase (SERCA) function. Variants in the PLN gene result in increased SERCA inhibition with defective calcium reuptake, with consequent reduction in contractility and DCM phenotypic expression. In some DCM cohorts, especially in The Netherlands and in Germany (due to founder mutations), the prevalence of PLN variants is high. Typical ECG features are low QRS complex potentials and decreased R-wave amplitude, mainly in anterior-lateral precordial leads.¹⁵

In summary, the genetic background of DCM may be complex and the ECG may suggest specific genetic abnormalities. ECG 'red flags' may indeed point toward particularly aggressive genetic forms that would require specific management, such as ICD implantation in primary prevention at an early stage of the disease.

The ECG in other cardiomyopathies with dilated hypokinetic phenotype

Left ventricular or biventricular dilatation and systolic dysfunction is a common final result of various disease processes. Cardiomyopathies characterized by myocardial infiltration or by LVH at an initial stage may progress toward LV dilatation and dysfunction. Typically, cardiac amyloidosis (especially the AL form) may be characterized by significant reduction of QRS voltages, a feature that may be shared also by HCM in the so-called 'burn-out' phase. While this ECG sign reflects an infiltrative myocardial process in cardiac amyloidosis, it underlies high myocardial fibrosis burden in HCM.³⁰

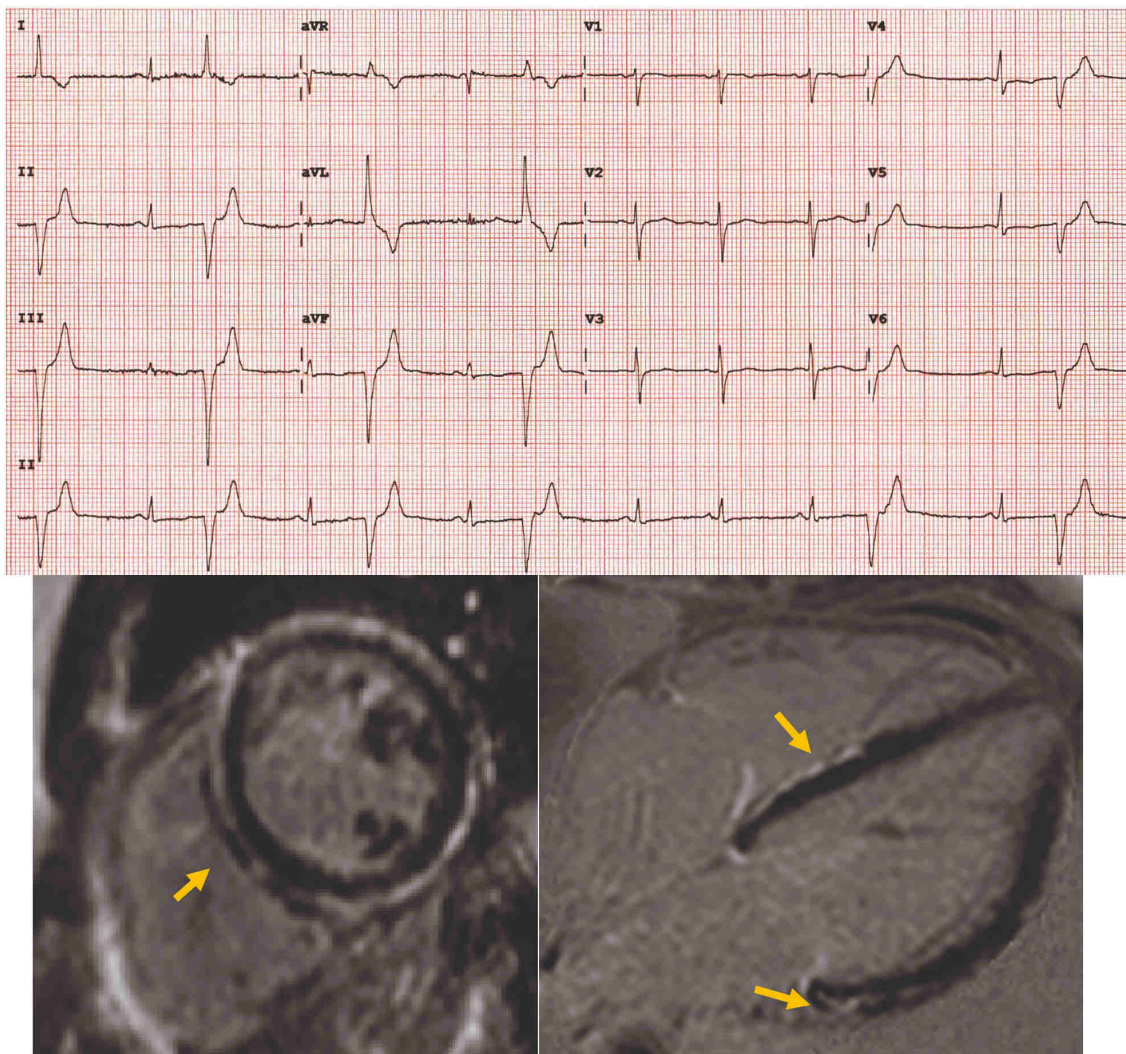


Figure 2 Electrocardiogram of a 32-year-old woman exhibiting a dilated cardiomyopathy phenotype, found to have a desmoplakin pathogenic variant. Note the low voltages on the limb and precordial leads. Cardiovascular magnetic resonance (late gadolinium enhancement sequences) shows subepicardial late gadolinium enhancement, which is more evident at the level of the right side of the interventricular septum and the basal lateral wall.

The ECG in non-genetic forms of dilated cardiomyopathy

A number of chemical compounds can induce DCM, the most common of which are chemotherapeutic agents, cocaine and alcohol. Inflammation and auto-immune response can result in particularly malignant forms of DCM.²³ Some ECG features are typical of specific acquired forms of DCM (Table 3).

Inflammatory cardiomyopathies

Acute myocarditis may result in chronic inflammation and evolution to DCM in a variable proportion of patients.⁴⁸ The spectrum of ECG features in DCM resulting from previous myocarditis is wide and often non-specific. However, especially in the acute inflammatory phase, low voltages (reflecting concomitant pericardial effusion or myocardial

fibrosis), conduction abnormalities (especially in myocarditis due to Lyme disease), lateral TWI, increased QRS duration and frequent VPBs or NSVT might be present²⁸ (Figure 3A). A specific form of inflammatory cardiomyopathy is Chagas disease, caused by the parasite *Trypanosoma cruzi* and common in South America and Central America. Chagas disease is characterized by conduction system abnormalities, most commonly RBBB with left anterior fascicular block and AV blocks.⁴⁹

A clinically manifest cardiac involvement with LV or biventricular systolic dysfunction with or without chamber enlargement occurs in approximately 5% of patients affected by systemic sarcoidosis, but a silent disease is far more common, according to autopsy studies.⁵⁰ The most common ECG manifestations are abnormalities in the conduction system, such as AV blocks, bundle branch blocks and fascicular blocks^{51,52} (Figure 3B). Unexplained advanced AV blocks in young individuals, especially if associated with LV systolic dysfunction,

Table 3 Non-genetic forms of dilated cardiomyopathy and electrocardiographic features

• Post-inflammatory DCM	- Low voltages - T-wave inversion (especially in the lateral leads) - Prolonged QRS duration - Frequent VPBs and NSVT - RBBB and LAH or high-degree AV blocks (Chagas disease)
• Cardiac sarcoidosis	- High-degree AV blocks - RBBB - Frequent VPBs and NSVT
• Tachycardia-induced DCM	- AF - Frequent VPBs
• Chemotherapy-induced DCM	- Non-specific findings (low QRS voltages and prolonged QTc correlate with disease prognosis)
• Toxic-induced DCM	- Non-specific findings (LBBB, various degree AV blocks, non-specific ST-segment alterations)

AF, atrial fibrillation; AV, atrio-ventricular; DCM, dilated cardiomyopathy; LAH, left anterior hemiblock; LBBB, left bundle branch block; NSVT, non-sustained ventricular tachycardia; RBBB, right bundle branch block; VPB, ventricular premature beat.

should raise the suspicion of cardiac sarcoidosis.⁵³ Frequent VPBs and non-sustained or sustained ventricular tachycardia are also common, and might be the first presentations of the disease.⁵⁴

Tachycardia-induced cardiomyopathy

Tachycardia-induced cardiomyopathy is defined as the reversible impairment of ventricular function with or without chamber dilatation induced by persistent arrhythmia.²³ Both atrial and ventricular arrhythmias may cause or at least promote LV or biventricular systolic dysfunction. The exclusion of underlying structural heart disease may be challenging as current imaging techniques, for example CMR, cannot easily identify diffuse fibrosis which may be a substrate for arrhythmias. In this setting, the ECG (and prolonged ECG monitoring) may provide useful insights in the diagnosis (Figure 3C). For example the demonstration of high VPBs burden or of atrial arrhythmias, especially if poorly controlled in terms of heart rate, may suggest tachycardia-induced cardiomyopathy where a timely diagnosis is important given the potential for recovery with appropriate treatment.¹⁹

Dilated cardiomyopathy caused by drugs and toxins

A series of drugs and toxins can cause DCM. Anthracyclines and several other agents used for oncologic treatment may be toxic for the heart, resulting in a clinical picture that is generally characterized by LV systolic dysfunction with or without LV dilatation, often without a specific ECG pattern. Prolonged QTc interval and decreased QRS voltages have been shown to correlate with LV systolic dysfunction in this setting⁵⁵ (Figure 3D). The burden of arrhythmia in patients with anthracycline-related cardiomyopathy is not different from patients with other forms of DCM.⁵⁶

The relationship between alcohol intake and heart failure is influenced by various genetic and environmental factors. The diagnosis of alcoholic DCM is based on a history of heavy alcohol intake

(>80–100 g/day for >10 years) in combination with otherwise unexplained cardiomyopathy.⁵⁷ Non-specific abnormalities like complete or incomplete LBBB, AV conduction disturbances, alterations in the ST segment can be found comparable to those of idiopathic DCM.⁵⁸

Cocaine and methamphetamines are sympathomimetic drugs that induce heightened inotropic and chronotropic effects. The effects on the heart are multiple, including coronary vasospasm, atherosclerosis and LV systolic dysfunction. Although in the acute setting ECG ischaemic changes are often present, specific ECG patterns are often absent in the chronic phase.

Differential diagnosis with cardiac adaptation to exercise

Long-term athletic training is associated with a series of alterations in cardiac structure, function and electrical activity and chamber dilatation is commonly observed especially in endurance athletes.⁵⁹ Significant LV dilatation in athletes may pose a challenge in the differential diagnosis with DCM. Recent international recommendations for ECG interpretation in athletes underscore which abnormalities should be considered as reflective of physiological adaptation to exercise and which instead should be regarded as highly suggestive of pathology.²⁰ While isolated voltage criteria for LVH or left-axis deviation are highly suggestive of a normal process, low voltages, LBBB, repolarization abnormalities and pathological Q waves are more likely expression of DCM. Although sinus bradycardia and first-degree AV block are normal findings in athletes, extreme bradycardia (< 30 bpm) and advanced AV blocks suggest a pathologic process and should be further investigated.

In summary, unexplained dilatation and/or systolic dysfunction is a description of a phenotype, but not a diagnosis. Although DCM may be genetic/familial in up to 25% of cases,¹ secondary causes should be excluded. In this context, a correct ECG interpretation in conjunction with a detailed personal and family history may provide useful clues for the final diagnosis. A correct identification of a possible secondary process underlying LV systolic dysfunction is relevant as, in some cases, LV systolic dysfunction may be reversible after specific treatment.

Standard ECG for risk stratification

Dilated cardiomyopathy is a dynamic condition and ECG abnormalities reflect the natural history of the disease. The presence of LBBB at baseline has been reported as an independent predictor of worse outcomes (all-cause mortality and SCD) in patients with severely impaired systolic function.⁶⁰ Moreover, a significant proportion of patients develop new-onset LBBB during follow-up, which likewise is a strong and independent predictor of all-cause mortality.⁶¹ Selection of patients who may potentially benefit from CRT is based on the severity of their LV systolic dysfunction, of their symptoms [as assessed by New York Heart Association (NYHA) class], and most importantly, ECG criteria indicative of ventricular dyssynchrony.^{2,62} In general terms, current European and American guidelines recommend CRT in symptomatic heart failure patients (NYHA class ≥II) with an ejection fraction of ≤35%,⁶³ LBBB, and a QRS duration of ≥150 ms.^{64,65} Although patients with LBBB are more likely to respond to CRT compared to patients with RBBB or non-specific interventricular conduction delay,⁶⁶ both these guidelines also state that CRT should be considered in non-LBBB with QRS ≥150 ms. American guidelines widen their indication for CRT to include patients with ischaemic cardiomyopathy and NYHA class I symptoms with an ejection fraction

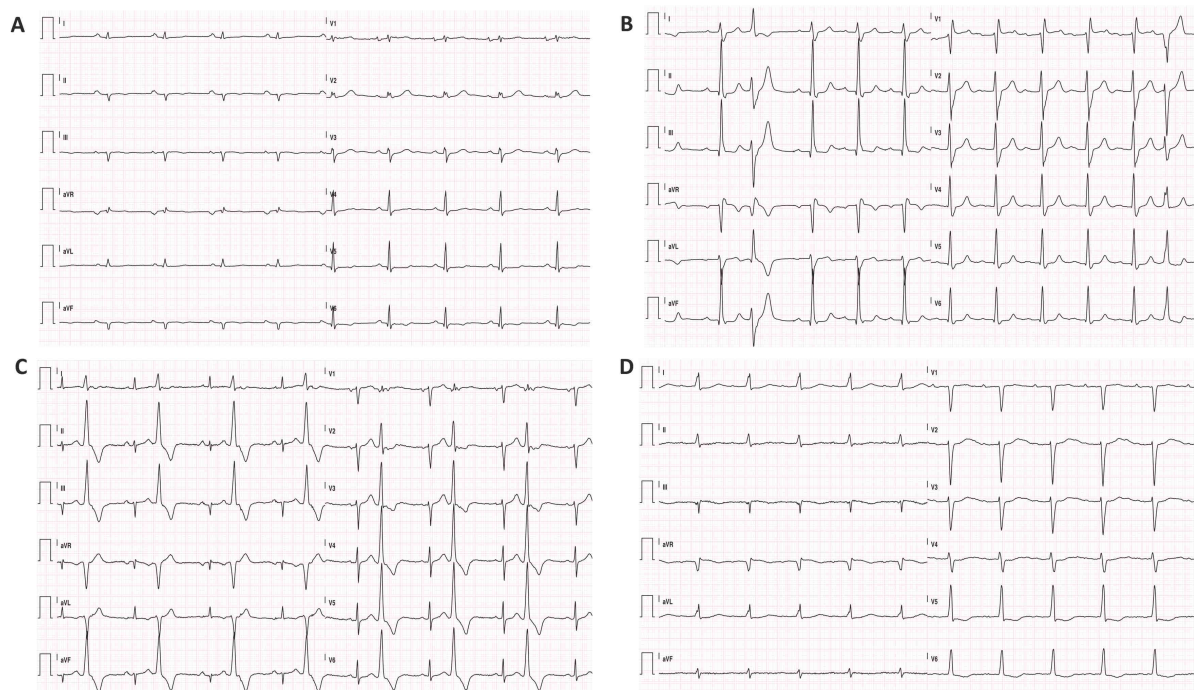


Figure 3 Non-genetic forms of dilated cardiomyopathy. (A) Diffuse low amplitude of the QRS complexes, prolonged QRS duration and lateral T-wave inversion in a patient with post-myocarditis dilated cardiomyopathy. (B) First-degree atrio-ventricular block and complete right bundle branch block in a patient with cardiac sarcoidosis and frequent premature ventricular contractions. (C) Frequent fascicular ventricular premature beats in a patient with tachycardia-induced-cardiomyopathy. (D) Non-specific electrocardiographic abnormalities, such as first-degree atrio-ventricular block and prolonged QRS duration in a patient affected by chemotherapy-induced dilated cardiomyopathy. Notably, a long QTc can be seen, which is associated with worse long-term prognosis.

of <30% and LBBB with a QRS duration of ≥ 150 ms.⁶⁵ A wider QRS has also emerged as a predictor of ventricular arrhythmias^{63,67,68} and, more interestingly, has been independently associated with early (<6 months) arrhythmic events.⁶⁹

The impact of new-onset arrhythmias is also relevant for DCM prognosis. Atrial fibrillation (both at baseline and development during follow-up) has been associated with poor long-term survival and need for heart transplantation in patients with DCM.⁹

Fragmentation of the QRS complex (i.e. the presence of notching of the QRS or an additional R wave) carries a higher risk for major ventricular arrhythmias and major adverse cardiac events.^{68,70–73} More recently, low QRS amplitude and anterolateral TWI emerged as independent predictors of major ventricular arrhythmias and SCD in patients with DCM.^{5,28} Merlo *et al.*⁵ recently showed that specific ECG features, including TWI in anterolateral leads, LVH (according to Sokolow–Lyon criteria) and higher heart rates are predictors of heart transplant and death.

Although many ECG features may underlie a propensity for potentially fatal cardiac arrhythmias, none of these are included in the recommendations for ICD implantation in primary prevention, which are still based on LV ejection fraction and NYHA class only.⁶⁴

Clinical implications

A learned ECG interpretation is extremely valuable when approaching patients with unexplained LV systolic dysfunction and/or LV dilatation. A systematic approach to ECG interpretation may reveal features

that point toward specific forms of DCM with implications in clinical management. Certain ECG ‘red flags’ may suggest to look beyond the echocardiogram and to request additional tests as CMR, Holter monitoring and exercise tolerance test, avoiding an LV ejection fraction-centred approach (Figure 4).

Gaps in evidence and future suggestions

Most studies on ECG in DCM are single-centre retrospective studies. Despite the rapid increase in the understanding of the genotype–phenotype correlations in DCM and the role of the ECG in this context, the knowledge on the modifications of the ECG during the natural history of the disease is still limited. As the definition of DCM is based mainly on structural features as LV dilatation and systolic dysfunction, clinical research has focused mainly on imaging tools such as echocardiography and more recently CMR. Future studies should include ECG data systematically in order to identify possible additional roles of the ECG in the diagnosis and risk stratification of the disease.

Conclusions

The ECG is a cornerstone in the diagnosis and management of cardiomyopathies. While traditionally the ECG was considered non-specific in DCM, a deeper understanding of the genotype–phenotype correlations and of the complex aetiological

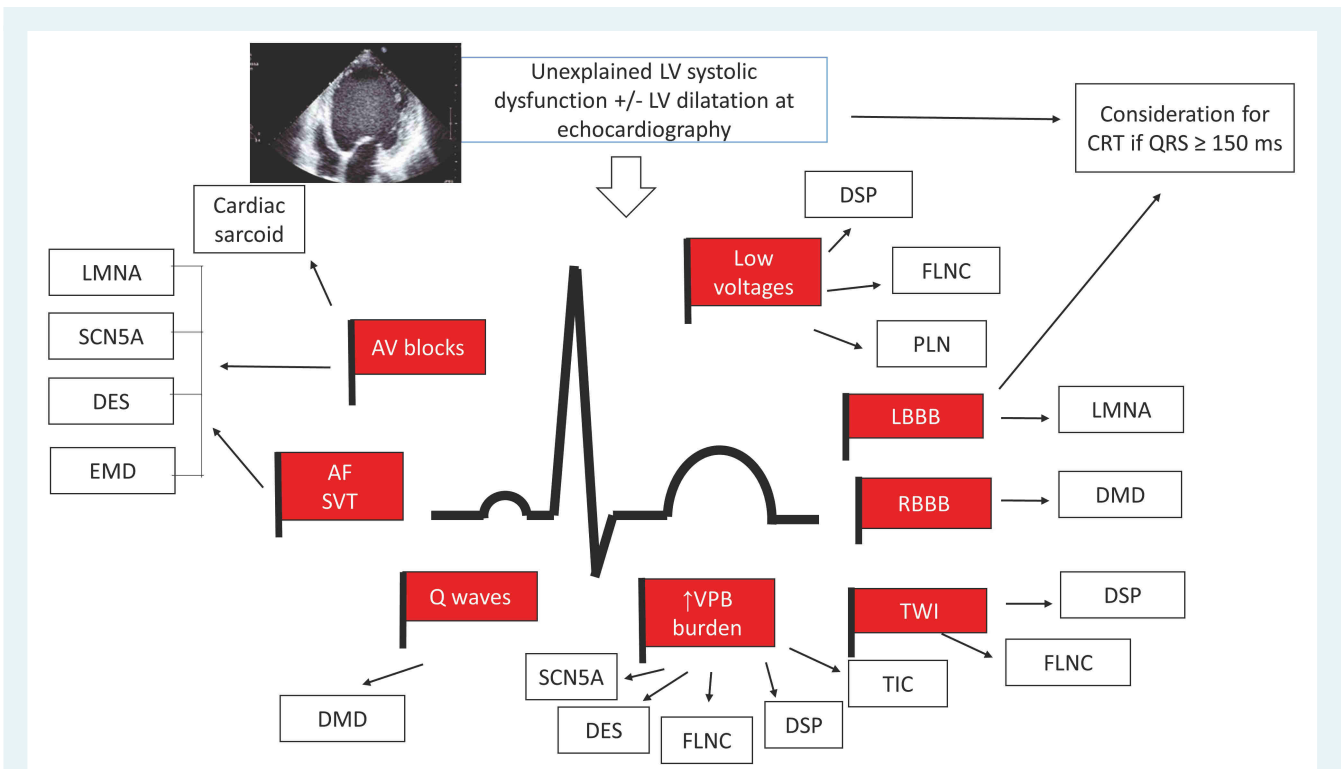


Figure 4 Red flags at the electrocardiogram in patients presenting with unexplained left ventricular (LV) systolic dysfunction. AF, atrial fibrillation; AV, atrio-ventricular; CRT, cardiac resynchronization therapy; DES, desmin; DMD, dystrophin; DSP, desmoplakin; EMD, Emery–Dreifuss; FLNC, filamin C; LBBB, left bundle branch block; LMNA, lamin A/C; PLN, phospholamban; RBBB, right bundle branch block; SCN5A, cardiac sodium channel type 5 α -subunit; SVT, supraventricular tachycardia; TIC, tachycardia-induced cardiomyopathy; TWI, T-wave inversion; VPB, ventricular premature beat.

background underlying a DCM phenotype, increasingly reveals ECG patterns and ‘red flags’ that provide the opportunity to early identify or suspect specific genetic and acquired forms. A ‘cardiomyopathy-oriented’ ECG interpretation in the setting of LV or biventricular systolic dysfunction may suggest clinical scenarios requiring a specific approach in terms of clinical management. For example the finding of just a mild LV systolic dysfunction at echocardiography in a young patient may wrongly reassure the clinician. In fact, if this feature is combined with certain ECG ‘red flags’ such as AV blocks and/or AF, a laminopathy should be excluded; if instead low voltages and TWI in the lateral leads are found, a desmosomal disease should be suspected with major implications not only for the patient but also for first-degree family members who may potentially be at risk. A learned ECG interpretation combined with a wise use of the most advanced imaging techniques and genetic testing is extremely useful in the approach to patients where clinical management is often complex, despite continuous developments in cardiovascular medicine.

Funding

I.O. was supported by the European Union’s Horizon 2020 Research and Innovation Programme under Grant Agreement no. 777204: ‘SILICOFCM - In Silico trials for drug tracing the effects of

sarcomeric protein mutations leading to familial cardiomyopathy’; by the Italian Ministry of Health [Left ventricular hypertrophy in aortic valve disease and hypertrophic cardiomyopathy: genetic basis, biophysical correlates and viral therapy models (RF-2013-02356787), and NET-2011-02347173 (Mechanisms and treatment of coronary microvascular dysfunction in patients with genetic or secondary left ventricular hypertrophy)] and by the Ente Cassa di Risparmio di Firenze (bando 2016) ‘juvenile sudden cardiac death: just know and treat’.

Conflict of interest: none declared.

References

- McNally EM, Mestroni L. Dilated cardiomyopathy: genetic determinants and mechanisms. *Circ Res* 2017;**121**:731–748.
- Seferović PM, Polovina M, Bauersachs J, Arad M, Ben Gal T, Lund LH, Felix SB, Arbustini E, Aforio AL, Farmakis D, Filippatos GS, Gialafos E, Kanjuh V, Krljanac G, Limongelli G, Linhart A, Lyon AR, Maksimović R, Miličić D, Milinković I, Noutsias M, Oto A, Oto Ö, Pavlović SU, Piepoli MF, Ristić AD, Rosano GM, Seggewiss H, Ašanin M, Seferović JP, Ruschitzka F, Čelutkienė J, Jaarsma T, Mueller C, Moura B, Hill L, Volterrani M, Lopatin Y, Metra M, Backs J, Mullens W, Chioncel O, de Boer RA, Anker S, Rapezzi C, Coats AJ, Tschöpe C. Heart failure in cardiomyopathies: a position paper from the Heart Failure Association of the European Society of Cardiology. *Eur J Heart Fail* 2019;**21**:553–576.
- Roberts WC, Siegel RJ, McManus BM. Idiopathic dilated cardiomyopathy: analysis of 152 necropsy patients. *Am J Cardiol* 1987;**60**:1340–1355.
- Momiyama Y, Mitamura H, Kimura M. ECG characteristics of dilated cardiomyopathy. *J Electrocardiol* 1994;**27**:323–328.

5. Merlo M, Zaffalon D, Stolfo D, Altinier A, Barbati G, Zecchin M, Bardari S, Sinagra G. ECG in dilated cardiomyopathy: specific findings and long-term prognostic significance. *J Cardiovasc Med (Hagerstown)* 2019;**20**:450–458.
6. Wilensky RL, Yudelman P, Cohen AI, Fletcher RD, Atkinson J, Virmani R, Roberts WC. Serial electrocardiographic changes in idiopathic dilated cardiomyopathy confirmed at necropsy. *Am J Cardiol* 1988;**62**:276–283.
7. Kamiyama N, Nezu S, Sawayama T, Kawahara Y, Samukawa M, Suetuna R, Saitou Y. Electrocardiographic features differentiating dilated cardiomyopathy from hypertrophic cardiomyopathy. *J Electrocardiol* 1997;**30**:301–306.
8. Grimm W, Christ M, Bach J, Müller HH, Maisch B. Noninvasive arrhythmia risk stratification in idiopathic dilated cardiomyopathy: results of the Marburg cardiomyopathy study. *Circulation* 2003;**108**:2883–2891.
9. Aleksova A, Merlo M, Zecchin M, Sabbadini G, Barbati G, Vitrella G, Di Lenarda A, Sinagra G. Impact of atrial fibrillation on outcome of patients with idiopathic dilated cardiomyopathy: data from the Heart Muscle Disease Registry of Trieste. *Clin Med Res* 2010;**8**:142–149.
10. Hamby RI, Raia F. Vectorcardiographic aspects of primary myocardial disease in 50 patients. *Am Heart J* 1968;**76**:304–315.
11. McNair WP, Sinagra G, Taylor MR, Di Lenarda A, Ferguson DA, Salcedo EE, Slavov D, Zhu X, Caldwell JH, Mestroni L. SCNSA mutations associate with arrhythmic dilated cardiomyopathy and commonly localize to the voltage-sensing mechanism. *J Am Coll Cardiol* 2011;**57**:2160–2168.
12. Taylor MR, Fain PR, Sinagra G, Robinson ML, Robertson AD, Carniel E, Di Lenarda A, Bohlmeier TJ, Ferguson DA, Brodsky GL, Boucek MM, Lascor J, Moss AC, Li WL, Stetler GL, Muntoni F, Bristow MR, Mestroni L; Familial Dilated Cardiomyopathy Registry Research Group. Natural history of dilated cardiomyopathy due to lamin A/C gene mutations. *J Am Coll Cardiol* 2003;**41**:771–780.
13. Gigli M, Merlo M, Graw SL, Barbati G, Rowland TJ, Slavov DB, Stolfo D, Haywood ME, Dal Ferro M, Altinier A, Ramani F, Brun F, Cocciolo A, Puggia I, Morea G, McKenna WJ, La Rosa FG, Taylor MR, Sinagra G, Mestroni L. Genetic risk of arrhythmic phenotypes in patients with dilated cardiomyopathy. *J Am Coll Cardiol* 2019;**74**:1480–1490.
14. Ortiz-Genga MF, Cuenca S, Dal Ferro M, Zorio E, Salgado-Aranda R, Clement V, Padrón-Barthe L, Duro-Aguado I, Jiménez-Jáimez J, Hidalgo-Olivares VM, García-Campo E, Lanzillo C, Suárez-Mier MP, Yonath H, Marcos-Alonso S, Ochoa JP, Santomé JL, García-Giustiniani D, Rodríguez-Garrido JL, Domínguez F, Merlo M, Palomino J, Peña ML, Trujillo JP, Martín-Vila A, Stolfo D, Molina P, Lara-Pezzi E, Calvo-Iglesias FE, Nof E, Calò L, Barriales-Villa R, Gimeno-Blanes JR, Arad M, García-Pavía P, Monserrat L. Truncating FLNC mutations are associated with high-risk dilated and arrhythmogenic cardiomyopathies. *J Am Coll Cardiol* 2016;**68**:2440–2451.
15. Haghghi K, Kolokathis F, Gramolini AO, Waggoner JR, Pater L, Lynch RA, Fan GC, Tsiapras D, Parekh RR, Dorn GW, MacLennan DH, Kremastinos DT, Kranias EG. A mutation in the human phospholamban gene, deleting arginine 14, results in lethal, hereditary cardiomyopathy. *Proc Natl Acad Sci U S A* 2006;**103**:1388–1393.
16. Begay RL, Graw SL, Sinagra G, Asimaki A, Rowland TJ, Slavov DB, Gowan K, Jones KL, Brun F, Merlo M, Miani D, Sweet M, Devaraj K, Warchow EP, Gigli M, Puggia I, Salcedo EE, Garrity DM, Ambardekar AV, Buttrick P, Reece TB, Bristow MR, Saffitz JE, Mestroni L, Taylor MR. Filamin C truncation mutations are associated with arrhythmogenic dilated cardiomyopathy and changes in the cell-cell adhesion structures. *JACC Clin Electrophysiol* 2018;**4**:504–514.
17. Elliott P, O'Mahony C, Syrris P, Evans A, Rivera Sorensen C, Sheppard MN, Carr-White G, Pantazis A, McKenna WJ. Prevalence of desmosomal protein gene mutations in patients with dilated cardiomyopathy. *Circ Cardiovasc Genet* 2010;**3**:314–322.
18. Groh WJ. Arrhythmias in the muscular dystrophies. *Heart Rhythm* 2012;**9**:1890–1895.
19. Martin CA, Lambiase PD. Pathophysiology, diagnosis and treatment of tachycardiomyopathy. *Heart* 2017;**103**:1543–1552.
20. Sharma S, Drezner JA, Baggish A, Papadakis M, Wilson MG, Prutkin JM, La Gerche A, Ackerman MJ, Borjesson M, Salerno JC, Asif IM, Owens DS, Chung EH, Emery MS, Froelicher VF, Heidbuchel H, Adamuz C, Asplund CA, Cohen G, Harmon KG, Marek JC, Molossi S, Niebauer J, Pelto HF, Perez MV, Riding NR, Saarel T, Schmiech CM, Shipon DM, Stein R, Vetter VL, Pelliccia A, Corrado D. International recommendations for electrocardiographic interpretation in athletes. *Eur Heart J* 2018;**39**:1466–1480.
21. Augusto JB, Eiros R, Nakou E, Moura-Ferreira S, Treibel TA, Captur G, Akhtar MA, Protonotarios A, Gossios TD, Savvatis K, Syrris P, Mohiddin S, Moon JC, Elliott PM, Lopes LR. Dilated cardiomyopathy and arrhythmogenic left ventricular cardiomyopathy: a comprehensive genotype-imaging phenotype study. *Eur Heart J Cardiovasc Imaging* 2020;**21**:326–336.
22. Miles C, Finocchiaro G, Papadakis M, Gray B, Westaby J, Ensam B, Basu J, Parry-Williams G, Papatheodorou E, Paterson C, Malhotra A, Robertus JL, Ware JS, Cook SA, Asimaki A, Witney A, Chis Ster I, Tome M, Sharma S, Behr ER, Sheppard MN. Sudden death and left ventricular involvement in arrhythmogenic cardiomyopathy. *Circulation* 2019;**139**:1786–1797.
23. Weintraub RG, Semsarian C, Macdonald P. Dilated cardiomyopathy. *Lancet* 2017;**390**:400–414.
24. Narula OS. Longitudinal dissociation in the His bundle. Bundle branch block due to asynchronous conduction within the His bundle in man. *Circulation* 1977;**56**:996–1006.
25. Lustgarten DL, Crespo EM, Arkhipova-Jenkins I, Lobel R, Winget J, Koehler J, Liberman E, Sheldon T. His-bundle pacing versus biventricular pacing in cardiac resynchronization therapy patients: a crossover design comparison. *Heart Rhythm* 2015;**12**:1548–1557.
26. Strauss DG, Selvester RH, Wagner GS. Defining left bundle branch block in the era of cardiac resynchronization therapy. *Am J Cardiol* 2011;**107**:927–934.
27. Mascioli G, Padeletti L, Sassone B, Zecchin M, Lucca E, Sacchi S, Boggian G, Tondo AL, Belvito C, Bakhtadze N, Borrelli A, Sinagra G. Electrocardiographic criteria of true left bundle branch block: a simple sign to predict a better clinical and instrumental response to CRT. *Pacing Clin Electrophysiol* 2012;**35**:927–934.
28. Towbin JA, McKenna WJ, Abrams DJ, Ackerman MJ, Calkins H, Darrieux FC, Daubert JP, de Chillou C, DePasquale EC, Desai MY, Estes NA, Hua W, Indik JH, Ingles J, James CA, John RM, Judge DP, Keegan R, Krahn AD, Link MS, Marcus FI, McLeod CJ, Mestroni L, Priori SG, Saffitz JE, Sanatani S, Shimizu W, Tintelen JP van, Wilde AA, Zareba W. 2019 HRS expert consensus statement on evaluation, risk stratification, and management of arrhythmogenic cardiomyopathy. *Heart Rhythm* 2019;**16**:e301–e372.
29. Rapezzi C, Arbustini E, Caforio AL, Charron P, Gimeno-Blanes J, Helio T, Linhart A, Mogensen J, Pinto Y, Ristic A, Seggewiss H, Sinagra G, Tavazzi L, Elliott PM. Diagnostic work-up in cardiomyopathies: bridging the gap between clinical phenotypes and final diagnosis. A position statement from the ESC Working Group on Myocardial and Pericardial Diseases. *Eur Heart J* 2013;**34**:1448–1458.
30. Finocchiaro G, Sheikh N, Biagini E, Papadakis M, Maurizi N, Sinagra G, Pelliccia A, Rapezzi C, Sharma S, Olivotto L. The electrocardiogram in the diagnosis and management of patients with hypertrophic cardiomyopathy. *Heart Rhythm* 2020;**17**:142–151.
31. Perin F, Rodríguez-Vázquez Del Rey MD, Carreras-Blesa C, Arrabal-Fernández L, Jiménez-Jáimez J, Tercedor L. Dilated cardiomyopathy with short QT interval suggests primary carnitine deficiency. *Rev Esp Cardiol* 2018;**71**:1074–1075.
32. Fischer C, Seeck A, Schroeder R, Goernig M, Schirdewan A, Figulla HR, Baumert M, Voss A. QT variability improves risk stratification in patients with dilated cardiomyopathy. *Physiol Meas* 2015;**36**:699–713.
33. Spezzacatene A, Sinagra G, Merlo M, Barbati G, Graw SL, Brun F, Slavov D, Di Lenarda A, Salcedo EE, Towbin JA, Saffitz JE, Marcus FI, Zareba W, Taylor MR, Mestroni L. Arrhythmogenic phenotype in dilated cardiomyopathy: natural history and predictors of life-threatening arrhythmias. *J Am Heart Assoc* 2015;**4**:e002149.
34. Corrado D, Drezner JA, D'Ascenzi F, Zorzi A. How to evaluate premature ventricular beats in the athlete: critical review and proposal of a diagnostic algorithm. *Br J Sports Med* 2019:bjsports-2018-100529 [Epub ahead of print].
35. Merlo M, Cannatà A, Gobbo M, Stolfo D, Elliott PM, Sinagra G. Evolving concepts in dilated cardiomyopathy. *Eur J Heart Fail* 2018;**20**:228–239.
36. Herman DS, Lam L, Taylor MR, Wang L, Teekakirikul P, Christodoulou D, Conner L, DePalma SR, McDonough B, Sparks E, Teodorescu DL, Cirino AL, Banner NR, Pennell DJ, Graw S, Merlo M, Di Lenarda A, Sinagra G, Bos JM, Ackerman MJ, Mitchell RN, Murry CE, Lakdawala NK, Ho CY, Barton PJ, Cook SA, Mestroni L, Seidman JG, Seidman CE. Truncations of titin causing dilated cardiomyopathy. *N Engl J Med* 2012;**366**:619–628.
37. Tayal U, Newsome S, Buchan R, Whiffin N, Halliday B, Lota A, Roberts A, Baksi AJ, Voges I, Midwinter W, Wilk A, Govind R, Walsh R, Daubeney P, Jarman JWE, Baruah R, Frenneaux M, Barton PJ, Pennell D, Ware JS, Prasad SK, Cook SA. Phenotype and clinical outcomes of titin cardiomyopathy. *J Am Coll Cardiol* 2017;**70**:2264–2274.
38. Paldino A, De Angelis G, Merlo M, Gigli M, Dal Ferro M, Severini GM, Mestroni L, Sinagra G. Genetics of dilated cardiomyopathy: clinical implications. *Curr Cardiol Rep* 2018;**20**:83.
39. Kumar S, Baldinger SH, Gandjbakhch E, Maury P, Sellal JM, Androulakis AFA, Waintraub X, Charron P, Rollin A, Richard P, Stevenson WG, Macintyre CJ, Ho CY, Thompson T, Vohra JK, Kalman JM, Zeppenfeld K, Sacher F, Tedrow UB, Lakdawala NK. Long-term arrhythmic and nonarrhythmic outcomes of lamin A/C mutation carriers. *J Am Coll Cardiol* 2016;**68**:2299–2307.
40. Rakovec P, Zidar J, Šinkovec M, Zupan I, Breclj A. Cardiac involvement in Emery-Dreifuss muscular dystrophy: role of a diagnostic pacemaker. *Pacing Clin Electrophysiol* 1995;**18**:1721–1724.
41. Sakata K, Shimizu M, Ino H, Yamaguchi M, Terai H, Fujino N, Hayashi K, Kaneda T, Inoue M, Oda Y, Fujita T, Kaku B, Kanaya H, Mabuchi H. High incidence of sudden cardiac death with conduction disturbances and atrial cardiomyopathy caused by a nonsense mutation in the STA gene. *Circulation* 2005;**111**:3352–3358.

42. Hor K, Raman S, Subramanian S, Moran T, Gnyawali T, Lao K, Benson W, Cripe L. ECG abnormalities correlate with myocardial fibrosis by cardiac magnetic resonance imaging in DMD. *Neuromuscul Disord* 2016;**26**(Suppl 2):S121 (abstr).
43. Perloff JK, Roberts WC, de AC L Jr, O'Doherty D. The distinctive electrocardiogram of Duchenne's progressive muscular dystrophy. An electrocardiographic-pathologic correlative study. *Am J Med* 1967;179–188.
44. Clemen CS, Herrmann H, Strelkov SV, Schröder R. Desminopathies: pathology and mechanisms. *Acta Neuropathol* 2013;**125**:47–75.
45. Remme CA. Cardiac sodium channelopathy associated with SCN5A mutations: electrophysiological, molecular and genetic aspects. *J Physiol* 2013;**591**:4099–4116.
46. Finocchiaro G, Papadakis M, Dhutia H, Zaidi A, Malhotra A, Fabi E, Cappelletto C, Brook J, Papatheodorou E, Ensam B, Miles CJ, Bastiaenen R, Attard V, Homfray T, Sharma R, Tome M, Carr-White G, Merlo M, Behr ER, Sinagra G, Sharma S. Electrocardiographic differentiation between 'benign T-wave inversion' and arrhythmogenic right ventricular cardiomyopathy. *Europace* 2019;**21**:332–338.
47. van den Hoogenhof MM, Beqqali A, Amin AS, van der Made I, Aufiero S, Khan MA, Schumacher CA, Jansweijer JA, van Spaendonck-Zwarts KY, Remme CA, Backs J, Verkerk AO, Baartscheer A, Pinto YM, Creemers EE. RBM20 mutations induce an arrhythmogenic dilated cardiomyopathy related to disturbed calcium handling. *Circulation* 2018;**138**:1330–1342.
48. D'Ambrosio A. The fate of acute myocarditis between spontaneous improvement and evolution to dilated cardiomyopathy: a review. *Heart* 2001;**85**:499–504.
49. Nunes MC, Beaton A, Acquatella H, Bern C, Bolger AF, Echeverría LE, Dutra WO, Gascon J, Morillo CA, Oliveira-Filho J, Ribeiro AL, Marin-Neto JA. Chagas cardiomyopathy: an update of current clinical knowledge and management: a scientific statement from the American Heart Association. *Circulation* 2018;**138**:e169–e209.
50. Birnie DH, Nery PB, Ha AC, Beanlands RS. Cardiac sarcoidosis. *J Am Coll Cardiol* 2016;**68**:411–421.
51. Mehta D, Lubitz SA, Frankel Z, Wisnivesky JP, Einstein AJ, Goldman M, Machac J, Teirstein A. Cardiac involvement in patients with sarcoidosis: diagnostic and prognostic value of outpatient testing. *Chest* 2008;**133**:1426–1435.
52. Schuller JL, Olson MD, Zipse MM, Schneider PM, Aleong RG, Wienberger HD, Varosy PD, Sauer WH. Electrocardiographic characteristics in patients with pulmonary sarcoidosis indicating cardiac involvement. *J Cardiovasc Electrophysiol* 2011;**22**:1243–1248.
53. Nery PB, Beanlands RS, Nair GM, Green M, Yang J, McArdle BA, Davis D, Ohira H, Gollob MH, Leung E, Healey JS, Birnie DH. Atrioventricular block as the initial manifestation of cardiac sarcoidosis in middle-aged adults. *J Cardiovasc Electrophysiol* 2014;**25**:875–881.
54. Birnie DH, Sauer WH, Bogun F, Cooper JM, Culver DA, Duvernoy CS, Judson MA, Kron J, Mehta D, Cosedis Nielsen J, Patel AR, Ohe T, Raatikainen P, Soejima K. HRS expert consensus statement on the diagnosis and management of arrhythmias associated with cardiac sarcoidosis. *Heart Rhythm* 2014;**11**:1305–1323.
55. Horacek JM, Jakl M, Horackova J, Pudil R, Jebavy L, Maly J. Assessment of anthracycline-induced cardiotoxicity with electrocardiography. *Exp Oncol* 2009;**31**:115–117.
56. Mazur M, Wang F, Hodge DO, Siontis BL, Beinborn DS, Villarraga HR, Lerman A, Friedman PA, Herrmann J. Burden of cardiac arrhythmias in patients with anthracycline-related cardiomyopathy. *JACC Clin Electrophysiol* 2017;**3**:139–150.
57. Ware JS, Amor-Salamanca A, Tayal U, Govind R, Serrano I, Salazar-Mendiguchia J, García-Pinilla JM, Pascual-Figal DA, Nuñez J, Guzzo-Merello G, Gonzalez-Vioque E, Bardaji A, Manito N, López-Garrido MA, Padron-Barthe L, Edwards E, Whiffin N, Walsh R, Buchan RJ, Midwinter W, Wilk A, Prasad S, Pantazis A, Baski J, O'Regan DP, Alonso-Pulpon L, Cook SA, Lara-Pezzi E, Barton PJ, Garcia-Pavia P. Genetic etiology for alcohol-induced cardiac toxicity. *J Am Coll Cardiol* 2018;**71**:2293–2302.
58. Rodrigues P, Santos-Ribeiro S, Teodoro T, Gomes FV, Leal I, Reis JP, Goff DC, Gonçalves A, Lima JA. Association between alcohol intake and cardiac remodeling. *J Am Coll Cardiol* 2018;**72**:1452–1462.
59. Pelliccia A, Culasso F, Di Paolo FM, Maron BJ. Physiologic left ventricular cavity dilatation in elite athletes. *Ann Intern Med* 1999;**130**:23–31.
60. Akhtar MM, Elliott P. Impact of left bundle branch block (LBBB) in dilated cardiomyopathy (DCM) with intermediate left ventricular systolic dysfunction (LVSD). *Int J Cardiol* 2019;**278**:199–201.
61. Aleksova A, Carriere C, Zecchin M, Barbati G, Vitrella G, Di Lenarda A, Sinagra G. New-onset left bundle branch block independently predicts long-term mortality in patients with idiopathic dilated cardiomyopathy: data from the Trieste Heart Muscle Disease Registry. *Europace* 2014;**16**:1450–1459.
62. Seferovic PM, Ponikowski P, Anker SD, Bauersachs J, Chioncel O, Cleland JG, de Boer RA, Drexel H, Ben Gal T, Hill L, Jaarsma T, Jankowska EA, Anker MS, Lainscak M, Lewis BS, McDonagh T, Metra M, Milicic D, Mullens W, Piepoli MF, Rosano G, Ruschitzka F, Volterrani M, Voors AA, Filippatos G, Coats AJ. Clinical practice update on heart failure 2019: pharmacotherapy, procedures, devices and patient management. An expert consensus meeting report of the Heart Failure Association of the European Society of Cardiology. *Eur J Heart Fail* 2019;**21**:1169–1186.
63. Stolfo D, Ceschia N, Zecchin M, Luca A De, Gobbo M, Barbati G, Gigli M, Masè M, Pinamonti B, Pivetta A, Merlo M, Sinagra G. Arrhythmic risk stratification in patients with idiopathic dilated cardiomyopathy. *Am J Cardiol* 2018;**121**:1601–1609.
64. Ponikowski P, Voors AA, Anker SD, Bueno H, Cleland JG, Coats AJ, Falk V, González-Juanatey JR, Harjola VP, Jankowska EA, Jessup M, Linde C, Nihoyannopoulos P, Parissis JT, Pieske B, Riley JP, Rosano GM, Ruilope LM, Ruschitzka F, Rutten FH, van der Meer P. 2016 ESC guidelines for the diagnosis and treatment of acute and chronic heart failure: The Task Force for the diagnosis and treatment of acute and chronic heart failure of the European Society of Cardiology (ESC). Developed with the special contribution of the Heart Failure Association (HFA) of the ESC. *Eur J Heart Fail* 2016;**18**:891–975.
65. Yancy CW, Jessup M, Bozkurt B, Butler J, Casey DE, Drazner MH, Fonarow GC, Geraci SA, Horwich T, Januzzi JL, Johnson MR, Kasper EK, Levy WC, Masoudi FA, McBride PE, McMurray JVV, Mitchell JE, Peterson PN, Riegel B, Sam F, Stevenson LW, Tang WH, Tsai EJ, Wilkoff BL. 2013 ACCF/AHA guideline for the management of heart failure: executive summary: a report of the American College of Cardiology Foundation/American Heart Association Task Force on Practice Guidelines. *Circulation* 2013;**128**:1810–1852.
66. Barsheshet A, Goldenberg I, Moss AJ, Eldar M, Huang DT, McNitt S, Klein HU, Hall WJ, Brown MW, Goldberger JJ, Goldstein RE, Schuger C, Zareba W, Daubert JP. Response to preventive cardiac resynchronization therapy in patients with ischaemic and nonischaemic cardiomyopathy in MADIT-CRT. *Eur Heart J* 2011;**32**:1622–1630.
67. Hombach V, Merkle N, Torzewski J, Kraus JM, Kunze M, Zimmermann O, Kestler HA, Wöhrle J. Electrocardiographic and cardiac magnetic resonance imaging parameters as predictors of a worse outcome in patients with idiopathic dilated cardiomyopathy. *Eur Heart J* 2009;**30**:2011–2018.
68. Goldberger JJ, Subačius H, Patel T, Cunnane R, Kadish AH. Sudden cardiac death risk stratification in patients with nonischemic dilated cardiomyopathy. *J Am Coll Cardiol* 2014;**63**:1879–1889.
69. Losurdo P, Stolfo D, Merlo M, Barbati G, Gobbo M, Gigli M, Ramani F, Pinamonti B, Zecchin M, Finocchiaro G, Mestroni L, Sinagra G. Early arrhythmic events in idiopathic dilated cardiomyopathy. *JACC Clin Electrophysiol* 2016;**2**:535–543.
70. Ahn MS, Kim JB, Joung B, Lee MH, Kim SS. Prognostic implications of fragmented QRS and its relationship with delayed contrast-enhanced cardiovascular magnetic resonance imaging in patients with non-ischemic dilated cardiomyopathy. *Int J Cardiol* 2013;**167**:1417–1422.
71. Pei J, Li N, Gao Y, Wang Z, Li X, Zhang Y, Chen J, Zhang P, Cao K, Pu J. The J wave and fragmented QRS complexes in inferior leads associated with sudden cardiac death in patients with chronic heart failure. *Europace* 2012;**14**:1180–1187.
72. Sha J, Zhang S, Tang M, Chen K, Zhao X, Wang F. Fragmented QRS is associated with all-cause mortality and ventricular arrhythmias in patient with idiopathic dilated cardiomyopathy. *Ann Noninvasive Electrocardiol* 2011;**16**:270–275.
73. Das MK, Maskoun W, Shen C, Michael MA, Suradi H, Desai M, Subbarao R, Bhakta D. Fragmented QRS on twelve-lead electrocardiogram predicts arrhythmic events in patients with ischemic and nonischemic cardiomyopathy. *Heart Rhythm* 2010;**7**:74–80.