UNIVERSITÀ DEGLI STUDI DI TRIESTE

Hematopoietic Stem Cell Transplantation in Late-onset X-linked Chronic Granulomatous Disease in a Female Carrier

This is the peer reviewed (post-print) version of the following article:

Original
Hematopoietic Stem Cell Transplantation in Late-onset X-linked Chronic Granulomatous Disease in a Female Carrier / Trevisan, M., Kang, E.m., Salton, F., Ruaro, B., Torregiani, C., Confalonieri, P., Naviglio, S., Valencic, E., Gabrielli, M., Parta, M., Kelly, C., Notarangelo, L.d., Malech, H.l., Tommasini, A., Confalonieri, M.. - In: JOURNAL OF CLINICAL IMMUNOLOGY. - ISSN 0271-9142. - STAMPA. - 42:7(2022), pp. 1396-1399. [10.1007/s10875-022-01310-9]

Availability:
This version is available at: 11368/3025164 since: 2022-11-21T11:55:10Z
Publisher:

Published
DOI:10.1007/s10875-022-01310-9
Terms of use:

Some rights reserved. More details in the PostPrint rights section below.

License:
Digital Rights Management not defined

Publisher copyright

-.-

(Article begins on next page)

19 October 2026

arTs Università degli Studi di Trieste
Archivio della ricerca – postprint

Hematopoietic Stem Cell Transplantation in Late-onset X-linked Chronic Granulomatous Disease in a Female Carrier

Matteo Trevisan[1] · Elizabeth M. Kang[4] · CGD Consortium · Alberto Tommasini[1,5] · Marco Confalonieri[1,6]

Accepted: 21 June 2022

Abbreviations

AUC	Area Under the Curve
CGD	Chronic Granulomatous Disease
DHR	Dihydrorhodamine assay
GVHD	Graft Versus Host Disease
HSCT	Hematopoietic Stem Cell Transplantation
IFNγ	Interferon-gamma
NADPH	Nicotinamide Adenine Dinucleotide Phosphate
NIH	National Institutes of Health
PBSC	Peripheral Blood Stem Cells
PMA	Phorbol 12-Myristate 13-Acetate

To the Editors:

Chronic granulomatous disease (CGD) is a rare immunodeficiency disorder characterized by a defective NADPH oxidase complex leading to an impaired respiratory burst and defective killing of pathogens by phagocytes. The most common type of CGD is caused by hemizygous mutations of the *CYBB* gene on the X chromosome encoding the gp91^{phox} subunit. It usually affects males, yet heterozygous females may rarely manifest clinical signs of the disease due to skewed X chromosome inactivation in leukocytes [1]. Despite advances in gene therapy, hematopoietic stem cell transplantation (HSCT) remains the main definitive treatment. Older patients, however, are at greater risk of HSCT-related complications and mortality and may require a specific approach.

A 49-year-old woman was admitted to the Pneumonology Unit because of bilateral pneumonia. Her medical history was characterized by discoid lupus and Raynaud's phenomenon, which had appeared 3 years before. She had no history of frequent, severe, or unusual infections. After unsuccessful treatment with broad-spectrum antibiotics, analysis of bronchoalveolar lavage fluid demonstrated multi-sensitive *Nocardia asteroides* infection. Despite targeted antibiotics (imipenem and co-trimoxazole), she developed acute respiratory distress syndrome and bilateral pneumothorax, requiring intensive care unit admission and extracorporeal membrane oxygenation. Blood tests showed normal immunoglobulins and lymphocytes subpopulations, yet a dihydrorhodamine-123 (DHR123) assay showed superoxide anion production only in 6.7% of neutrophils (Fig. 1A); furthermore, the mean fluorescence intensity (MFI) in positive cells was lower than expected, suggesting a reduced superoxide anion production. Genetic analysis revealed a heterozygous mutation on the *CYBB* gene (c.[1661_1662insT]:[=],p.[Glu555*]), a nonsense mutation already classified as pathogenic in the ClinVar database. The finding of an unbalanced X-chromosome inactivation pattern in leukocytes (97.8:2.2), together with DHR123 test results, was coherent with the hypothesis of inactivation of the wild-type *CYBB* gene in almost all cells, thus confirming a functional diagnosis of X-linked CGD. After 1 week of maximized antimicrobial and steroidal therapy, her condition did not improve, therefore subcutaneous interferon-γ (IFNγ) was started (120 μg/m^2 3 times a week). Notably, this treatment did not influence the overall percentage of functional neutrophils at the

Trevisan M. and Kang E.M. contributed equally as co-first authors.

Tommasini A. and Confalonieri M. contributed equally as co-last authors.

✉ Matteo Trevisan
matteo.trevisan91@gmail.com

1 Department of Medicine, Surgery, and Health Sciences, University of Trieste, Trieste, Italy

2 Laboratory of Clinical Immunology and Microbiology, National Institute of Allergy and Infectious Diseases, National Institutes of Health, Bethesda, MD, USA

3 Pulmonology Department, University Hospital of Trieste, Trieste, Italy

4 Institute for Maternal and Child Health IRCCS "Burlo Garofolo", Trieste, Italy

5 Cardiovascular Department, Cardiac Surgery Unit, Ospedali Riuniti di Trieste, Trieste, Italy

6 Clinical Research Directorate, Frederick National Laboratory for Cancer Research, Bethesda, MD, USA

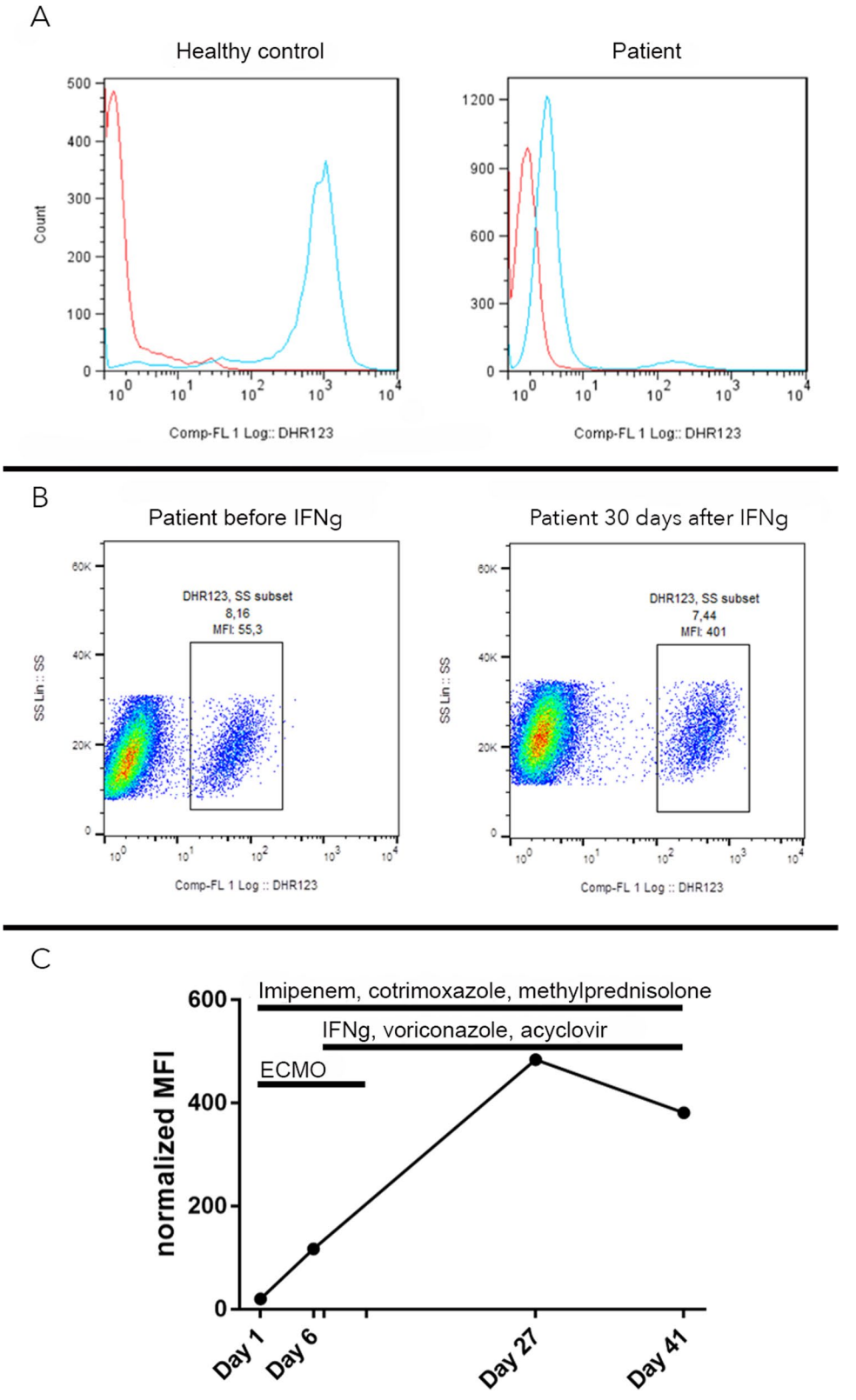

Fig. 1 **A** Dihydrorhodamine assay (DHR). Histogram graphs in Panel A show a low superoxidase production by the patient's neutrophils rather than control after PMA treatment (blue line); red line represents the untreated samples. **B** Fluorescence intensity (MFI) in dihydrorhodamine assay (DHR123) showing an increase in functional neutrophils after IFNγ administration without a rise in the percentage of DHR+ cells. **C** Change in MFI values in four-time points DHR assay and drugs administered. Normalized MFI = MFI of PMA-treated samples - MFI of untreated samples

DHR123 assay; however, positive cells showed a normalization of the MFI (Fig. 1B and 1C). A significant improvement of pneumonia was observed in the following days, allowing progressive reduction of respiratory support and ultimately discharge. Subcutaneous IFNγ was continued also thereafter, in association with antimicrobial prophylaxis. In

the following months, the patient developed granulomatous colitis and recurrent lung infections (due to *Nocardia asteroides*, *Klebsiella pneumoniae*, and *Pseudomonas aeruginosa*), ultimately requiring partial right lung resection. HSCT was therefore recommended, due to her overall worsening condition and recurrent infections. At the age of 51 years, she was transferred to the National Institutes of Health (NIH) in Bethesda, Maryland, USA, where she received a matched (10/10) HSCT graft of PBSC (10 million CD34 per kg) from her healthy brother after non-myeloablative conditioning with intravenous busulfan (3.2 mg/kg; AUC 30–40 mg/L*h) and alemtuzumab. Post-transplant cyclophosphamide on days 3 and 4 and then sirolimus for 6 months were given for graft-versus-host disease (GVHD) prophylaxis. Neutrophil engraftment (>500/μL) occurred on day +23, and 99% of the early-appearing circulating neutrophils were functionally normal at the DHR123 assay. After transplantation, she developed grade I acute cutaneous GVHD, treated with topical steroids, and a self-limited asymptomatic reactivation of Cytomegalovirus and Epstein-Barr virus. Ten months after transplantation, blood chimerism dropped to 60% of donor neutrophils and remained stable thereafter. No severe infections nor discoid lupus flares occurred after HSCT. At the last follow-up visit, 3.5 years after HSCT, the patient maintained overall good health, with no infectious or inflammatory manifestations or HSCT complications.

This case highlights several peculiar aspects of the approach to late-onset X-linked CGD in female patients. First, it confirms the paradigm that even a single severe/unusual infection in a previously healthy adult should raise the suspicion of primary immunodeficiency, even in presence of normal blood cell counts, serum immunoglobulins, and lymphocyte subsets, and without a significant previous history of infections. It is already known that female carriers who develop clinical CGD often present later in life due to a progressive skewing of X chromosome inactivation with age, which may result from the presence of deleterious damages on the other X chromosome. The risk of infection increases when DHR^+ cells decrease under 20% [1]. Moreover, independently of $\%DHR^+$ cells, they can also present with autoimmune and inflammatory manifestations, including skin conditions (especially discoid lupus, as in our patient) and inflammatory bowel disease. Overall, these patients are usually managed with anti-inflammatory drugs and only a minority develop severe infections requiring antimicrobial prophylaxis. HSCT has been reported only in a few cases.

Current treatment of CGD is based on the prevention of severe infections, prompt and intensive anti-infectious therapy, and proper treatment of granulomas and inflammatory complications. The role of IFNγ is still debated. IFNγ has been shown to enhance phagocyte activity in cells from healthy subjects and from CGD patients [2], yet its benefit in clinical practice is still not clearly defined; furthermore, treatment is associated with high cost and limited availability. In our patient, a clinical improvement at the time of the first infection was noted soon after the introduction of IFNγ, together with an increased MFI at the DHR123 assay. Notably, our patient had a lower-than-expected baseline MFI in residual normal neutrophils, possibly due to immune paralysis in sepsis. Nevertheless, it is not possible to demonstrate that IFNγ therapy was actually related to clinical improvement, and long-term treatment with IFNγ did not prevent subsequent bacterial infections. No serious adverse events were observed.

HSCT remains the main definitive treatment for X-linked CGD, yet older patients are at greater risk of transplant-related complications and mortality [3]. Gene therapy is promising but still under development, and its availability is limited. Due to the presence of several risk factors in our patient (age, active infectious and inflammatory complications), a non-myeloablative conditioning regimen followed by a high-dose PBSC graft was used from matched brother. Reduced-intensity regimens with low-dose busulfan (AUC 45-65 mg/L*h) or treosulfan have been shown to be associated with a higher overall and event-free survival compared to myeloablative regimens, yet graft failure and chronic GVHD are major complications [3]. Although non-myeloablative conditioning can lead to mixed chimerism, in primary immunodeficiencies this is usually sufficient to overcome the immune defect. The NIH regimen for matched related donors incorporates low dose busulfan (30–40 mg/L*h) and alemtuzumab (1 mg/kg), or even lower dose busulfan (median AUC of 20–30 mg/L*h) combined with low dose total body irradiation and alemtuzumab for matched unrelated donors, followed by sirolimus as single-agent GvHD prophylaxis [4]. This patient, enrolled on a new protocol, also received post-transplant cyclophosphamide along with a high dose of unmanipulated PBSC (10 million CD34 per kg) to ensure better engraftment and prevent GVHD. Indeed, high-dose cyclophosphamide on days 3–4 after transplantation has been shown to be effective in preventing GVHD in patients receiving PBSC transplant from HLA-matched donors, mainly through the reduction of alloreactive effector T cell proliferation and expansion of T regulatory cells. Notably, the same regimen did not prove effective in patients with CGD receiving haploidentical HSCT [5]. Overall, stable donor chimerism with minimal morbidity was observed in our patient, with only mild GVHD. This suggests that matched HSCT with non-myeloablative conditioning with low dose busulfan and alemtuzumab, combined with an increased stem cell dose and post-transplant cyclophosphamide, may represent a curative option even in high-risk CGD patients at an advanced age.

CGD consortium members Francesco Salton[6], Barbara Ruaro[6], Chiara Torregiani[6], Paola Confalonieri[6], Samuele Naviglio[5], Erica Valencic[5], Marco Gabrielli[2], Mark Parta[3], Corin Kelly[4], Luigi D. Notarangelo[4], Harry L. Malech[4]

Author Contribution All authors contributed to the study conception and design. The first draft of the manuscript was written by MT and EMK. FS, BR, CT, MG, PC, CK, MP, EMK, AT, HLM, and MC cared for the patient. Material preparation, clinical data collection, and analysis were performed by EV, SN, MP, and AT. LDN, AT, HLM and MC reviewed and improved the final draft. All authors read and approved the final manuscript.

Funding This project has been funded in whole or in part with federal funds from the National Cancer Institute, National Institutes of Health, under Contract No. HHSN261200800001E and Contract No. 75N910D00024, Task Order No. 75N91019F00131. The content of this publication does not necessarily reflect the views or policies of the Department of Health and Human Services, nor does mention of trade names, commercial products, or organizations imply endorsement by the U.S. Government.

Data Availability Not applicable.

Code Availability Not applicable.

Declarations

Consent to Participate The patient gave informed consent to participate in this research.

Consent for Publication The patient's consent to publish was obtained. A signed informed consent was obtained from the patient to publish her data in this journal article. This form is available for review upon request.

Conflict of Interest The authors declare no competing interests.

References

1. Marciano BE, Zerbe CS, Falcone EL, et al. X-linked carriers of chronic granulomatous disease: illness, lyonization, and stability. J Allergy Clin Immunol. 2018;141(1):365–71.
2. Ezekowitz RAB, Orkin SH, Newburger PE. Recombinant interferon gamma augments phagocyte superoxide production and X-chronic granulomatous disease gene expression in X-linked variant chronic granulomatous disease. J Clin Invest. 1987;80(4):1009–16.
3. Güngör T, Teira P, Slatter M, et al. Reduced-intensity conditioning and HLA-matched haemopoietic stem-cell transplantation in patients with chronic granulomatous disease: a prospective multicentre study. Lancet. 2014;383(9915):436–48.
4. Parta M, Kelly C, Kwatemaa N, et al. Allogeneic reduced intensity hematopoietic stem cell transplantation for chronic granulomatous disease: a single-center prospective Trial. J Clin Immun. 2017;37:548–58.
5. Parta M, Hilligoss D, Kelly C, et al. Failure to prevent severe graft-versus-host disease in haploidentical hematopoietic cell transplantation with post-transplant cyclophosphamide in chronic granulomatous disease. J Clin Immunol. 2020;40(4):619–24.

Publisher's Note Springer Nature remains neutral with regard to jurisdictional claims in published maps and institutional affiliations.