



## Diagnosis and Management of Rare Cardiomyopathies in Adult and Paediatric Patients. A Position Paper of the Italian Society of Cardiology (SIC) and Italian Society of Paediatric Cardiology (SICP)

Giuseppe Limongelli<sup>a,b,\*</sup>, Rachele Adorisio<sup>c</sup>, Chiara Baggio<sup>d</sup>, Barbara Baucè<sup>b,e</sup>, Elena Biagini<sup>b,f</sup>, Silvia Castelletti<sup>g</sup>, Silvia Favilli<sup>h</sup>, Massimo Imazio<sup>i</sup>, Michele Lioncino<sup>a</sup>, Marco Merlo<sup>b,d</sup>, Emanuele Monda<sup>a</sup>, Iacopo Olivetto<sup>j</sup>, Vanda Parisi<sup>f</sup>, Francesco Pelliccia<sup>k</sup>, Cristina Basso<sup>b,l</sup>, Gianfranco Sinagra<sup>b,d</sup>, Ciro Indolfi<sup>m</sup>, Camillo Autore<sup>n</sup>, on behalf of WG on Cardiomyopathies of SIC (Società Italiana di Cardiologia), on behalf of WG on Cardiomyopathies of SICPed (Società Italiana di Cardiologia Pediatrica)

<sup>a</sup> Inherited and Rare Cardiovascular Disease Unit, University of Campania “Luigi Vanvitelli”, AORN dei Colli, Monaldi Hospital, Naples, Italy

<sup>b</sup> Member of ERN GUARD-HEART (European Reference Network for Rare and Complex Diseases of the Heart; <http://guardheart.ern-net.eu>)

<sup>c</sup> Heart Failure, Transplant and Mechanical Circulatory Support Unit, Department of Pediatric Cardiology and Cardiac Surgery, Heart Lung Transplantation, Bambino Gesù Hospital and Research Institute, Rome, Italy.

<sup>d</sup> Cardiothoracovascular and Medical Surgical and Health Science Department, Azienda Sanitaria Universitaria Giuliano Isontina (ASUGI), University of Trieste, 34149 Trieste, Italy

<sup>e</sup> Department of Cardio-Thoraco-Vascular Sciences and Public Health, University of Padua, Padua, Italy

<sup>f</sup> Cardiology Unit, St. Orsola Hospital, IRCCS Azienda Ospedaliero-Universitaria di Bologna, 40138 Bologna, Italy

<sup>g</sup> Cardiomyopathy Unit and Center for Cardiac Arrhythmias of Genetic Origin, Department of Cardiovascular, Neural and Metabolic Science, Istituto Auxologico Italiano IRCCS, Milan, Italy

<sup>h</sup> Department of Pediatric Cardiology, Meyer Children's Hospital, Viale Gaetano Pieraccini, 24, 50139 Florence, Italy

<sup>i</sup> Head of Cardiology, Cardiothoracic Department, University Hospital “Santa Maria della Misericordia”, ASUFC, Piazzale Santa Maria della Misericordia 15, Udine 33100, Italy

<sup>j</sup> Cardiomyopathy Unit, Azienda Ospedaliera Universitaria Careggi and the University of Florence, Florence, Italy

<sup>k</sup> Department of Cardiovascular Sciences, Sapienza University, Rome, Italy

<sup>l</sup> Cardiovascular Pathology Unit, Department of Cardiac, Thoracic, Vascular Sciences and Public Health Azienda Ospedaliera, University of Padua Padova, Italy

<sup>m</sup> Department of Medical and Surgical Sciences, Magna Grecia University, Catanzaro, Italy

<sup>n</sup> Department of Clinical and Molecular Medicine, Sapienza University of Rome, Division of Cardiology, Sant'Andrea Hospital, Via di Grottarossa 1035-1039, 00189 Rome, Italy

### ARTICLE INFO

#### Keywords:

Cardiomyopathy  
Rare cardiovascular disease  
Diagnosis  
Management

### ABSTRACT

Cardiomyopathies (CMPs) are myocardial diseases in which the heart muscle is structurally and functionally abnormal in the absence of coronary artery disease, hypertension, valvular disease and congenital heart disease sufficient to cause the observed myocardial abnormality. Thought for a long time to be rare diseases, it is now clear that most of the CMPs can be easily observed in clinical practice. However, there is a group of specific heart muscle diseases that are rare in nature whose clinical/echocardiographic phenotypes resemble those of the four classical morphological subgroups of hypertrophic, dilated, restrictive, arrhythmogenic CMPs.

These rare CMPs, often but not solely diagnosed in infants and paediatric patients, should be more properly labelled as specific CMPs. Emerging consensus exists that these conditions require tailored investigation and management. Indeed, an appropriate understanding of these conditions is mandatory for early treatment and counselling. At present, however, the multisystemic and heterogeneous presentation of these entities is a challenge for clinicians, and time delay in diagnosis is a significant concern. The aim of this paper is to define practical recommendations for diagnosis and management of the rare CMPs in paediatric or adult age. A

\* Corresponding author at: Inherited and Rare Cardiovascular Disease Clinic, Department of Translational Medical Sciences, University of Campania “Luigi Vanvitelli”, Via L. Bianchi 1 c/o Monaldi Hospital, AORN Colli, Italy.

E-mail address: [limongelligiuseppe@libero.it](mailto:limongelligiuseppe@libero.it) (G. Limongelli).

<https://doi.org/10.1016/j.ijcard.2022.03.050>

Received 14 February 2022; Received in revised form 21 March 2022; Accepted 24 March 2022

Available online 30 March 2022

0167-5273/© 2022 The Author(s). Published by Elsevier B.V. This is an open access article under the CC BY-NC-ND license (<http://creativecommons.org/licenses/by-nc-nd/4.0/>).

modified Delphi method was adopted to grade the recommendations proposed by each member of the writing committee.

## 1. Introduction

Cardiomyopathies (CMPs) are myocardial disorders in which the heart muscle is structurally and functionally abnormal in the absence of a disease sufficient to cause the observed myocardial abnormality [1].

According to the more recent classifications, i.e. the 2008 European Society of Cardiology (ESC) position statement on classification of CMPs and the 2013 MOGE(S) classification proposed by World Heart Federation, CMPs are defined as “heart muscle disease sufficient to cause structural and functional myocardial abnormality in the absence of coronary artery disease, hypertension, valvular disease, and congenital heart disease that are not sufficient to cause the phenotype” [1,2].

Thought for a long time to be rare diseases, it is now clear that most of the CMPs can be easily seen in clinical practice. However, there is a group of specific heart muscle diseases which are rare in nature (i.e., affecting fewer than 1 in 2,000 people within the general population) whose clinical/echocardiographic phenotypes resemble those of the four classical morphological subgroups of hypertrophic, dilated, restrictive, arrhythmogenic CMPs.

These rare heart muscle diseases, often but not solely diagnosed in infants and paediatric patients, should be more properly labelled as specific CMPs. Alternative terms used (but not universally acknowledged) are phenocopies, genocopies, or CMP mimics. Emerging consensus exists that these conditions require tailored investigation and management [3]. Indeed, an appropriate understanding of these conditions is mandatory for early treatment and counselling. At present, however, multisystemic and heterogeneous presentation of these entities is a challenge for clinicians, and time delay in diagnosis is a significant concern.

### 1.1. Aim of the paper

This paper aims to define practical recommendations for diagnosis and management of the rare CMPs in paediatric or adult age.

## 2. Methods

As in previous consensus documents [4], we ranked our recommendations using coloured symbols (circles). This categorization must not be considered equivalent to that used for official ESC or other guidelines/international board documents, which apply a classification (Class I–III) and level of evidence (A, B and C) to recommendations. A green circle indicates a “need to do this” recommendation, meaning a wide degree of consensus on the efficacy and benefits of the indicated treatment/procedure, based on at least one randomized trial or strong observational studies. A yellow circle indicates general agreement or scientific evidence favouring a “should or may do this” statement or the usefulness/efficacy of a treatment or procedure. Treatment strategies for which there is scientific evidence of no benefit or potential harm and should not be used (“do not do this”) are indicated by a red circle. A modified Delphi method was adopted to grade the recommendations proposed by each member of the writing committee. “Consensus” was obtained on a recommendation if  $\geq 70\%$  of the responses fell within the same answer. “Disagreement” occurred if 35% or more of responses fell in both two extreme ranges of possible options. All other combinations of panel answers were considered “Partial Agreement”. Only recommendations for whom “Consensus” was obtained were included in the document.

### 2.1. The inherited and rare cardiomyopathy team

As for other fields of Cardiology, the concept of a dedicated, multidisciplinary team is emerging as the best strategy to provide state-of-the-art, tailored treatment to patients with cardiomyopathies. A multidisciplinary team with specific expertise in inherited and rare CMPs (Graphical Abstract) has the potential to improve diagnostic work-up, standardize and evolve clinical practice, as well as fully exploit the variety of available treatment options [5]. The variety of aetiologies, clinical presentations, and decision-making hubs, characterizing heart muscle disease, determines a degree of complexity that overcomes individual expertise, even in best case scenarios. This is particularly evident in the paediatric setting, especially in neonates and infants, because of the high prevalence of non-sarcomeric forms and in adult metabolic/storage or inflammatory diseases, where multi-organ involvement requires the most diverse expertise [6]. But even with conditions confined to the heart, such as the most common form of genetic or acquired cardiomyopathies, the range of expertise required involves adult and paediatric cardiologists, genetic counsellors, electrophysiologists, geneticists, psychologists, intensive care specialists, cardiac surgeons and electrophysiologists, as well as dedicated nursing personnel. The interpretation and disclosure of genetic test results can be particularly challenging unless addressed by adequate teamwork [7]. In addition, well-defined management trajectories need to be in place for special needs, including pregnancy, individualized sport practice in low-risk patients [8] and transplant referral.

Comprehensive testing under multidisciplinary expert guidance plays a crucial role in identifying an underlying myopathic process in patients of aborted sudden cardiac arrest (SCA) and/or electrical storm [9].

















Patients with CMPs and severe left ventricular hemodynamic derangement require a multi-faceted approach for acute hemodynamic stabilization and subsequent decision making [10], allowing the appropriate choice from an armamentarium including the trans-venous versus subcutaneous implantable cardioverter defibrillator (ICD), catheter ablation of atrial and ventricular arrhythmias, autonomic modulation with thoracic epidural anaesthesia, stellate ganglion block, or cardiac sympathetic denervation. Surgical versus catheter-based approach to specific scenarios typical of CMPs should also be discussed in a multidisciplinary environment. As a case in point, the Inherited and Rare Cardiomyopathy Team is required to critically appraise the need for a septal reduction intervention in case of hypertrophic cardiomyopathy (HCM) in order to weigh the benefit-risk ratio with either alcohol septal ablation or surgical myectomy [11]. This team should be ideally composed by at least one clinical cardiologist, an interventional cardiologist and a cardiac surgeon with recognized experience in the disease. Also, the Inherited and Rare Cardiomyopathy Team should promote the transfer of care from paediatric, child-oriented to adult care (“transition”), similarly to what is recommended for congenital heart diseases.

Recently, lifestyle counselling and quality of life issues have become increasingly important in chronic cardiac conditions such as most CMP. The updated ESC guidelines on sport prescription in patients with cardiovascular disease and the recent American Heart Association/American College of Cardiology (AHA/ACC) HCM guidelines [12] have liberalized restrictions on exercise and sport participation for individuals with HCM. This remains an extremely delicate issue, however, in which a final decision should be taken jointly by a multidisciplinary expert team involving open discussion with patients and their families [13].

Finally, the concept of patient empowerment has come to the fore in


the last decade. In a field of cardiology largely comprising rare or relatively rare conditions, with subsequent, large areas of uncertainty and data –free zones, informing patients and their families, and involving them directly in major decisions regarding their lives becomes mandatory. This approach, however, is neither easy nor well standardized and requires adequate, accessible and reliable information, a profound understanding of individual needs and expectations, as well as specific training. Research in the field, including the assessment of shared decision-making on the outcome, is still behind.

General recommendations on the diagnosis and management of rare CMPs are listed below.

Recommendations for the diagnosis of genetic and rare CMPs	Symbol
A comprehensive evaluation by a specialist team with expertise in inherited and rare cardiomyopathies is recommended.	
A complete cardiovascular assessment, including a comprehensive family history, a three-generation pedigree, physical examination, 12-lead ECG, transthoracic echocardiogram and 24 h Holter monitoring is recommended, at diagnosis and with regular, personalized, intervals in adults and children with new-onset cardiomyopathy	
CMR is recommended in children and adults with genetic CMPs: <ul style="list-style-type: none"> <li>a) when echocardiography is inconclusive;</li> <li>b) when the definition of anatomic structures, ventricular function, and tissue characterization is crucial to diagnosis and management;</li> <li>c) to assess concomitant congenital heart diseases;</li> <li>d) for sudden cardiac death stratification.</li> </ul>	
CMR with general anaesthesia should be considered in children and adults who are unable to undergo CMR without general anaesthesia.	
Risk stratification for SCD, surgical myectomy or heart transplantation decision needs to be assessed by a multidisciplinary heart team, according to phenotype, aetiology, individual clinical presentation and patient (or parents') preferences.	
EMB may be considered in patients with heart involvement and inconclusive clinical, biochemical and genetic testing.	
Genetic test, comprehensive of NGS panel testing, is recommended in patients with a CMP.	
High-resolution chromosome microarray or exome sequencing may be considered if gene testing is negative or inconclusive.	
High-resolution chromosome microarray should be considered as first-line genetic investigation when specific genetic syndromes are suspected.	
Exome sequencing may be considered in critically ill infants treated in intensive care unit who are unlikely to survive longer than a few months but where a definitive genetic diagnosis may have implication for specific treatment.	
Parental testing and co-segregation studies are recommended if a variant of unknown significance is identified in the proband.	
A comprehensive clinical evaluation and cascade genetic screening is recommended in first-degree relatives of patients carrying a pathogenic or likely pathogenic variant for genetic CMP.	
Diagnosis of rare cardiomyopathy must not be excluded solely based on a negative genetic test.	
Genetic counselling is recommended in patients with genetic cardiomyopathies.	
A comprehensive cardiological screening (ECG and echocardiography) is recommended at the time of CMP diagnosis in first-degree relatives of the proband.	
Cardiovascular biomarkers (i.e., NT proBNP, troponins), widely measured in adult patients for diagnostic and prognostic purposes, should also be considered in paediatric patients with CMPs.	

(continued on next column)

(continued)

Recommendations for the diagnosis of genetic and rare CMPs	Symbol
Metabolic screening is recommended in infants and children with CMPs, and in selected cases, repeated sampling should be obtained at the time of diagnosis.	

## 2.2. Hypertrophic cardiomyopathy

### 2.2.1. Introduction

HCM is a disease of the heart muscle characterized by increased left ventricular wall thickness, not solely explained by loading conditions [12,14]. In adults, up to 60% of the patients harbour a mutation in sarcomeric proteins genes [14,15]. According to data from the SHaRe Registry, up to 60% of childhood-onset HCM are related to sarcomeric protein disease [16]. However, the prevalence of sarcomeric or non-syndromic HCM is relatively lower in infants (up to 46%), with higher rates of specific aetiologies [16–18,19].

### 2.2.2. Diagnostic work up and management of infant-onset HCM

According to large observational registries [16,17], infant-onset HCM (<1 year) is associated with increased morbidity and mortality compared with patients diagnosed during childhood. However, data from the SHaRe registry showed that childhood-onset group had a higher overall event rate during long-term follow-up than infant-onset group.

The most common aetiologies in infants with HCM are listed in Supplemental Table 1. Survival rates varied significantly according to the aetiology of infant-onset HCM, with sarcomeric or non-syndromic HCM showing a significant better prognosis compared with non-sarcomeric causes (especially inborn error of metabolisms) [18]. Thus, differential diagnosis is mandatory, and it can be raised by the presence of clinical markers (“red flags”) [19,20].

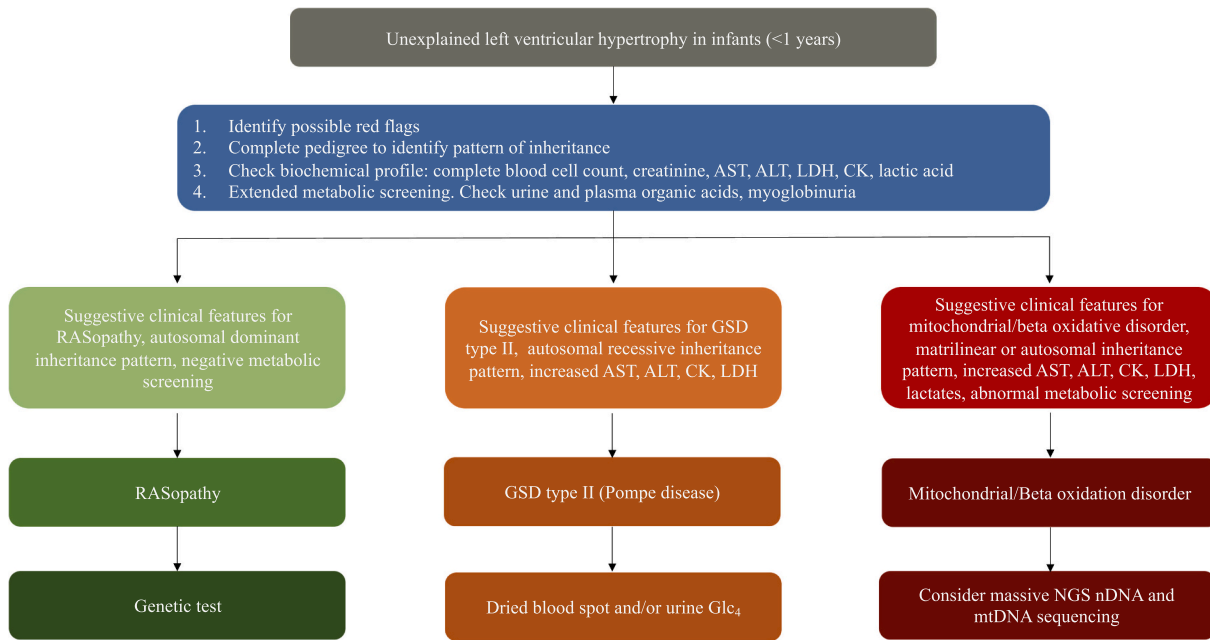
Presentation with heart failure associated with hypokinetic HCM is typical of lysosomal storage (i.e., Pompe) [21,22], metabolic (i.e., beta oxidation) [23], mitochondrial [24–30], whereas in malformation syndromes, LV failure seems related with hemodynamically significant LVOT or biventricular obstruction [31–34]. LVNC or either endocardial fibroelastosis may be described among carriers of TAZ gene mutation, both in form of isolated CMP or in the context of Barth syndrome, in the case of concomitant neutropenia or 3-methylglutaconic aciduria [35,36]. Non-obstructive, biventricular CMP is the most common phenotype in these patients, particularly when a coexistence of respiratory distress and/or lactic acidosis is present [37]. Laboratory results can highlight increased serum creatine kinase or transaminases levels.

On the other hand, LVOT or biventricular obstruction (particularly when a dysplastic pulmonary valve is present) in the presence of systemic involvement (polyhydramnios, craniofacial dysmorphism, cryptorchidism, endocrine, cutaneous, and skeletal abnormalities) may suggest the diagnosis of RASopathy [38–41]. 12-lead ECG can show a pre-excitation pattern, suggesting mitochondrial, glycogen storage disorders and/or beta oxidation deficits [21,42–46], high amplitude QRS complexes (Pompe disease) [19,47–49] or an extreme right-axis deviation in RASopathies [19].

Diagnostic work-up in infants with HCM should include a three-generation pedigree in order to identify the pattern of inheritance and baseline biochemical screening, comprehensive of serum creatinine, creatin kinase enzyme, transaminases and blood lactates. Clinical clues (red flags) for the diagnosis of specific aetiologies should be identified and, in selected cases, extended metabolic screening, urine and serum organic acid profile or the presence of myoglobinuria could help to orient diagnosis (Fig. 1).

### 2.2.3. Diagnostic work up in children and adolescents with HCM

In children and adolescents, mutations in sarcomeric genes represent the most common cause of HCM [50,51]. However, up to 30% of

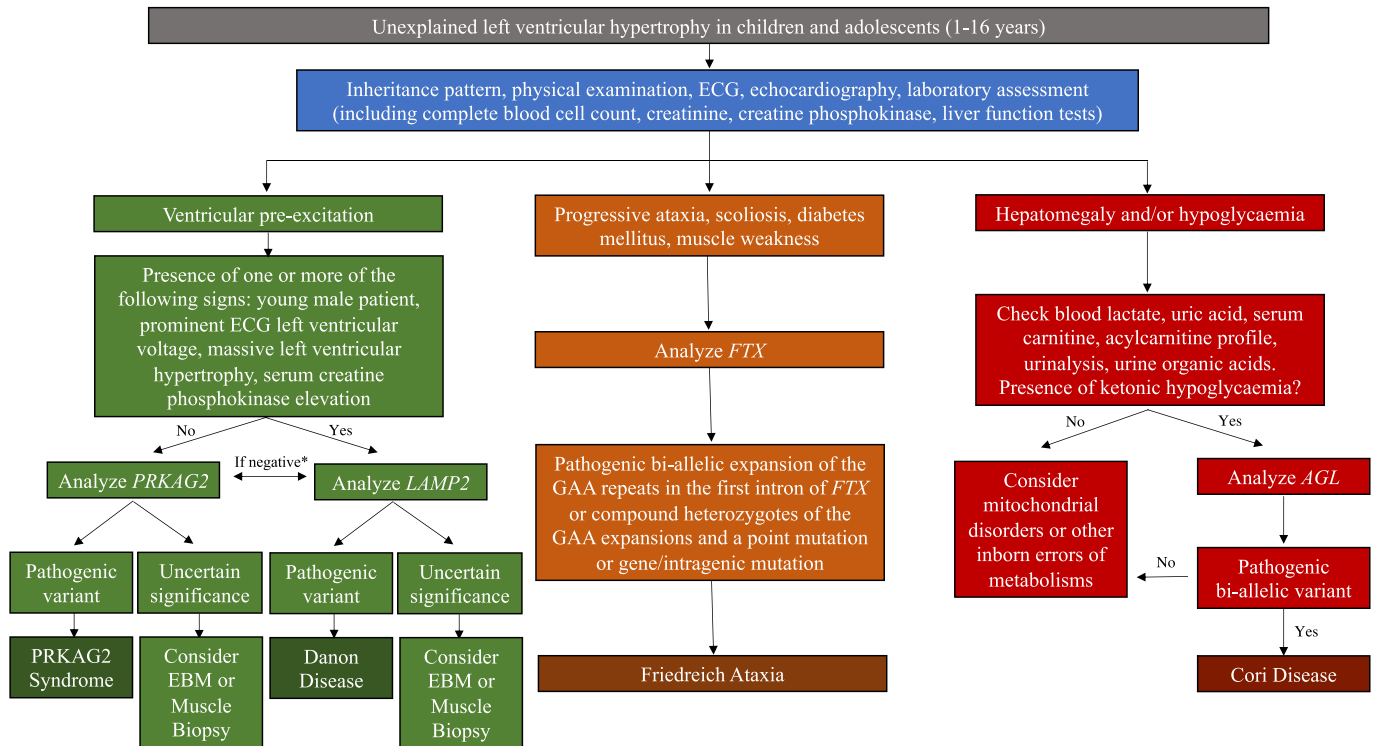


**Fig. 1.** Diagnostic work up in unexplained left ventricular hypertrophy in infants (<1 year).  
**Abbreviations:** ALT, alanine aminotransferase; AST, aspartate aminotransferase; CK, Creatine kinase; Glc4, glucose tetrasaccharide; GSD, glycogen storage disorder; LDH, lactate dehydrogenase; mtDNA, mitochondrial DNA; nDNA, nuclear DNA; NGS, next generation sequencing.

patients show a non-sarcomeric cause [16,17,52,53]. The most common aetiology in children and adolescents with HCM are listed in Supplemental Table 2. While Pompe CMP often appears in the first year of age [54], other glycogen storage disorders, such as Danon disease, PRKAG2 syndrome, and Cori-Forbes disease usually manifest in childhood [55–58]. Friedreich ataxia also represents an important cause of HCM in

children [59]. Considering the unfavourable outcome of these conditions, early diagnosis is required, and the aetiology can be suggested by the presence of different clinical markers [19,20] (Supplemental Table 2).

Patients with Danon disease or PRKAG2 syndrome carry an increased risk of arrhythmias, as shown by ventricular pre-excitation pattern on












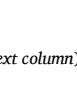
\*if both negative consider other rare cause of pre-excitation and unexplained LVH such as other glycogen storage disorders or mitochondrial disorders

**Fig. 2.** Diagnostic work up in unexplained LVH in children and adolescents (1-16 years).  
**Abbreviations:** ECG, electrocardiography; EBM, endomyocardial biopsy.

ECG, history of supraventricular tachyarrhythmias, AV blocks and even sudden cardiac death (SCD) [55,58]. Therefore, in the presence of ventricular pre-excitation, the presence of prominent ECG left ventricular hypertrophy (LVH), the echocardiographic evidence of massive left ventricular hypertrophy (LVH), the elevation of serum creatine kinase (CK), alanine transferase (ALT), and aspartate transferase (AST) values, are suggestive of Danon disease, while their absence is typical of PRKAG2 syndrome [60]. However, it should be remembered that a pre-excitation pattern can be found also in other glycogen storage disorders (e.g., Pompe disease) and in mitochondrial disorders [61]. On the other hand, the presence of gait ataxia, scoliosis, foot deformity is suggestive of Friedrich ataxia [62]. These manifestations may precede the occurrence of HCM, whereas diabetes mellitus is invariably delayed in the course of the illness [63]. Moreover, patients with Friedreich Ataxia exhibit a high prevalence of supraventricular arrhythmias [64].


















The diagnostic work-up in children and adolescents with HCM includes pedigree, physical examination, ECG, echocardiography, and baseline laboratory screening. The identification of diagnostic clues should orient the suspicion towards a specific condition and is useful to guide the subsequent diagnostic evaluation. The most common clinical scenario and the relative diagnostic work-up are shown in Fig. 2. Unfortunately, there is no etiological treatment for these conditions and the current treatment are based on symptomatic management [65].

Recommendations for the diagnosis and management of the most common aetiologies for infant and paediatric onset HCM are listed below.

Recommendations for the diagnosis and management of infant and paediatric onset HCM	Symbol
Fluid depletion must be avoided in infants with severe biventricular involvement (hypertrophy and/or obstruction) or where pathophysiology is preload dependent.	
<b>Recommendations for the management of HCM in RASopathies (R-HCM)</b>	
Non-vasodilating beta blockers and diuretics should be carefully administered in patients with R-HCM.	
Disopyramide may be considered in children with obstructive R-HCM, who remain symptomatic despite beta blockers.	
Surgical myectomy can be beneficial in patients with R-HCM who remain symptomatic for significant LVOTO despite maximal medical therapy.	
Orthotopic heart transplantation should be considered in patients with severe HF symptoms with: a) evidence of refractoriness to medical therapy; b) intractable ventricular arrhythmias c) cardiogenic shock requiring inotropes; d) severe diastolic dysfunction.	
Orthotopic heart transplantation may be considered in infants and children with signs of HF and LVOTO, when surgical myectomy is not feasible.	
Mechanical circulatory support may be considered as bridge to transplant in infants and children with RASopathies.	
In patients with amenable mutations, selective inhibitors of RAS/MAPK pathway may be considered for compassionate use.	
<b>Recommendations for the diagnosis of mitochondrial disease (MD)</b>	
Among patients with suspected MD a first level molecular screening for the most common mtDNA mutations (e.g., m.3243A > G, or m.4300A > G) is recommended to rule out an OXPHOS deficiency if biochemical panel is inconclusive.	
Skeletal muscle biopsy, endomyocardial biopsy (in patients with heart involvement) or opportunistic assessment of cardiac tissue obtained during other cardiac procedures should be considered as first line approach in patients requiring definitive diagnosis.	
<b>Recommendations for the cardiovascular assessment in mitochondrial disease</b>	








(continued on next column)

(continued)

Recommendations for the diagnosis and management of infant and paediatric onset HCM	Symbol
In selected patients with palpitations, personal history of syncope or risk factors for sudden AV block, and in individuals affected by KSS, 7-days Holter monitoring, implantable loop recorder devices or electrophysiological study may be considered.	
Cardiopulmonary exercise test with lactate determination may be considered in patients with MD, at baseline and during follow-up, to help clinical diagnosis and to assess functional capacity.	
<b>Recommendations for the treatment of mitochondrial disease</b>	
Endurance training can improve quality-of-life scores in patients with MD and is recommended in absence of contraindications.	
Drugs or situational stressors which could precipitate acute metabolic crisis are contraindicated in MD.	
<b>Recommendations for the treatment of bradyarrhythmias in mitochondrial disease</b>	
Permanent pacemaker implantation may be considered in patients with MD with a PR interval greater than 240 ms, a QRS duration greater than 120 ms, or any grade of fascicular block.	
<b>Recommendations for the diagnosis of Pompe disease</b>	
In infants and children with HCM and ≥ 1 red flag for Pompe disease, the combination of screening for GAA activity in DBS or leukocytes and Glc <sub>4</sub> urinary dosing are recommended. To confirm diagnosis, acid α-glucosidase (GAA) assay performed on skin fibroblasts (preferred method) or muscle biopsy are recommended.	
Acid α-glucosidase (GAA) genetic testing is recommended to confirm diagnosis, to identify gene carriers and in suspected late-onset Pompe disease with vascular or aortic involvement.	
<b>Recommendations for the management of HCM in Pompe disease</b>	
Careful administration of beta blockers and/or ACE inhibitors may be considered in selected patients with Pompe disease and heart failure symptoms.	
<b>Recommendations for the management of Pompe disease</b>	
Enzyme replacement therapy (ERT) is recommended in patients with infantile-onset Pompe disease.	
Cross-reaction immunologic material (CRIM) status should be assessed in patients candidate to ERT.	
Immunotolerance induction may be considered for patients who are candidate to ERT in paediatric centres with expertise in glycogen storage disorders, if not contraindicated.	
Miglustat may be considered as orphan drug in selected patients with infantile onset Pompe disease.	
<b>Recommendations for the diagnosis of Danon disease</b>	
In patients with HCM and ≥ 1 red flag for Danon disease, genetic test with identification of disease-causing mutation is recommended for the diagnosis.	
In patients carrying a LAMP gene variant of uncertain significance and high suspicion of Danon disease, the biopsy of an affected organ (e.g., heart, muscle) should be considered to confirm the diagnosis.	
<b>Recommendations for the management of HCM in Danon disease</b>	
ICD implantation should be considered in patients with severe left ventricular hypertrophy, non-sustained ventricular tachycardia and/or unexplained syncope.	
Orthotopic heart transplantation should be considered in patients with severe HF symptoms with evidence of refractoriness to medical therapy, intractable arrhythmias.	
<b>Recommendations for the management of arrhythmias in Danon disease</b>	
In symptomatic patients with recurrent episodes of atrioventricular re-entrant tachycardia, catheter ablation may be considered when symptoms cannot be relieved by pharmacological therapy alone considering the balance between clinical status and recurrence risk.	
<b>Recommendations for the diagnosis of PRKAG2 syndrome</b>	

(continued on next page)

(continued)

Recommendations for the diagnosis and management of infant and paediatric onset HCM	Symbol
In patients with HCM and ventricular pre-excitation, genetic test with identification of disease-causing mutation is recommended for the diagnosis.	
<i>Recommendations for the management of arrhythmias in PRKAG2 syndrome</i>	
In symptomatic patients with recurrent episodes of atrioventricular re-entrant tachycardia, catheter ablation may be considered when symptoms cannot be relieved by pharmacological therapy alone considering the balance between clinical status and recurrence risk.	
<i>Recommendations for the diagnosis of Cori disease</i>	
In patients with clinical red flags for Cori disease, genetic test with identification of disease-causing mutation in the AGL gene on both alleles is recommended for the diagnosis.	
<i>Recommendations for the management of Cori disease</i>	
A dietitian with expertise in glycogen storage disorders is recommended.	
In infants and children, small frequent feeding including complex carbohydrates and proteins (avoiding simple sugars), and introduction of corn-starch as early as first year of life, if hypoglycaemia is present, should be considered.	
In adolescent and adults, a dietary approach based on high protein intake, low complex carbohydrates, avoidance of simple sugar, and avoidance of fasting, is recommended.	
<i>Recommendations for the diagnosis of Friedreich ataxia</i>	
In patients with clinical red flags of Friedreich Ataxia, genetic testing with the identification of the bi-allelic expansion of the GAA repeats in the first intron of the FTX gene or the compound heterozygotes of the GAA expansion and a point mutation or a gene/intragenic deletion is required for diagnosis.	

2.2.4. Diagnostic work up and management of adult onset HCM

Differential diagnosis of adult onset HCM should include a complete work-up, in order to exclude potentially treatable HCM-mimics as cardiac amyloidosis (CA) and Fabry disease (FD) [19,66] (Fig. 3). Although its prevalence is uncertain, CA is overlooked in many clinical scenarios.

Recent autopsy data [67] reveal that among patients with heart failure with preserved ejection fraction (HFpEF), amyloid deposits can be found in almost 32% of patients older than 75 years of age. Non-invasive studies [68–70] have reported a prevalence of 13% among patients with HFpEF [71], 16% among patients with severe aortic stenosis requiring transcatheter aortic valve replacement [70,72] and 5% among patients with a diagnosis of HCM [73]. On the other hand, prevalence of FD ranges between 1 and 11% among patients with late-onset HCM [74–76]. Extracardiac and cardiac red flags, as proteinuria, peripheral neuropathy, gastrointestinal symptoms, valve thickening, right ventricular hypertrophy or reduced global longitudinal strain can be observed both in FD and CA [6,19,77]. Personal history of stroke/transient ischaemic attacks, hypohidrosis, angiokeratomas or visual impairment due to cornea verticillate may suggest FD, whereas bilateral carpal tunnel syndrome, lumbar spinal stenosis or autonomic dysfunction are typical of CA. Recently, a multimodality imaging score has been proposed to suspect CA [78]. Red flags for differential diagnosis of late onset HCM are listed in Supplemental Table 3. In patients in whom cardiac or extracardiac red flags are inconclusive to orient diagnosis, cardiac magnetic resonance (CMR) with T1 mapping should be considered: late gadolinium enhancement in the inferolateral wall and low native T1 are typical of FD, in addition, because storage disorder is predominantly intracellular in FD, extracellular volume (ECV) is typically normal in FD, in contrast with CA [79–88].

In patients with clinically suspected CA, serum and urine immunofixation, kappa/lambda free light chain ratio and baseline biochemical profile should be obtained: in the absence of monoclonal chain, radio-nuclide bone scintigraphy can lead to a definitive diagnosis [68,77] (Supplemental Fig. 1-2). On the other hand, α-galactosidase A activity should be the first diagnostic test in male patients with suspected FD [89]. In female patients with suspected FD and/or in male patients with reduced α-Gal A activity genetic testing with the identification of the GLA disease-causing mutation should be performed, in order to confirm diagnosis [89,90] (Supplemental Fig. 3).

Recommendations for the diagnosis and management of the most

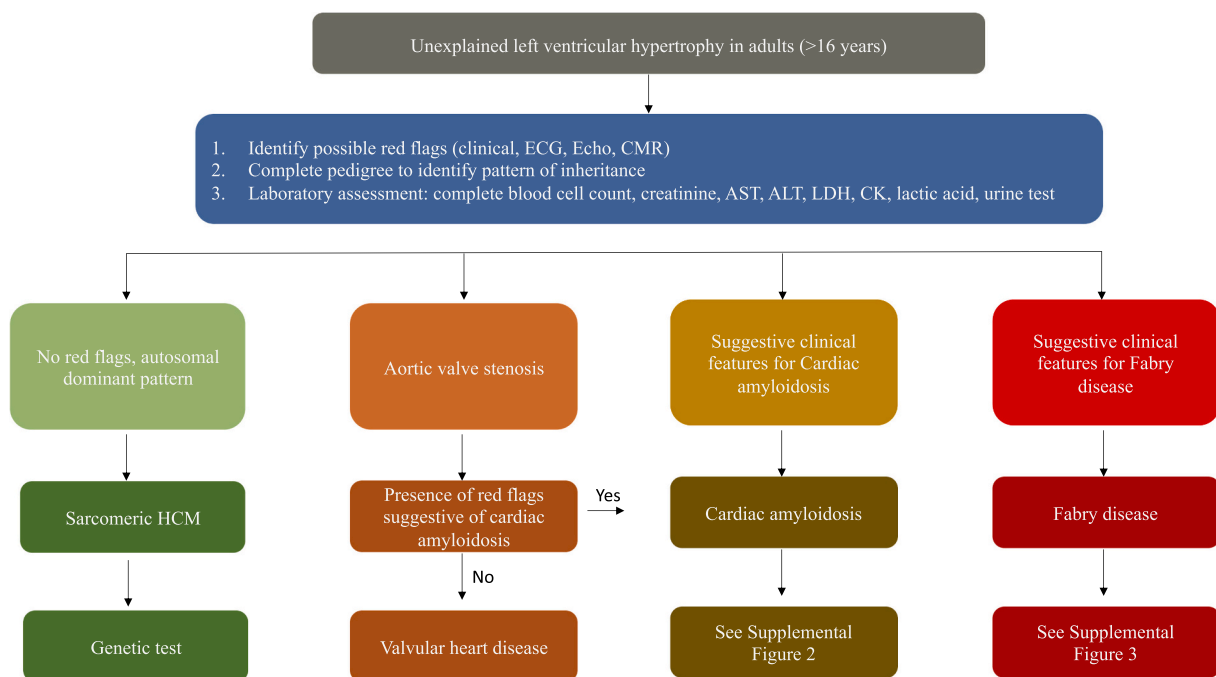


Fig. 3. Diagnostic work up in unexplained left ventricular hypertrophy in adults (>16 years).

Abbreviations: ALT, alanine aminotransferase; AST, aspartate aminotransferase; CMR, cardiac magnetic resonance; CK, Creatine kinase; ECG, electrocardiography; LDH, lactate dehydrogenase; HCM, hypertrophic cardiomyopathy.

common aetiologies for adult-onset HCM are listed below.

Recommendations for the diagnosis and management of adult-onset HCM	Symbol
<i>Recommendations for non-invasive testing in ATTR-CA</i>	
In patients with HCM and > 1 red flag for the diagnosis of cardiac amyloidosis, serum and urine immunofixation and/or serum free light chain titration in combination with radionuclide bone scintigraphy with technetium-labelled bisphosphonates are recommended.	
CMR with non-contrast T1 mapping and extracellular volume quantification may be considered to assess amyloid burden and define prognosis.	
Endomyocardial biopsy is recommended in patients with inconclusive first line tests for ATTR-CA.	
New echocardiographic technologies are useful for diagnosis and prognosis of patients with CA and global longitudinal strain should be considered in prognostic stratification of AL-CA.	
Regardless of age and familial history of CA, genetic testing is recommended in patients with confirmed ATTR-CA.	
Regular monitoring should be considered in carriers of a mutation of interest at least 10 years before the predicted age of onset of symptoms.	
Serum creatinine, high sensitivity troponin assay and serum natriuretic peptides are recommended for the purposes of prognostic stratification in patients with ATTR-CA.	
<i>Recommendations for the medical therapy of amyloidosis with HF</i>	
Beta blockers, ACEi and ARBs are not currently recommended in patients with ATTR-CA, unless there is an additional indication.	
Non dihydropyridine calcium channel blockers are not recommended in ATTR-CA.	
<i>Recommendations for the management of atrial fibrillation in patients with cardiac amyloidosis</i>	
In patients with ATTR-CA and AF (clinical and subclinical) anticoagulation with VKA or DOAC is recommended, if not contraindicated, irrespective of CHA2-DS2-VASc score.	
Transoesophageal echocardiography should be considered before DCV in patients with AF and ATTR-CA, irrespective of anticoagulation.	
If a rhythm control strategy is preferred, amiodarone should be considered as first choice treatment.	
<i>Recommendations for the management of ATTR-CA</i>	
Tafamidis is recommended in patients with wtATTR or mATTR-CA with class I-II NYHA symptoms in order to slow disease progression.	
Tafamidis may be considered in patients with wtATTR or mATTR-CA with class III NYHA symptoms in order to slow disease progression.	
Patients with mATTR-CA and evidence of polyneuropathy should be considered for treatment with TTR silencers (patisiran or inotersen) or tafamidis.	
Treatment with TTR silencer is not recommended in patients without neurological involvement.	
Liver transplantation is not recommended in ATTR-CA.	
<i>Recommendations for the diagnosis of Fabry disease</i>	
In patients with adult-onset HCM and > 1 red flag for Fabry disease, the evaluation of $\alpha$ -Gal A activity in men and genetic testing in female, is recommended as first diagnostic approach.	
<i>Recommendations for cardiovascular assessment in Fabry disease</i>	

(continued on next column)

(continued)

Recommendations for the diagnosis and management of adult-onset HCM	Symbol
Cardiac magnetic resonance with non-contrast T1 mapping should be considered in adult patient to detect early cardiac involvement and for the purposes for differential diagnosis.	
The measurement of lyso-Gb3 should be considered for diagnostic confirmation.	
The measurement of lyso-Gb3 may be considered to assess therapeutic response.	
<i>Recommendations for the management of Fabry disease</i>	
Enzyme replacement therapy is recommended as first line treatment in male patients with classical disease, regardless of organ involvement.	
Enzyme replacement therapy should be considered in male patients with late-onset mutations or in female patients with classical or late-onset mutations, at the first sign of vital organ involvement.	
In patients with amenable GLA disease-causing mutations, migalastat should be considered in all symptomatic patients with classical or later onset disease, at the earliest sign of organ involvement, as alternative treatment to enzyme replacement therapy.	

### 2.3. Dilated cardiomyopathy

#### 2.3.1. Introduction

Dilated cardiomyopathy (DCM) is a heart muscle disease characterized by left or bi-ventricular systolic dysfunction, associated with chamber dilation, which cannot be explained solely by evidence of volume or pressure overload [1]. In absence of chamber dilatation, the term hypokinetic-nondilated cardiomyopathy (HNDC) should be preferred. DCM is the most common CMP, both in adult and paediatric population, with an estimated prevalence of 1:2500 and 1:170000, respectively [91,92]. Moreover, with the inclusion of secondary forms of DCM, the estimated prevalence increases to 1:250 besides being considered a rare disease, DCM emerged to be more common than previously estimated, with a wide spectrum of genotype-phenotype interactions [93].

DCM predominantly affects the male gender (with a male: female ratio of 1:3) and typically manifests in the third-fourth decade of life.

Although paediatric DCM has a lower annual incidence compared with adult-onset DCM, the outcome for DCM in young patients has shown to be particularly severe, being the first cause of heart transplantation in children [94,95]. According to the 20th ISHLT Paediatric Heart Transplantation Report [96], the annual number of heart transplants in children significantly increased in the last 5 years, and roughly 300 children are listed annually for heart transplantation due to DCM [97].

In some paediatric populations, it has been pointed out that even if the disease usually appears less severe at baseline compared with adults, in part thanks to the familial screening [98], the long-term outcome shows significantly reduced 5-year survival rates and freedom from heart transplantation.











The severe prognosis of paediatric DCM may suggest a rapid disease progression in young patients, with a more aggressive disease course compared with adults, both in terms of heart failure progression and need for heart transplant/mechanical circulatory support (MCS) and severe, life-threatening arrhythmias [91,94,99].

The causes of this severe disease's phenotype in children remain insufficiently characterized [100]. One possible explanation is the presence of particularly aggressive genetic mutations which lead to an early-onset, more arrhythmic and rapidly progressive disease [91]. On the other hand, mild DCM forms due to Titin (TTN) gene mutations become more prevalent among older people, possibly because they may need an environmental trigger (hypertension, tachyarrhythmias,

alcohol or chemotherapy exposure) that typically emerges later in life [101–103].

Accordingly, a family history of DCM among paediatric patients has been reported to be twice as common as among the adults and a positive family history for DCM resulted a predictor of arrhythmic events [94]. This topic highlights also the challenging issue of arrhythmic protection with an ICD in this population, existing a low level of evidence in the current heart failure paediatric guidelines and some ethical and technical difficulties [99]. Thus, it is important to assure an individualized and holistic approach to these patients, with a close follow-up and a more aggressive treatment [91,94,104].

General recommendations on the diagnosis and management of DCM are listed below.

Recommendations for the diagnosis and management of DCM	Symbol
In children and adolescents with family history for DCM and carriers of a pathogenic/likely pathogenic variant, regular annual follow-up, comprehensive of 12 lead ECG, echocardiogram and 24 h Holter monitoring may be considered irrespective of LVEF, giving particular attention to the arrhythmic risk.	
Coronary-CT and invasive hemodynamic assessment is recommended for the differential diagnosis of infantile-onset DCM when coronary anatomy is suspicious for ALCAPA and echocardiography is uncertain.	
A comprehensive investigation of alcohol or drug abuse, previous chemotherapies or cardiotoxins, pregnancy status, recent infectious diseases, endocrine or autoimmune disorders, neuromuscular involvement and the exclusion of ischemic symptoms are recommended in adolescents and adults with unexplained LVEF < 50%.	
Genetic testing is recommended in familial forms of DCM and needs to be performed in a) sporadic forms of DCM and > 1 red flag for specific genetic aetiologies b) after exclusion of secondary aetiologies (i.e., valvular heart disease) c) in first degree relatives of a proband with pathogenic/likely pathogenic mutation.	
In patients with DCM and > 1 red flag for autoimmune disease, serology for antinuclear antibodies (ANA), anti-neutrophil cytoplasmic antibodies (ANCA) and aetiology-specific tests is recommended.	
Endomyocardial biopsy must be performed at experienced centres and is recommended in patients with acute heart failure requiring inotropes or MCS, ventricular arrhythmias/cardiogenic shock, new onset high grade AV block or when CMR or non-invasive evaluation suggest a diagnosis of chronic myocarditis/inflammatory DCM, unless contraindicated.	
Anti-heart antibodies and molecular tests including polymerase chain reaction (PCR) for viral genome on myocardial specimens should be considered to guide treatment strategies in patients with chronic myocarditis/inflammatory DCM only in high volume centers with specific expertise.	
Guideline-derived optimal medical therapy (OMT) at maximum tolerated dose is recommended in patients with DCM, irrespective of aetiology.	
According to current guidelines, the decision to implant an ICD needs to consider the age of the patient, NYHA class, aetiology (ischemic, non-ischemic, specific genetic aetiology), LV systolic function and life expectancy.	
Left ventricular assist device (LVAD) should be considered for patients with severe HF as bridge to decision, destination therapy or bridge to transplant.	

### 2.3.2. Diagnostic work-up and management of neonatal, children and young adults DCM

The age-specific aetiologies and red flags of DCM in infants, children and young adults are listed in Supplemental Table 4. A comprehensive clinical evaluation by a multidisciplinary cardiomyopathy team including paediatricians, geneticists, cardiac surgeons, neurologists and metabolic disease experts is recommended. Congenital heart diseases with left-to-right shunts, tachycardia-induced cardiomyopathy, coronary artery anomalies including anomalous origin of the left coronary artery from the pulmonary artery (ALCAPA) or Kawasaki disease should be ruled out in paediatric patients with suspected DCM. In children with muscular weakness, delayed motor milestones, elevated serum CK and

disproportion between the severity of dyspnoea and the magnitude of cardiovascular involvement, an underlying neuromuscular disorder should be suspected.

The muscular dystrophies of Duchenne, Becker and Emery-Dreifuss are frequently associated with DCM, often with an increased risk of progressive atrioventricular block (AVB) and ventricular arrhythmias [105].

Neuromuscular disorders may be rarely associated with infant-onset DCM, in particular specific aetiologies, including nemaline myopathy, systemic primary carnitine deficiency and Barth syndrome have been reported.

Although HCM represents the most common cardiovascular phenotype in mitochondrial diseases, DCM and left ventricular noncompaction (LVNC) have been described [106]. Barth syndrome (BS) is a rare X-linked mitochondrial cardiomyopathy caused by mutation in *TAZ* gene, encoding for the mitochondrial transacylase *tafazzin*. BS was initially associated with the triad of DCM, cyclic neutropenia and 3-methylglutaconic aciduria. However, these hallmark features may not be present in a significant number of patients, being exercise intolerance, abnormal heart rate response and higher respiratory exchange ratios during CPET the only clinical manifestation. Cardiovascular involvement in BS may include DCM, LVNC, supraventricular or ventricular arrhythmias and SCD. Left ventricular remodelling follows a typical trajectory, with an undulating phenotype with severe hypokinetic evolution during infancy followed by an improvement during toddler-years and a late slow decline of left ventricular systolic function during childhood and adolescence [106]. ALCAPA, a congenital coronary anomaly causing unexplained left ventricular systolic dysfunction, should be included in differential diagnosis of DCM in infants, particularly because of its poor prognosis if untreated, with a mortality rate approaching 90% within the 1-year [107]. Early repair with coronary arteries reimplantation results in low operative mortality and progressive improvement in left ventricular systolic function, even in case of extended cardiac fibrosis. Differential diagnosis with DCM could be suggested by the finding of broad Q waves in aVL in association with negative T waves (QT pattern), enlarged right coronary artery (RCA/aortic anulus ratio > 0.14), hyperechogenic papillary muscles or inverted colour Doppler flow in left coronary artery (LCA).

Inflammatory DCM should be suspected among the possible aetiologies of DCM in children and young adults [91,108], accounting for up to 16% of paediatric DCM in the United States. Of note, acute myocarditis in paediatric patients seems to have a more aggressive course than in adults, probably because of a predominant immune response; nevertheless, inflammatory DCM in this population is likely to be particularly severe, requiring aggressive therapeutic strategies and close follow-up.

Finally, children with structural congenital heart disease treated by palliative/corrective surgery may present with heart failure due to systolic dysfunction of systemic or sub-pulmonary ventricle. This phenomenon can occur in a wide spectrum of conditions, such as valvular, surgical sequelae, ischemic- and underlying causes should be carefully evaluated. Lipshultz et al. [109] suggested that an abnormal cardiac function not solely or completely explained by abnormal structural disease and hemodynamic overload, an underlying heart muscle disease should be excluded [110].

### 2.3.3. Diagnostic work-up and management of adult-onset DCM

When acquired environmental triggers of left ventricular dysfunction have been excluded, genetic DCM should be considered, particularly when patients report a positive family history of the disease [111]. In familial DCM, cascade screening of first-degree relatives allows to achieve an early diagnosis and prompt prophylactic therapy in preclinical disease's forms. Up to 40% of adult-onset DCM is genetically determined, with a possible underestimation due to variable clinical presentation and incomplete penetrance [93,112].

Genetic DCM can be caused by a variety of mutations, mainly



involving sarcomere genes, ion channels, Z-band and cytoskeletal proteins.

Although evidence is insufficient to define genotype–phenotype correlations in patients with genetic DCM, specific genes seem to be associated with common phenotypic traits, like the propensity for ventricular arrhythmias in mutated desmosomal genes [113,114], Filamin-C gene (FLNC) [115], phospholamban gene (PLN) or lamin (LMNA) [116,117,118], leading to different management strategies (Supplemental Table 5).

Natural history studies enrolling patients diagnosed with LMNA cardiomyopathy show an increased prevalence of high grade atrioventricular blocks and atrial fibrillation, which can precede the development of ventricular arrhythmias and over systolic dysfunction [119,120]. Risk factor for sudden cardiac death may include LVEF <45%, male sex, more than 500 PVC on ECG Holter monitoring and nonmissense variant carrier status [120]. The phenotype of R14del PLN variant carriers is characterized by low-amplitude ECG voltages, high prevalence of malignant ventricular arrhythmias and severe systolic dysfunction. Recently, a validated cohort model has identified LVEF, the amount of PVC/24 h, amount of negative waves and the presence of low voltage ECG pattern as predictors of the composite outcome of SCD, sustained ventricular arrhythmia and/or appropriate ICD discharge with high discriminative ability [121]. FLNC truncating mutations have been associated to a particular overlapping phenotype of dilated and left dominant arrhythmogenic cardiomyopathy with dominant transmission pattern [115]. Extended cardiac fibrosis, low amplitude QRS complexes and repolarization abnormalities in the infero-lateral leads were observed in the study cohort, which experienced high rates of SCD. Interestingly, immunohistochemical analysis did not show intracellular filamin aggregates, unlike among carriers of missense mutations with FLNC-associated myofibrillar myopathy.

With the development of large familial genetic screening, the mean age of DCM onset has changed over the years, resulting in a later onset of the disease. The explanation for this phenomenon may reflect the increasing penetrance over time of TTN gene mutations, which account for the majority of familial DCM [102].

However, several non-genetic causes of DCM are common in adults. Supplemental Table 6 lists the most common aetiologies and the clinical clues (red flags) of adult-onset DCM.

Inflammatory DCM should be included in the differential diagnosis of new-onset DCM in adult patients [122–124,125]. In patients with incident DCM or unexplained ventricular arrhythmias, CMR is mandatory to exclude a previous myocardial inflammation based on the regional distribution of late gadolinium enhancement (LGE), although its sensitivity is lower in chronic forms. EMB, due to its invasive nature, should be considered only in life-threatening clinical scenarios or when a specific, potentially reversible, aetiology is suspected.

A recent history of drug hypersensitivity, nasal polyposis, glomerulonephritis or severe asthma, and/or the identification of peripheral eosinophilia may trigger the suspicion of eosinophilic myocarditis. On the other hand, giant cell myocarditis should be always excluded in acute, fulminant HF, particularly when associated to cardiogenic shock requiring mechanical circulatory support or inotropes. In these clinical scenarios EMB is crucial for diagnosis and to set the appropriate treatment strategy [126].

Although data from randomized studies are limited, immunosuppressive therapy may represent the first option of treatment in autoimmune/immune mediated DCM, when the exclusion of viral and infective aetiology has been ascertained.

Peri-partum cardiomyopathy (PPCM) [127,128] and iron overload cardiomyopathy [129] represent rare forms of DCM and should be included in the initial work-up, in order to direct potential treatment strategies. Therefore, blood sampling investigation should always include serum iron, ferritin, transferrin and total iron binding capacity, permitting a resolute therapy in case of a positive result.

In conclusion, due to the complexity and heterogeneity of DCM, with












several different aetiologies and genetic backgrounds of DCM, each patient should be evaluated in an holistic approach [93].

In the absence of known responsible environmental factors, which have to be investigated even in the absence of clinical evident suspicion, a genetic investigation is recommended [93,112,117].

This is particularly important for some genotypes involving mutations in desmosomal genes, LMNA, FLNC, PLN, as they seem to be associated with arrhythmogenic phenotypes of DCM, in which the implantation of an ICD in primary prevention may be considered even in presence of moderate left ventricular systolic dysfunction [3,116,130].

In contrast, in paediatric population the implantation of ICD has to be always taken into account since the DCM phenotype in young people appeared to be especially aggressive, requiring a closer and more careful follow-up [91,93].

Recommendations for the diagnosis and management of the most common aetiologies for paediatric- and adult-onset DCM are listed below.

Recommendations for diagnosis and management of patients with DCM	Symbol
<b>Neuromuscular diseases</b>	
In patients with clinically suspected Duchenne or Becker's dystrophy cardiovascular evaluation should be performed at diagnosis and on annual basis, starting from the age of 10. Cardiovascular assessment is recommended every 2 years in asymptomatic children <10 years.	
Comprehensive genetic test (comprehensive of <i>PLN</i> , <i>SCN5A</i> , <i>LMNA</i> , <i>EMD</i> , <i>LGMD1B</i> , <i>MD1</i> gene testing/sequencing) and neuromuscular evaluation is recommended in presence of family history of DCM associated with SCD, progressive AVB, or premature atrial fibrillation.	
In patients with limb-girdle muscle dystrophy, myofibrillar myopathy and myotonic dystrophy, 48 h Holter monitoring, loop recorder ECG monitoring should be considered for the assessment of symptomatic palpitations.	
In patients with limb-girdle muscle dystrophy, and myofibrillar myopathy EPS may be considered for the assessment of symptomatic palpitations.	
In patients with myotonic dystrophy and palpitations, syncope, atrial flutter/atrial fibrillation, PR interval > 240 msec, QRS duration >120 msec, second- or third-degree atrioventricular block, EPS should be considered to evaluate infra-Hisian conduction and malignant arrhythmias.	
Glucocorticoids (deflazacort) should be considered in patients with Duchenne and Becker's dystrophy, unless contraindicated, on top of guideline-derived optimal medical therapy (OMT).	
ICD may be considered in patients affected by neuromuscular disorders with high-risk features for SCD, particularly in patients with Duchenne and Becker's muscular dystrophy, Emery-Dreifuss dystrophy, Limb-girdle muscular dystrophy 1B and myotonic dystrophy unless a short-term negative outlook is present due to systemic involvement, and after careful evaluation of the risk-benefit balance.	
ACE inhibitors should be started at 10 years of age, in asymptomatic Duchenne and Becker's muscular dystrophy.	
<b>Mitochondrial/beta oxidative disorders</b>	
See HCM	
<b>Myocarditis/inflammatory cardiomyopathy</b>	
In patients with suspected myocarditis, personal history of recent infection, immune checkpoint inhibitors administration, recent drug exposure, and/or history of systemic autoimmune disorders is recommended.	
In patients with inflammatory DCM/chronic myocarditis, negative viral PCR, and signs of ongoing myocardial leukocyte infiltration, immunosuppression may be considered.	
Empirical immunosuppressive therapy may be harmful when a positive PCR testing for viral agents has not been excluded on myocardial specimens.	
<b>Sarcoidosis</b>	
See ACM	
<b>Iron Overload</b>	
See RCM	
<b>Peripartum Cardiomyopathy</b>	

(continued on next page)

(continued)

Recommendations for diagnosis and management of patients with DCM	Symbol
PPMC needs to be excluded in new onset HF which began in the last months of pregnancy or months after delivery, when other possible aetiologies have been excluded.	
Counselling about the risks of a subsequent pregnancy is recommended in women with confirmed PPCM.	
Comprehensive genetic test should be considered in woman with confirmed PPCM.	
Urgent delivery should be considered in pregnant patients with hemodynamic instability, if the foetus is viable and induction of lung maturation (>23 W) has been performed, after careful assessment by the Heart team.	
Short term (2.5 mg once daily for a week) or long term (2.5 mg twice daily for 2 weeks followed by 2.5 mg once daily for 6 weeks) bromocriptine should be considered in women with acute PPCM.	
Anticoagulation (UFH or LWMH) should be considered in women with severe systolic dysfunction and PPCM.	
A wearable defibrillator may be considered in pregnant women at high risk of ventricular arrhythmias, allowing protected LV function recovery.	
<b>Chemotherapy-induced DCM</b> In patients treated with chemotherapies, a comprehensive cardiovascular assessment is recommended at baseline evaluation and repeated at regular intervals or with the development of new symptoms.	
Among patients treated with adriamycin, divided continuous infusions, encapsulated liposomal formulations and use of cardioprotective agents (i.e., dexrazoxane) may be considered in patients at high risk of cardiac toxicity.	
Cardiac biomarkers (troponins and B-natriuretic peptide) should be measured at regular intervals.	

profile, characterized by increased ventricular stiffness, restrictive filling pattern and elevated filling pressures with only small increases in volume. This result in a prominent “y” descendent on the atrial pressure curves and in the *square root* or *dip and plateau sign* on ventricular pressure curves.

RCM recognizes several aetiologies, including inherited and acquired causes, which are listed in Fig. 4.

General recommendations for management of RCM are listed below.

Recommendations for the management of RCMs	Symbol
Beta blockers and calcium channel blockers are not currently recommended in children and adults with genetic RCMs, unless there is an additional indication (e.g., supraventricular arrhythmias, hypertension).	
Angiotensin converting enzyme (ACE) inhibitors and angiotensin receptor blockers (ARB), may be considered only if other indication is present (i.e., arterial hypertension).	
Digoxin, inotropes drugs (such as dopamine, dobutamine and epinephrine), pulmonary vasodilators (such as prostaglandins) and endothelin receptor antagonists are not recommended, unless other indication is present.	
Orthotopic heart transplantation must be considered in patients with severe HF symptoms with evidence of refractoriness to medical therapy or intractable ventricular arrhythmias.	
Orthotopic heart transplantation may be considered in patients with severe HF symptoms with evidence of refractoriness to medical therapy and progressive increase in pulmonary vascular resistance.	
Left ventricular assist device (LVAD) should be considered for patients with severe HF as bridge to decision, destination therapy or bridge to transplant.	

## 2.4. Restrictive cardiomyopathy

### 2.4.1. Introduction

Restrictive cardiomyopathy (RCM) is characterized by impaired ventricular filling with normal or reduced diastolic volumes in the presence of normal ejection fraction and ventricular wall thickness [1]. Despite different aetiologies, RCM recognizes a peculiar haemodynamic

### 2.4.2. Neonatal, children and young adults

RCM is rare in children, accounting for 2-5% of all paediatric cardiomyopathies [131]. The mean age at diagnosis ranges from 6 to 11 years old, and a higher prevalence in girls has been described. The prognosis is poor, with a 2-year survival <50%, being heart transplantation the only effective treatment [132,133].

The term “idiopathic” RCM should not be used, given the frequent positive genetic findings. The Paediatric Cardiomyopathy Registry Investigators performed a whole-exome sequencing of 36 genes involved in cardiomyopathies and reported a pathogenic or likely pathogenic sequence variant in 50% of children with RCM. The most frequent mutations are responsible for sarcomeric molecular defects, accounting of one third of the cases [131]. Notably, an overlap between HCM and

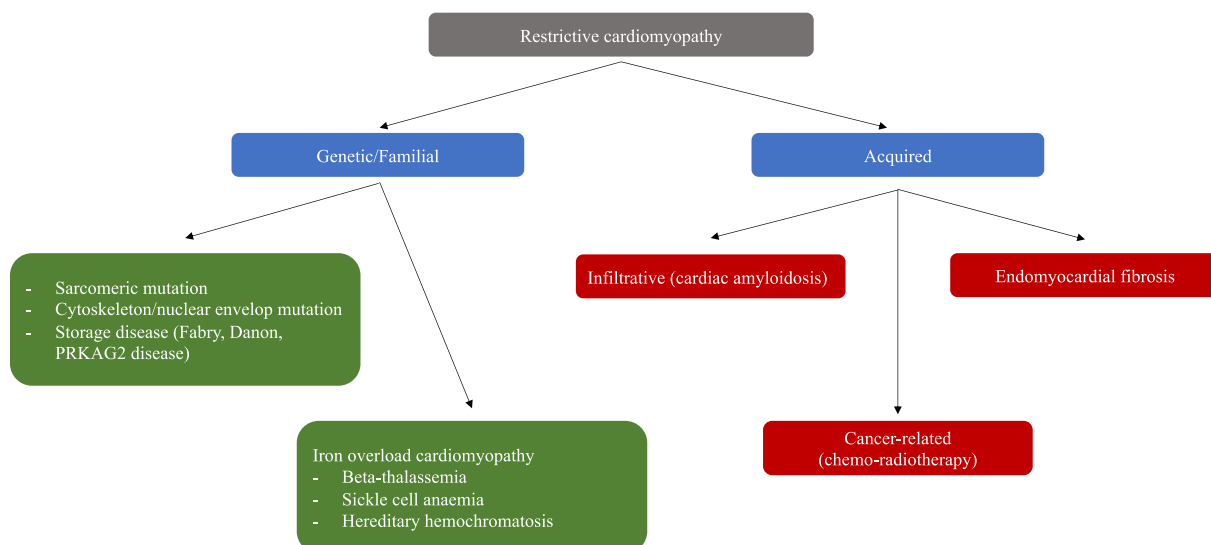


Fig. 4. Common aetiologies of restrictive cardiomyopathy.

RCM has been described in patients with sarcomeric mutations, with the same molecular defect resulting in one or the other phenotype, also in the same family members [132,134]. Cytoskeleton/nuclear envelope mutations (desmin, lamin and filamin C) are sometimes associated with early skeletal muscle involvement and atrio-ventricular conduction disturbances [134,135,136,137].

Tropical endomyocardial fibrosis (EMF) still represent the most common cause of RCM worldwide, affecting more than 12 million people, although it is commonly reported in equatorial developing countries. The precise aetiology is still unknown, and the natural history is characterized by recurrent hot phases of inflammation and eosinophilia, leading to deposition of fibrous tissue in endomyocardium and resulting in a chronic biventricular RCM. Usually both ventricles are involved, although an exclusive right ventricle involvement has been described, with chronic venous hypertension [138].

Given the typically normal or near normal biventricular systolic function until end stage of the disease, the clinical scenario of patients with RCM is represented by HFpEF, with symptoms as dyspnoea, poor appetite, ascites, peripheral oedema, and hepatomegaly. Children with RCM may have nonspecific findings, such as history of frequent respiratory infections. Diastolic dysfunction leads to progressive atrial enlargement which, in turn, may result in arrhythmias, thromboembolic complications, and secondary mitral regurgitation [139]. SCD or syncope resulting from ventricular arrhythmias or conduction abnormalities may represent the first expression of the disease [140,141]. Risk factors for SCD may include previous aborted cardiac arrest/sustained ventricular arrhythmias, a personal history of syncope and ischemia-related manifestations [140]. The decision for ICD implantation in paediatric RCM should consider the individual risk for SCD, the competitive HF-related morbidity, extracardiac comorbidities and patient's preferences, and should be assessed after a multidisciplinary heart team discussion.

Other RCMs aetiologies, such as storage diseases (PRKAG2, Danon and Fabry disease) are described in detail in HCM section, due to the mainly hypertrophic phenotype. For cardiac amyloidosis and cancer related cardiomyopathy please refer to specific available documents.


2.4.3. Adults

Iron overload cardiomyopathy (IOC) is secondary to increased deposition of iron in the heart independent of other concomitant processes and is caused by increased gastrointestinal iron absorption (primary hemochromatosis, which includes hereditary forms) or excess administration of iron with diet or red blood cell transfusions (secondary hemochromatosis, also called hemosiderosis) [142]. These conditions are listed in Supplemental Table 7 [143]. Its prevalence is expected to increase with the improvement in life expectancy of hematologic disorders.

Regardless of its origin, IOC is characterized by a restrictive physiology, with early diastolic dysfunction progressively evolving to an end-stage DCM [144]. Additionally, valve disorders, tachyarrhythmias and AVB may develop, even in the early stage of the disease [129].



















Considering the specific underlying pathophysiological mechanisms and treatment strategies, red flags such as serum ferritin and multiorgan involvement should direct the clinician to suspect IOC and therefore prompt specific diagnostic tests. In this scenario, T2 mapping with a cut-off value of <20 ms at 1.5 Tesla CMR has been proposed as a predictor of adverse events and is currently used in monitoring and management of these patients [129] (Supplemental Fig. 4).

Recommendations for the diagnosis and management of adult aetiologies of RCM are listed below.

Recommendations for diagnosis and management of genetic RCMs	Symbol
Cardiac catheterization should be considered:	
- to distinguish between restrictive and constrictive physiology	

(continued on next column)

(continued)

Recommendations for diagnosis and management of genetic RCMs	Symbol
- to determine the severity of the diastolic dysfunction by directly measuring biventricular filling pressures	
- to test for pulmonary vasoreactivity in children with elevated pulmonary vascular resistance.	
Cardiac catheterization with pulmonary vascular resistance study should be considered every 6-12 months, even in the absence of symptoms or demonstrated pulmonary hypertension, to ensure optimal timing for transplantation.	
Plasma levels of natriuretic peptides measurement should be performed in all patients, especially in the differential diagnosis with constrictive pericarditis.	
Endomyocardial biopsy may be considered only in those cases in which non-invasive diagnostic pathway has not reached a definite diagnosis.	
Recommendations for the diagnosis of endomyocardial fibrosis (EMF) Echocardiography with ultrasound contrast medium is the gold standard tool for the diagnosis of EMF in adults.	
Laboratory tests should be considered in patients with suspected EMF (absolute eosinophilia), but a negative result should not rule out the diagnosis.	
CMR should be considered for further characterization of EMF and for the differential diagnosis in patients presenting with apical obliterations, mimicking apical HCM.	
Endomyocardial biopsy and cardiac characterization may be considered in patients with non-unequivocal findings.	
Support therapies, such as diuretics to prevent fluid overload, are recommended in EMF, as bridging approach before surgery or heart transplantation.	
Anticoagulation therapy may be considered, if not contraindicated, in patients with EMF to prevent cardioembolic events and for differential diagnosis with LV apical thrombosis.	
Recommendations for cardiac sarcoidosis See ACM	
Recommendation for diagnosis of iron overload cardiomyopathy Genetic test for common hereditary hemochromatosis mutations (HFE C282Y and H63D) is recommended in patients with one or more of the following:	
- individuals with a family history of HH;	
- Individuals with documented iron overload (i.e., liver disease) as a means of determining the genetic contribution	
In patients with a suspected iron overload condition based on symptoms and altered laboratory exams (complete blood count, liver functional tests, serum ferritin and transferrin saturation), screening for cardiac involvement with 12-lead ECG and echocardiogram is recommended.	
In patients at risk of iron overload cardiomyopathy (i.e., thalassemia with repeated red blood cells transfusions) transthoracic echocardiogram with full diastolic function assessment and mitral annular tissue velocities is recommended every 1-2 years.	
MRI with T2 and T2* weighted scans (normal value >20 milliseconds) is recommended in patients with suspected iron overload condition or idiopathic cardiomyopathy for non-invasively assessment of cardiac iron deposition, routinely follow-up and therapy monitoring.	
Liver biopsy may be considered in patients who do not have access to MRI, or those who require precise estimation of liver burden or assessment of liver histology (i.e., thalassemia patients prior to hematopoietic stem cell transplant).	
Recommendation for treatment of iron overload cardiomyopathy (IOC) The use of disease-specific treatment with appropriate iron chelation and/or phlebotomy when indicated are recommended to prevent multiorgan failure.	
In patients in NYHA functional class IV stage, despite optimal medical therapy including cardiac resynchronization therapy, heart transplantation may be considered to extend survival and improve quality of life.	

## 2.5. Arrhythmogenic cardiomyopathy

### 2.5.1. Introduction

Even if the presence of a cardiomyopathy involving the right ventricle (RV) usually identifies a cardiac disease called arrhythmogenic cardiomyopathy (ACM), myocardial diseases of different aetiologies may involve the RV with structural and functional abnormalities leading to the need of a differential diagnosis [145].

ACM is an inherited form of heart disease characterized by ventricular morphological and functional abnormalities and presence of ventricular arrhythmias that can even lead to SCD, especially in the young [146,147].

The ACM prevalence ranges from 1:1000 to 1:5000 [146]. The disease usually becomes clinically overt in the second-fourth decade of life and males result to be more frequently affected respect to females (up to 3:1) [146,148,149].

The ACM pathologic basis consists in myocardial ventricular atrophy followed by fibro-fatty tissue replacement; this process is progressive, starting from the epicardium and then extending to the endocardium, eventually becoming transmural [150]. The presence of fibro-fatty tissue leads both to morphological ventricular abnormalities and circuits that constitute the anatomic basis of re-entry ventricular arrhythmias.

Although in the original description the disease was characterized by an exclusive or at least predominant RV involvement, in the last years the extensive use of CMR with contrast agent injection demonstrated that left ventricle is frequently involved. For this reason, the current phenotypic classification of disease considers the presence of three variants: “right dominant”, characterized by the predominant RV involvement, with no or minor LV abnormalities; “biventricular” with a parallel involvement of the RV and LV; and the “left-dominant ACM” characterized by a predominant LV involvement, with no or minor RV abnormalities [151].

Fatty infiltration, that in original descriptions was one of the milestones of the disease histologic feature, is now not considered anymore a sufficient morphologic hallmark of the disease, as a replacement-type fibrosis and myocyte degenerative changes should always be identified [152].

The phenotypic aspects of ACM can vary in a considerable manner, ranging from asymptomatic family members with mild forms of the disease to symptomatic patients who experienced life-threatening ventricular arrhythmias or refractory heart failure [147].

The most common clinical presentation consists of arrhythmic symptoms as palpitations, syncopal episodes or cardiac arrest. Sudden death can be the first clinical manifestation of the disease in previously asymptomatic individuals, especially in the young and in competitive athletes [153,154]. Moreover, patients with ACM can show a myocarditic presentation, defined “hot phase”, characterized by chest pain, myocardial enzyme release, and ECG abnormalities with normal coronary arteries [155,156], commonly affecting paediatric patients and carriers of desmoplakin gene mutations. The prognosis in patients affected with ACM is related to the degree of electric instability and the disease extent in terms of ventricular morphological abnormalities.

Since the first description, the presence of an inheritable pattern of the disease with familial recurrence has been reported [157]. Genetic studies demonstrated that approximately 30–50% of ACM patients carry a pathogenic mutation in a desmosome gene. Mutations most often affect genes coding for desmosomal proteins: desmoplakin, placophilin-2, desmoglein-2, desmocollin-2 and plakoglobin. Moreover, approximately 10–25% of AC patients carry compound mutations and are heterozygous [158,159].









Although less frequently found, mutations in non-desmosomal genes (desmin, filamin C, transmembrane protein 43, lamin A/C, titin, phospholamban,  $\alpha$ -T-catenin, cadherin-2, transforming growth factor  $\beta$ 3, ryanodine receptor 2,  $Nav1.5$ ) also have been linked to the disease.

The diagnosis of the disease relies on the demonstration of anamnestic, clinical, morphological and electrophysiological parameters

which can be achieved from different instrumental tools as 12 lead ECG, 24 h ambulatory ECG, 2D echocardiogram and CMR [160–162]. Among these tests, CMR with contrast agent gadolinium constitutes the ideal technique to address both biventricular and left dominant variants, thanks to its tissue characterization capability that allows the detection of fibro-fatty infiltration [147,163]. Endomyocardial biopsy is reserved for selected ACM patients, in which phenocopies (dilated cardiomyopathy, myocarditis, sarcoidosis) should be excluded [161,164].

Therapeutic strategies in ACM patients include physical restriction, drug therapy (mainly beta-blockers, sotalol and amiodarone), ICD implant and catheter ablation [165]. Heart transplantation still represents the final therapeutic option for ACM patients with advanced stages of the disease who suffer refractory congestive heart failure and/or uncontrollable arrhythmic storms, despite previous attempts with catheter ablation and ICD therapy.

Recommendations for the diagnosis and management of ACM are listed below.

Recommendations for the diagnosis and management of ACM	Symbol
In children and adolescents with family history for ACM and carriers of a pathogenic/likely pathogenic variant, regular annual follow-up, comprehensive of 12 lead ECG, echocardiogram and 24 h Holter monitoring are recommended.	
Genetic test (comprehensive of desmosomal gene testing/sequencing): - should be considered in patients with myocarditis and positive family history (ACM); - may be considered in patients with recurrent myocarditis.	
Restriction from competitive sports activity may be considered in phenotype-negative genotype positive children and adults and/or in case of unknown genetic test results.	
Prophylactic administration of beta blockers is not recommended in phenotype-negative children and adults carrying a pathogenic/likely pathogenic variant for ACM.	
In patients with ACM and premature ventricular complexes/nonsustained VT, beta blockers titrated to the maximum tolerated dose are recommended.	
In individuals with phospholamban cardiomyopathy, and LVEF less than 45% or evidence of nonsustained VT, an ICD is reasonable.	
In individuals with lamin A/C ACM and two or more risk factors among LVEF <45%, NSVT and male sex, an ICD with pacing capabilities should be considered.	
In individuals with FLNC ACM and an LVEF <45%, an ICD should be considered.	

### 2.5.2. Paediatric age

As previously reported, ACM becomes clinically overt in the second-fourth decade of life. Nonetheless, the disease can be rarely diagnosed before puberty. However, once diagnosed, clinical characteristics and outcomes are similar between paediatric and adult patients. Paediatric relatives of patients with AC should enter a follow-up program with cardiological evaluation including ECG, echocardiogram 24-h Holter ECG and possibly CMR in order to highlight morpho-structural abnormalities otherwise unrecognized [166,167].

### 2.5.3. Cardio-cutaneous syndromes

Arrhythmogenic cardiomyopathy can be rarely a part a syndromic condition with presence of cutaneous phenotypes of woolly hair and palmoplantar.

Naxos syndrome is characterized by the association of ACM with palmoplantar keratoderma and woolly hair [168]. Differently from isolated ACM, Naxos syndrome is inherited in an autosomal recessive manner with full penetrance and deletion in desmosomal gene plakoglobin has been identified as the underlying genetic cause [157].

Carvajal syndrome is a similar medical condition syndrome characterized by keratoderma, woolly hair, and ACM with LV predominance in

which genetic studies demonstrated the presence of homozygous mutations in desmoplakin [169].



### 2.5.4. Cardiac sarcoidosis

Sarcoidosis is a granulomatous disease in which the pathological hallmark is represented by noncaseating granulomas. The pathogenesis remains largely unknown, it is speculated that the disease may be an immunological response to an unidentified antigenic trigger. Even if pulmonary involvement is the most common site of the disease, sarcoidosis may also involve the heart as well as other organs [170]. Its incidence is variable depending on the ethnicity considered, 11/100000 in white people, while in Afro-Caribbean it increases up to 36/100000. The disease typically has an onset between 25 and 45 years. Cardiac involvement is rare and estimated to be present in 5% of patients with pulmonary/systemic form [171]. When this occurs, clinical manifestations are varied and related to the extent of the disease and may include conduction system defects, ventricular arrhythmias, and heart failure [172]. The differential diagnosis between cardiac sarcoidosis and ACM is often challenging due to both clinical and imaging features common to the two entities. CMR represents a fundamental tool in the diagnosis of cardiac sarcoidosis [171,172]. The septum and the LV free wall are the most common locations at the LV level, while the RV free wall is involved in up to 40% of cases [173]. Nevertheless, some peculiar features distinguish sarcoidosis from ACM, and this can help the diagnostic assessment. First, differently from ACM, conduction delays are frequent because of the granulomatous infiltration of the interventricular septum. At post-contrast sequences, LGE shows an intramural or patchy appearance, localizes mostly at the basal lateral wall. In unclear cases, 18F-Fluorodeoxyglucose (FDG) - PET is a helpful examination as it allows to visualize the sites of active inflammation, both in the heart and in the other thoracic regions [174]. However, the only examination that allows a diagnosis of certainty is the biopsy [175,176]. Typically, this is performed at the level of hilar lymph nodes for the favourable risk-benefit ratio. In presence of an isolated cardiac involvement, endomyocardial biopsy may be required taking into account that sarcoidosis is a focal disease, and therefore it may not be properly sampled [171]. There are no validated clinical guidelines for the diagnosis of cardiac sarcoidosis (CS). The Heart Rhythm Society (HRS) 2014 statement and the Japanese Cardiology Society (JCS) updated in 2019 are the two currently used diagnostic criteria sets and are summarized in Supplemental Table 8.

CS can mimic other disease, such as ACM, myocarditis, non-ischaemic DCM, HCM. Supplemental Fig. 5 and Supplemental Fig. 6 summarize the diagnostic pathway for detection of CS in patients with known systemic sarcoidosis and in patients with unexplained cardiac involvement, respectively.

















Being the disease relatively rare, there are only few randomized controlled studies (RCTs) about treatment options, which are therefore based on individual patient characteristics and Centre experience. A multidisciplinary team approach in diagnosis and management of CS is mandatory, with the integration of information provided by clinical characteristics, laboratory tests, and instrumental diagnostic techniques (Supplemental Figs. 7 and Supplemental Fig. 8). The European Respiratory Society (ERS) has recently updated the clinical guidelines on treatment of sarcoidosis, with specific recommendations on CS [177].

Recommendations for the diagnosis and management of CS are listed below.

Recommendations for the diagnosis of cardiac sarcoidosis	
In patients <60 years with unexplained high-degree AV block, sustained VT, or unexplained reduced LVEF (≤ 40%), screening for cardiac sarcoidosis should be considered.	
ACE dosing, chest CT and 18-FDG PET scan are recommended in patients with clinically suspected cardiac sarcoidosis	

(continued on next column)

(continued)

Recommendations for the diagnosis of cardiac sarcoidosis	
EMB should be considered for diagnostic confirmation in patients with clinical suspicion of cardiac sarcoidosis.	
A complete cardiovascular assessment, including a comprehensive clinical history, physical examination, 12-lead ECG, transthoracic echocardiogram and 24 h Holter monitoring is recommended for patients with biopsy proven extracardiac sarcoidosis.	
CMR should be performed in patients with cardiac sarcoidosis and systolic dysfunction, for the purposes of SCD stratification and tissue characterization.	
Electrophysiological study (EPS) may be performed in patients with cardiac sarcoidosis, monomorphic ventricular arrhythmias and moderate systolic dysfunction.	
18FDG-PET scan may be repeated after 3 months of immunosuppressive therapy in order to guide further management and repeated at regular intervals, until relapse is obtained.	
Recommendations for the management of cardiac sarcoidosis Immunosuppression (with steroids or steroid-sparing drugs) should be considered in patients with evidence of active cardiac sarcoidosis.	
In patients with cardiac sarcoidosis and permanent or high-degree AV block, implantation of a device capable of cardiac pacing is recommended.	
In patients with cardiac sarcoidosis and ventricular arrhythmias, antiarrhythmic drug therapy should be considered on the top of optimal immunosuppressive therapy.	
In patients with cardiac sarcoidosis and monomorphic ventricular arrhythmias refractory to immunosuppressive plus antiarrhythmic drugs, catheter ablation may be considered.	
ICD implantation is recommended in patients with cardiac sarcoidosis and spontaneous sustained ventricular arrhythmias causing hemodynamic instability, including prior cardiac arrest.	
ICD implantation should be considered in patients with cardiac sarcoidosis and LVEF ≤35% despite optimal medical therapy.	
ICD implantation may be considered in patients with cardiac sarcoidosis and one risk factor, irrespective of LVEF, among: 1. arrhythmic syncope; 2. positive EPS documenting inducible VA; 3. Extended cardiac fibrosis at CMR.	
In patients with sarcoidosis and indication for permanent pacing who have LVEF <50%, implantation of a CRT-D should be considered.	
In patients with cardiac sarcoidosis and active inflammation after a period of immunosuppression therapy, ICD implantation may be considered if presence of right ventricular systolic dysfunction.	
In patients undergoing VT ablation, subsequent ICD implantation should be considered.	
ICD implantation is not recommended in patients with no history of syncope, normal LVEF/RV ejection fraction, no LGE on CMR, a negative EP study, and no indication for permanent pacing. ICD implantation is not recommended in patients with one or more of the following: 1. Incessant ventricular arrhythmias; 2. Severe New York Heart Association class IV heart failure.	

### 3. Conclusions

Rare cardiomyopathies and specific aetiologies may present in complex clinical syndromes, such as heart failure with reduced or preserved ejection fraction, LVH, aortic stenosis or arrhythmic events, ventricular arrhythmias and atrioventricular blocks, both in adult and paediatric patients. A high index of clinical suspicion is required for diagnosis. General cardiologists and paediatric cardiologists should be aware of cardiac and extracardiac red flags, which may provide clues to

reach a definitive diagnosis. Nevertheless, a step-by-step clinical evaluation is required to reach etiological diagnosis, not limiting to phenotypic definition, in order to direct disease-specific treatment strategies.

### Authors' contributions

Camillo Autore, Giuseppe Limongelli and Francesco Pelliccia conceived and ideated the manuscript and provided the endorsement of the SIC Working Group for Myocardial and pericardial diseases. Cristina Basso, Ciro Indolfi and Gianfranco Sinagra critically reviewed the manuscript and provided the endorsement of the Italian Society of Cardiology (SIC).

Silvia Favilli and Giuseppe Limongelli critically reviewed the manuscript and provided the endorsement of the Italian Society of Paediatric Cardiology (SICP).

Camillo Autore, Chiara Baggio, Barbara Bauce, Elena Biagini, Giuseppe Limongelli, Michele Lioncino, Marco Merlo, Emanuele Monda and Vanda Parisi drafted the manuscript and the recommendations.

Rachele Adoriso, Camillo Autore, Barbara Bauce, Elena Biagini, Silvia Favilli, Giuseppe Limongelli, Marco Merlo, Iacopo Olivotto and Francesco Pelliccia participated to the modified Delphi method to select the final recommendations. All the authors critically reviewed the manuscript and the recommendations.

### Funding

The authors have not declared a specific grant for this research from any funding agency in the public, commercial or not-for-profit sectors.

### Declaration of Competing Interest

Elena Biagini: Advisory board: Amicus, Shire Takeda, Sanofi Genzyme. Giuseppe Limongelli: Advisory board: BMS, Pfizer, Sanofi Genzyme. Marco Merlo: research grant #52524547 (Pfizer). Iacopo Olivotto: Grants: BMS, Cytokinetics, Boston Scientific, Sanofi Genzyme, Shire Takeda, Amicus, Menarini International, Bayer; Advisory Board: CMS, Amicus, Cytokinetics; Speaker's bureau: BMS, Boston Scientific, Bayer.

### Acknowledgments

None.

### Appendix A. Supplementary data

Supplementary data to this article can be found online at <https://doi.org/10.1016/j.ijcard.2022.03.050>.

### References

- [1] P. Elliott, B. Andersson, E. Arbustini, et al., Classification of the cardiomyopathies: a position statement from the European society of cardiology working group on myocardial and pericardial diseases, *Eur. Heart J.* 29 (2) (2008) 270–276, <https://doi.org/10.1093/EURHEARTJ/EHM342>.
- [2] E. Arbustini, N. Narula, G.W. Dec, et al., The MOGE(S) classification for a phenotype–genotype nomenclature of cardiomyopathy: endorsed by the World Heart Federation, *J. Am. Coll. Cardiol.* 62 (22) (2013) 2046–2072, <https://doi.org/10.1016/J.JACC.2013.08.1644>.
- [3] T.A. McDonagh, M. Metra, M. Adamo, et al., 2021 ESC guidelines for the diagnosis and treatment of acute and chronic heart failure, *Eur. Heart J.* 42 (36) (2021) 3599–3726, <https://doi.org/10.1093/EURHEARTJ/EHAB368>.
- [4] H. Heidbuchel, E. Arbelo, F. D'Ascenzi, et al., Recommendations for participation in leisure-time physical activity and competitive sports of patients with arrhythmias and potentially arrhythmogenic conditions. Part 2: ventricular arrhythmias, channelopathies, and implantable defibrillators A position statement of the section of sports cardiology and exercise from the European Association of Preventive Cardiology (EAPC) and the European heart rhythm association (EHRA), both associations of the European Society of Cardiology, *EP Eur.* 23 (1) (2021) 147–148, <https://doi.org/10.1093/EUROPEACE/EUAA106>.
- [5] M. Merlo, M. Masè, A. Cannata, et al., Management of nonischemic-dilated cardiomyopathies in clinical practice: a position paper of the working group on myocardial and pericardial diseases of Italian Society of Cardiology, *J. Cardiovasc. Med. (Hagerstown)* 21 (12) (2020) 927–943, <https://doi.org/10.2459/JCM.0000000000001050>.
- [6] M. Pieroni, J.C. Moon, E. Arbustini, et al., Cardiac involvement in Fabry disease: JACC review topic of the week, *J. Am. Coll. Cardiol.* 77 (7) (2021) 922–936, <https://doi.org/10.1016/j.jacc.2020.12.024>.
- [7] H. Yogasundaram, W. Alhumaid, T. Dzwiniel, S. Christian, G.Y. Oudit, Cardiomyopathies and genetic testing in heart failure: role in defining phenotype-targeted approaches and management, *Can. J. Cardiol.* 37 (4) (2021) 547–559, <https://doi.org/10.1016/J.CJCA.2021.01.016>.
- [8] L. Cavigli, I. Olivotto, F. Fattiolli, et al., Prescribing, Dosing and Titrating Exercise in Patients with Hypertrophic Cardiomyopathy for Prevention of Comorbidities: Ready for Prime Time, Published online June 17, 2020, <https://doi.org/10.1177/2047487320928654>.
- [9] A. Merghani, C. Monkhouse, C. Kirkby, et al., Diagnostic impact of repeated expert review & long-term follow-up in determining etiology of idiopathic cardiac arrest, *J. Am. Heart Assoc.* 10 (12) (2021), <https://doi.org/10.1161/JAHA.120.019610>.
- [10] G.N. Kowligi, Y.M. Cha, Management of ventricular electrical storm: a contemporary appraisal, *Europace.* 22 (12) (2020) 1768–1780, <https://doi.org/10.1093/EUROPEACE/EUAA232>.
- [11] F. Pelliccia, O. Alfieri, P. Calabrò, et al., Multidisciplinary evaluation and management of obstructive hypertrophic cardiomyopathy in 2020: towards the HCM heart team, *Int. J. Cardiol.* 304 (2020) 86–92, <https://doi.org/10.1016/J.IJCARD.2020.01.021>.
- [12] S.R. Ommen, S. Mital, M.A. Burke, et al., 2020 AHA/ACC guideline for the diagnosis and treatment of patients with hypertrophic cardiomyopathy, *Circulation* 20 (2020), <https://doi.org/10.1161/cir.0000000000000937>. Published online November.
- [13] A. Pelliccia, S. Sharma, S. Gati, et al., 2020 ESC guidelines on sports cardiology and exercise in patients with cardiovascular disease, *Eur. Heart J.* 42 (1) (2021) 17–96, <https://doi.org/10.1093/EURHEARTJ/EHAA605>.
- [14] J.L. Zamorano, A. Anastakis, M.A. Borger, et al., 2014 ESC guidelines on diagnosis and management of hypertrophic cardiomyopathy: the task force for the diagnosis and management of hypertrophic cardiomyopathy of the European Society of Cardiology (ESC), *Eur. Heart J.* 35 (39) (2014) 2733–2779, <https://doi.org/10.1093/eurheartj/ehu284>.
- [15] B.J. Maron, Clinical course and management of hypertrophic cardiomyopathy. Longo DL, ed, *N. Engl. J. Med.* 379 (7) (2018) 655–668, <https://doi.org/10.1056/NEJMra1710575>.
- [16] N.A. Marston, L. Han, I. Olivotto, et al., Clinical characteristics and outcomes in childhood-onset hypertrophic cardiomyopathy, *Eur. Heart J.* 26 (2021), <https://doi.org/10.1093/eurheartj/ehab148>. Published online March.
- [17] G. Norrish, E. Field, K. Mcleod, et al., Clinical presentation and survival of childhood hypertrophic cardiomyopathy: a retrospective study in United Kingdom, *Eur. Heart J.* 40 (12) (2019) 986–993, <https://doi.org/10.1093/eurheartj/ehy798>.
- [18] G. Norrish, G. Kolt, E. Cervi, et al., Clinical presentation and long-term outcomes of infantile hypertrophic cardiomyopathy: a European multicentre study, *ESC Heart Fail.* 8 (6) (2021) 5057, <https://doi.org/10.1002/EHF2.13573>.
- [19] C. Rapezzi, E. Arbustini, A.L.P. Caforio, et al., Diagnostic work-up in cardiomyopathies: bridging the gap between clinical phenotypes and final diagnosis. A position statement from the ESC working group on myocardial and pericardial diseases, *Eur. Heart J.* 34 (19) (2013) 1448–1458, <https://doi.org/10.1093/eurheartj/ehs397>.
- [20] G. Limongelli, E. Monda, S. Tramonte, et al., Prevalence and clinical significance of red flags in patients with hypertrophic cardiomyopathy, *Int. J. Cardiol.* 299 (2020) 186–191, <https://doi.org/10.1016/j.ijcard.2019.06.073>.
- [21] A.T. van der Ploeg, A.J. Reuser, Pompe's disease, *Lancet.* 372 (9646) (2008) 1342–1353, [https://doi.org/10.1016/S0140-6736\(08\)61555-X](https://doi.org/10.1016/S0140-6736(08)61555-X).
- [22] K. Hirono, F. Ichida, Glycogen storage diseases presenting as hypertrophic cardiomyopathy, *Respir. Circ.* 63 (7) (2015) 631–636, <https://doi.org/10.1056/nejmoa033349>.
- [23] C. Brunel-Guitton, A. Levtova, F. Sasarman, Mitochondrial diseases and cardiomyopathies, *Can. J. Cardiol.* 31 (11) (2015) 1360–1376, <https://doi.org/10.1016/j.cjca.2015.08.017>.
- [24] T.C.G. Vydt, R.F.M. de Co, O.I.I. Soliman, et al., Cardiac involvement in adults with m.3243A>G MELAS gene mutation, *Am. J. Cardiol.* 99 (2) (2007) 264–269, <https://doi.org/10.1016/j.amjcard.2006.07.089>.
- [25] M.G.D. Bates, J.P. Bourke, C. Giordano, G. D'Amati, D.M. Turnbull, R.W. Taylor, Cardiac involvement in mitochondrial DNA disease: clinical spectrum, diagnosis, and management, *Eur. Heart J.* 33 (24) (2012) 3023–3033, <https://doi.org/10.1093/eurheartj/ehs275>.
- [26] K. Wahbi, S. Larue, C. Jardel, et al., Cardiac involvement is frequent in patients with the m.8344A>G mutation of mitochondrial DNA, *Neurology.* 74 (8) (2010) 674–677, <https://doi.org/10.1212/WNL.0b013e3181d0ccf4>.
- [27] N. Stalder, N. Yarol, P. Tozzi, et al., Mitochondrial A3243G mutation with manifestation of acute dilated cardiomyopathy, *Circ. Heart Fail.* 5 (1) (2012), <https://doi.org/10.1161/CIRCHEARTFAILURE.111.963900>.
- [28] H. Ino, M. Tanaka, K. Ohno, et al., Mitochondrial leucine tRNA mutation in a mitochondrial encephalomyopathy, *Lancet.* 337 (8735) (1991) 234–235, [https://doi.org/10.1016/0140-6736\(91\)92196-9](https://doi.org/10.1016/0140-6736(91)92196-9).
- [29] M. Taniike, H. Fukushima, I. Yanagihara, et al., Mitochondrial tRNA<sup>Met</sup> mutation in fatal cardiomyopathy, *Biochem. Biophys. Res. Commun.* 186 (1) (1992) 47–53, [https://doi.org/10.1016/S0006-291X\(05\)80773-9](https://doi.org/10.1016/S0006-291X(05)80773-9).

- [30] M. Lioncino, E. Monda, M. Caiazza, et al., Cardiovascular involvement in mtDNA disease: diagnosis, management, and therapeutic options, *Heart Fail. Clin.* 18 (1) (2022) 51–60, <https://doi.org/10.1016/j.HFC.2021.07.003>.
- [31] A. Hahn, J. Lauriol, J. Thul, et al., Rapidly progressive hypertrophic cardiomyopathy in an infant with Noonan syndrome with multiple lentiginos: palliative treatment with a rapamycin analog, *Am. J. Med. Genet. Part A* 167 (4) (2015) 744–751, <https://doi.org/10.1002/ajmg.a.36982>.
- [32] M.E. Pierpont, M.C. Digilio, Cardiovascular disease in Noonan syndrome, *Curr. Opin. Pediatr.* 30 (5) (2018) 601–608, <https://doi.org/10.1097/MOP.0000000000000669>.
- [33] G. Calcagni, R. Adorisio, S. Martinelli, et al., Clinical presentation and natural history of hypertrophic cardiomyopathy in RASopathies, *Heart Fail. Clin.* 14 (2) (2018) 225–235, <https://doi.org/10.1016/j.hfc.2017.12.005>.
- [34] M. Lioncino, E. Monda, F. Verrillo, et al., Hypertrophic cardiomyopathy in RASopathies: diagnosis, clinical characteristics, prognostic implications, and management, *Heart Fail. Clin.* 0 (0) (2021), <https://doi.org/10.1016/J.HFC.2021.07.004>.
- [35] R. Chen, T. Tsuji, F. Ichida, et al., Mutation analysis of the G4.5 gene in patients with isolated left ventricular noncompaction, *Mol. Genet. Metab.* 77 (4) (2002) 319–325, [https://doi.org/10.1016/S1096-7192\(02\)00195-6](https://doi.org/10.1016/S1096-7192(02)00195-6).
- [36] M. Rahbek Schmidt, N. Birkebaek, I. Gonzalez, L. Sunde, Barth syndrome without 3-methylglutaconic aciduria, *Acta Paediatr. Int. J. Paediatr.* 93 (3) (2004) 419–421, <https://doi.org/10.1080/08035250410022837>.
- [37] S. Parikh, A. Goldstein, M.K. Koehnig, et al., Diagnosis and management of mitochondrial disease: a consensus statement from the mitochondrial medicine society, *Genet. Med.* 17 (9) (2015) 689–701, <https://doi.org/10.1038/gim.2014.177>.
- [38] L. Linglart, B.D. Gelb, Congenital heart defects in Noonan syndrome: diagnosis, management, and treatment, *Am. J. Med. Genet. Part C Semin. Med. Genet.* 184 (1) (2020) 73–80, <https://doi.org/10.1002/ajmg.c.31765>.
- [39] A.E. Roberts, J.E. Allanson, M. Tartaglia, B.D. Gelb, Noonan syndrome, *Lancet* 381 (9863) (2013) 333–342, [https://doi.org/10.1016/S0140-6736\(12\)61023-X](https://doi.org/10.1016/S0140-6736(12)61023-X).
- [40] G. Calcagni, G. Limongelli, A. D'Ambrosio, et al., Cardiac defects, morbidity and mortality in patients affected by RASopathies. CARNET study results, *Int. J. Cardiol.* 245 (2017) 92–98, <https://doi.org/10.1016/j.ijcard.2017.07.068>.
- [41] G. Calcagni, G. Gagliostro, G. Limongelli, et al., Atypical cardiac defects in patients with RASopathies: updated data on CARNET study, *Birth Defects Res.* 112 (10) (2020) 725–731, <https://doi.org/10.1002/bdr2.1670>.
- [42] D.M. Sproule, P. Kaufmann, K. Engelstad, T.J. Starc, A.J. Hordof, D.C. De Vivo, Wolff-Parkinson-white syndrome in patients with MELAS, *Arch. Neurol.* 64 (11) (2007) 1625–1627, <https://doi.org/10.1001/archneur.64.11.1625>.
- [43] K. Wahbi, W. Bougouin, A. Béhin, et al., Long-term cardiac prognosis and risk stratification in 260 adults presenting with mitochondrial diseases, *Eur. Heart J.* 36 (42) (2015) 2886–2893, <https://doi.org/10.1093/eurheartj/ehv307>.
- [44] R. Anan, M. Nakagawa, M. Miyata, et al., Cardiac involvement in mitochondrial diseases, *Circulation* 91 (4) (1995) 955–961, <https://doi.org/10.1161/01.CIR.91.4.955>.
- [45] K. Majamaa-Voltti, K. Peuhkurinen, M.L. Kortelainen, I.E. Hassinen, K. Majamaa, Cardiac abnormalities in patients with mitochondrial DNA mutation 3243A>G, *BMC Cardiovasc. Disord.* 2 (2002), <https://doi.org/10.1186/1471-2261-2-12>.
- [46] P. Sorajja, M.G. Sweeney, R. Chalmers, et al., Cardiac abnormalities in patients with Leber's hereditary optic neuropathy, *Heart* 89 (7) (2003) 791–792, <https://doi.org/10.1136/heart.89.7.791>.
- [47] P.C. Gillette, M.R. Nihill, D.B. Singer, Electrophysiological mechanism of the short PR interval in Pompe disease, *Am. J. Dis. Child.* 128 (5) (1974) 622–626, <https://doi.org/10.1001/archpedi.1974.02110300032005>.
- [48] A.K. Ansong, J.S. Li, E. Nozik-Grayck, et al., Electrocardiographic response to enzyme replacement therapy for Pompe disease, *Genet. Med.* 8 (5) (2006) 297–301, <https://doi.org/10.1097/01.gim.0000195896.04069.5f>.
- [49] B.H. Bulkley, G.M. Hutchins, Pompe's disease presenting as hypertrophic myocardiopathy with Wolff-Parkinson-white syndrome, *Am. Heart J.* 96 (2) (1978) 246–252, [https://doi.org/10.1016/0002-8703\(78\)90093-5](https://doi.org/10.1016/0002-8703(78)90093-5).
- [50] J.P. Kaski, P. Syrris, M.T.T. Esteban, et al., Prevalence of sarcomere protein gene mutations in preadolescent children with hypertrophic cardiomyopathy, *Circ. Cardiovasc. Genet.* 2 (5) (2009) 436–441, <https://doi.org/10.1161/CIRCGENETICS.108.821314>.
- [51] J.L. Zamorano, A. Anastasakis, M.A. Borger, et al., 2014 ESC guidelines on diagnosis and management of hypertrophic cardiomyopathy: the task force for the diagnosis and management of hypertrophic cardiomyopathy of the European Society of Cardiology (ESC), *Eur. Heart J.* 35 (39) (2014) 2733–2779, <https://doi.org/10.1093/eurheartj/ehu284>.
- [52] S.D. Colan, S.E. Lipshultz, A.M. Lowe, et al., Epidemiology and cause-specific outcome of hypertrophic cardiomyopathy in children: findings from the Pediatric cardiomyopathy registry, *Circulation* 115 (6) (2007) 773–781, <https://doi.org/10.1161/CIRCULATIONAHA.106.621185>.
- [53] S.E. Lipshultz, E.J. Orav, J.D. Wilkinson, et al., Risk stratification at diagnosis for children with hypertrophic cardiomyopathy: an analysis of data from the Pediatric cardiomyopathy registry, *Lancet* 382 (9908) (2013) 1889–1897, [https://doi.org/10.1016/S0140-6736\(13\)61685-2](https://doi.org/10.1016/S0140-6736(13)61685-2).
- [54] P.S. Kishnani, W.L. Hwu, H. Mandel, M. Nicolino, F. Yong, D. Corzo, A retrospective, multinational, multicenter study on the natural history of infantile-onset Pompe disease, *J. Pediatr.* 148 (5) (2006), <https://doi.org/10.1016/j.jpeds.2005.11.033>.
- [55] D. Boucek, J. Jirikowic, M. Taylor, Natural history of Danon disease, *Genet. Med.* 13 (6) (2011) 563–568, <https://doi.org/10.1097/GIM.0b013e31820ad795>.
- [56] D. Lotan, J. Salazar-Mendiguchía, J. Mogensen, et al., Clinical profile of cardiac involvement in Danon disease: a multicenter European registry, *Circ. Genomic Precis. Med.* 13 (6) (2020) 660–670, <https://doi.org/10.1161/CIRCGEN.120.003117>.
- [57] C.P. Sentner, I.J. Hoogeveen, D.A. Weinstein, et al., Glycogen storage disease type III: diagnosis, genotype, management, clinical course and outcome, *J. Inher. Metab. Dis.* 39 (5) (2016) 697–704, <https://doi.org/10.1007/s10545-016-9932-2>.
- [58] A.G. Porto, F. Brun, G.M. Severini, et al., Clinical spectrum of PRKAG2 syndrome, *Circ. Arrhythm. Electrophysiol.* 9 (1) (2016), <https://doi.org/10.1161/CIRCEP.115.003121>.
- [59] M. Rubino, E. Monda, M. Lioncino, et al., Diagnosis and management of cardiovascular involvement in Fabry disease, *Heart Fail. Clin.* 18 (1) (2022) 39–49, <https://doi.org/10.1016/J.HFC.2021.07.005>.
- [60] K. Hirono, F. Ichida, Glycogen storage diseases presenting as hypertrophic cardiomyopathy, *Respir. Circ.* 63 (7) (2015) 631–636, <https://doi.org/10.1056/nejmoa033349>.
- [61] J.N. Koneru, M.A. Wood, K.A. Ellenbogen, Rare forms of preexcitation a case study and brief overview of familial forms of preexcitation, *Circ. Arrhythm. Electrophysiol.* 5 (4) (2012), <https://doi.org/10.1161/CIRCEP.111.968917>.
- [62] A. Dürr, M. Cossee, Y. Agid, et al., Clinical and genetic abnormalities in patients with Friedreich's ataxia, *N. Engl. J. Med.* 335 (16) (1996) 1169–1175, <https://doi.org/10.1056/nejm199610173351601>.
- [63] E. Monda, M. Lioncino, M. Rubino, et al., Diagnosis and management of cardiovascular involvement in Friedreich ataxia, *Heart Fail. Clin.* 18 (1) (2022) 31–37, <https://doi.org/10.1016/J.HFC.2021.07.001>.
- [64] G. Norrish, T. Rance, E. Montanes, et al., Friedreich's ataxia-associated childhood hypertrophic cardiomyopathy: a national cohort study, *Arch. Dis. Child.* (2021), <https://doi.org/10.1136/ARCHDISCHILD-2021-322455>. Published online October 5. <https://doi.org/10.1136/ARCHDISCHILD-2021-322455>.
- [65] E. Monda, M. Lioncino, G. Palmiero, et al., Bisoprolol for treatment of symptomatic patients with obstructive hypertrophic cardiomyopathy. The BASIC (bisoprolol AS therapy in hypertrophic cardiomyopathy) study, *Int. J. Cardiol.* (2022), <https://doi.org/10.1016/J.IJCARD.2022.03.013>. Published online March.
- [66] M. Lioncino, E. Monda, G. Palmiero, et al., Cardiovascular involvement in transthyretin cardiac amyloidosis, *Heart Fail. Clin.* 18 (1) (2022) 73–87, <https://doi.org/10.1016/J.HFC.2021.07.006>.
- [67] M. Tanskanen, T. Peuralinna, T. Polvikoski, et al., Senile systemic amyloidosis affects 25% of the very aged and associates with genetic variation in alpha2-macroglobulin and tau: a population-based autopsy study, *Ann. Med.* 40 (3) (2008) 232–239, <https://doi.org/10.1080/07853890701842988>.
- [68] J.D. Gillmore, M.S. Maurer, R.H. Falk, et al., Nonbiopsy diagnosis of cardiac transthyretin amyloidosis, *Circulation* 133 (24) (2016) 2404–2412, <https://doi.org/10.1161/CIRCULATIONAHA.116.021612>.
- [69] A. Castano, M. Haq, D.L. Narotsky, et al., Multicenter study of planar technetium 99m pyrophosphate cardiac imaging: predicting survival for patients with ATTR cardiac amyloidosis, *JAMA Cardiol.* 1 (8) (2016) 880–889, <https://doi.org/10.1001/jamacardio.2016.2839>.
- [70] A. Castano, D.L. Narotsky, N. Hamid, et al., Unveiling transthyretin cardiac amyloidosis and its predictors among elderly patients with severe aortic stenosis undergoing transcatheter aortic valve replacement, *Eur. Heart J.* 38 (38) (2017) 2879–2887, <https://doi.org/10.1093/eurheartj/ehx350>.
- [71] E. González-López, M. Gallego-Delgado, G. Guzzo-Merello, et al., Wild-type transthyretin amyloidosis as a cause of heart failure with preserved ejection fraction, *Eur. Heart J.* 36 (38) (2015) 2585–2594, <https://doi.org/10.1093/eurheartj/ehv338>.
- [72] H. Rosenblum, A. Masri, D.L. Narotsky, et al., Unveiling outcomes in coexisting severe aortic stenosis and transthyretin cardiac amyloidosis, *Eur. J. Heart Fail.* (2020), <https://doi.org/10.1002/ehfj.1974>. Published online.
- [73] T. Damy, B. Costes, A.A. Hagège, et al., Prevalence and clinical phenotype of hereditary transthyretin amyloid cardiomyopathy in patients with increased left ventricular wall thickness, *Eur. Heart J.* 37 (23) (2016) 1826–1834, <https://doi.org/10.1093/eurheartj/ehv583>.
- [74] C. Chimenti, M. Pieroni, E. Morgante, et al., Prevalence of Fabry disease in female patients with late-onset hypertrophic cardiomyopathy, *Circulation* 110 (9) (2004) 1047–1053, <https://doi.org/10.1161/01.CIR.0000139847.74101.03>.
- [75] B. Sachdev, T. Takenaka, H. Teraguchi, et al., Prevalence of Anderson-Fabry disease in male patients with late onset hypertrophic cardiomyopathy, *Circulation* 105 (12) (2002) 1407–1411, <https://doi.org/10.1161/01.CIR.0000012626.81324.38>.
- [76] H. Sulaiman, E. Finegan, A. Rakovac Tisdall, R. Murphy, 66 Prevalence of fabry disease among patients diagnosed hypertrophic cardiomyopathy and unexplained left ventricular hypertrophy in St. James Hospital (2013–2015), *Heart* 102 (2016), <https://doi.org/10.1136/heartjnl-2016-310523.66>. *BMJ*. A34.3-A35.
- [77] M.M. Kittleson, M.S. Maurer, A.V. Ambardekar, et al., Cardiac amyloidosis: evolving diagnosis and management: a scientific statement from the American Heart Association, *Circulation* 142 (1) (2020) E7–E22, <https://doi.org/10.1161/CIR.0000000000000792>.
- [78] M. Boldrini, F. Cappelli, L. Chacko, et al., Multiparametric echocardiography scores for the diagnosis of cardiac amyloidosis, *JACC Cardiovasc. Imaging* 13 (4) (2020) 909–920, <https://doi.org/10.1016/j.jcmg.2019.10.011>.
- [79] J.B. Augusto, S. Nordin, R. Vijapurapu, et al., Myocardial edema, myocyte injury, and disease severity in Fabry disease, *Circ. Cardiovasc. Imaging* 13 (3) (2020), <https://doi.org/10.1161/CIRCMAGING.119.010171>.

- [80] J.B. Augusto, N. Johner, D. Shah, et al., The myocardial phenotype of Fabry disease pre-hypertrophy and pre-detectable storage, *Eur. Heart J.* 8 (2020), <https://doi.org/10.1093/ehjci/jeaa101>. Published online June.
- [81] K.D. Knott, J.B. Augusto, S. Nordin, et al., Quantitative myocardial perfusion in Fabry disease, *Circ. Cardiovasc. Imaging* 12 (7) (2019), <https://doi.org/10.1161/CIRCIMAGING.119.008872>.
- [82] S. Mathur, J.G. Dreisbach, G.R. Karur, et al., Loss of base-to-apex circumferential strain gradient assessed by cardiovascular magnetic resonance in Fabry disease: relationship to T1 mapping, late gadolinium enhancement and hypertrophy, *J. Cardiovasc. Magn. Reson.* 21 (1) (2019), <https://doi.org/10.1186/s12968-019-0557-0>.
- [83] A.M. Maceira, J. Joshi, S.K. Prasad, et al., Cardiovascular magnetic resonance in cardiac amyloidosis, *Circulation* 111 (2) (2005) 186–193, <https://doi.org/10.1161/01.CIR.0000152819.97857.9D>.
- [84] H. Vogelsberg, H. Mahrholdt, C.C. Deluigi, et al., Cardiovascular magnetic resonance in clinically suspected cardiac amyloidosis. Noninvasive imaging compared to endomyocardial biopsy, *J. Am. Coll. Cardiol.* 51 (10) (2008) 1022–1030, <https://doi.org/10.1016/j.jacc.2007.10.049>.
- [85] A. Martinez-Naharro, T. Kotecha, K. Norrington, et al., Native T1 and extracellular volume in transthyretin amyloidosis, *JACC Cardiovasc. Imaging* 12 (5) (2019) 810–819, <https://doi.org/10.1016/j.jcmg.2018.02.006>.
- [86] G. Palmiero, E. Vetrano, M. Rubino, et al., The role of new imaging technologies in the diagnosis of cardiac amyloidosis, *Heart Fail. Clin.* 18 (1) (2022) 61–72, <https://doi.org/10.1016/J.HFC.2021.07.014>.
- [87] E. Monda, G. Palmiero, M. Lioncino, et al., External validation of the increased wall thickness score for the diagnosis of cardiac amyloidosis, *Int. J. Cardiol.* 339 (2021) 99–101, <https://doi.org/10.1016/J.IJCARD.2021.07.035>.
- [88] E. Monda, G. Palmiero, M. Lioncino, et al., Multimodality imaging in cardiomyopathies with hypertrophic phenotypes, *J. Clin. Med.* 11 (3) (2022) 868, <https://doi.org/10.3390/JCM11030868>.
- [89] D.P. Germain, Fabry disease, *Orphanet J. Rare Dis.* 5 (2010) 1, <https://doi.org/10.1186/1750-1172-5-30>.
- [90] A. Ortiz, D.P. Germain, R.J. Desnick, et al., Fabry disease revisited: management and treatment recommendations for adult patients, *Mol. Genet. Metab.* 123 (4) (2018) 416–427, <https://doi.org/10.1016/j.ymgme.2018.02.014>.
- [91] J.A. Towbin, A.M. Lowe, S.D. Colan, et al., Incidence, causes, and outcomes of dilated cardiomyopathy in children, *JAMA* 296 (15) (2006) 1867–1876, <https://doi.org/10.1001/JAMA.296.15.1867>.
- [92] T.A. Manolio, K.L. Baughman, R. Rodeheffer, et al., Prevalence and etiology of idiopathic dilated cardiomyopathy (summary of a National Heart, Lung, and Blood Institute workshop), *Am. J. Cardiol.* 69 (17) (1992) 1458–1466, [https://doi.org/10.1016/0002-9149\(92\)90901-A](https://doi.org/10.1016/0002-9149(92)90901-A).
- [93] M. Merlo, A. Cannata, M. Gobbo, D. Stolfo, P.M. Elliott, G. Sinagra, Evolving concepts in dilated cardiomyopathy, *Eur. J. Heart Fail.* 20 (2) (2018) 228–239, <https://doi.org/10.1002/EJHF.1103>.
- [94] I. Puggia, M. Merlo, G. Barbatì, et al., Natural history of dilated cardiomyopathy in children, *J. Am. Heart Assoc.* 5 (7) (2016), <https://doi.org/10.1161/JAHA.116.003450>.
- [95] S. Choudhry, K. Puri, S.W. Denfield, An update on pediatric cardiomyopathy, *Curr. Treat Options Cardiovasc. Med.* 21 (8) (2019), <https://doi.org/10.1007/S11936-019-0739-Y>.
- [96] J.W. Rossano, W.S. Cherikh, D.C. Chambers, et al., The Registry of the International Society for Heart and Lung Transplantation: Twentieth Pediatric Heart Transplantation report-2017; Focus Theme: Allograft Ischemic Time, Published online, 2017, <https://doi.org/10.1016/j.healun.2017.07.018>.
- [97] K. Norozi, A. Wessel, V. Alpers, et al., Incidence and risk distribution of heart failure in adolescents and adults with congenital heart disease after cardiac surgery, *Am. J. Cardiol.* 97 (8) (2006) 1238–1243, <https://doi.org/10.1016/j.amjcard.2005.10.065>.
- [98] M. Moretti, M. Merlo, G. Barbatì, et al., Prognostic impact of familial screening in dilated cardiomyopathy, *Eur. J. Heart Fail.* 12 (9) (2010) 922–927, <https://doi.org/10.1093/EURJHF/HFQ093>.
- [99] R.K. Singh, C.E. Canter, L. Shi, et al., Survival without cardiac transplantation among children with dilated cardiomyopathy, *J. Am. Coll. Cardiol.* 70 (21) (2017) 2663–2673, <https://doi.org/10.1016/J.JACC.2017.09.1089>.
- [100] M.D. Patel, J. Mohan, C. Schneider, et al., Pediatric and adult dilated cardiomyopathy represent distinct pathological entities, *JCI Insight* 2 (14) (2017), <https://doi.org/10.1172/JCI.INSIGHT.94382>.
- [101] D.S. Herman, L. Lam, M.R.G. Taylor, et al., Truncations of titin causing dilated cardiomyopathy, *N. Engl. J. Med.* 366 (7) (2012) 619–628, <https://doi.org/10.1056/NEJM0A1110186>.
- [102] J.A. Jansweijer, K. Nieuwhof, F. Russo, et al., Truncating titin mutations are associated with a mild and treatable form of dilated cardiomyopathy, *Eur. J. Heart Fail.* 19 (4) (2017) 512–521, <https://doi.org/10.1002/EJHF.673>.
- [103] U. Tayal, S. Newsome, R. Buchan, et al., Phenotype and clinical outcomes of titin cardiomyopathy, *J. Am. Coll. Cardiol.* 70 (18) (2017) 2264–2274, <https://doi.org/10.1016/J.JACC.2017.08.063>.
- [104] T.M. Lee, D.T. Hsu, P. Kantor, et al., Pediatric cardiomyopathies, *Circ. Res.* 121 (7) (2017) 855–873, <https://doi.org/10.1161/CIRCRESAHA.116.309386>.
- [105] B. Feingold, W.T. Mahle, S. Auerbach, et al., Management of cardiac involvement associated with neuromuscular diseases: a scientific statement from the American Heart Association, *Circulation* 136 (13) (2017) e200–e231, <https://doi.org/10.1161/CIR.0000000000000526>.
- [106] A.W. El-Hattab, F. Scaglia, Mitochondrial cardiomyopathies, *Front. Cardiovasc. Med.* 3 (2016) 25, <https://doi.org/10.3389/fcvm.2016.00025>.
- [107] J.A. Brothers, M.A. Frommelt, R.D.B. Jaquiss, R.J. Myerburg, C.D. Fraser, J. S. Tweddell, Expert consensus guidelines: anomalous aortic origin of a coronary artery, *J. Thorac. Cardiovasc. Surg.* 153 (6) (2017) 1440–1457, <https://doi.org/10.1016/J.JTCVS.2016.06.066>.
- [108] G. Sinagra, M. Anzini, N.L. Pereira, et al., Myocarditis in clinical practice, *Mayo Clin. Proc.* 91 (9) (2016) 1256–1266, <https://doi.org/10.1016/J.MAYOCP.2016.05.013>.
- [109] S.E. Lipshultz, Y.M. Law, A. Asante-Korang, et al., Cardiomyopathy in children: classification and diagnosis: a scientific statement from the American Heart Association, *Circulation* 140 (1) (2019) E9–E68, <https://doi.org/10.1161/CIR.0000000000000682>.
- [110] M. Caiazza, M. Lioncino, E. Monda, et al., Troponin T mutation as a cause of left ventricular systolic dysfunction in a young patient with previous surgical correction of aortic coarctation, *Biomolecules* 11 (5) (2021), <https://doi.org/10.3390/Biom11050696>.
- [111] M.R. Hazebroek, S. Moors, R. Dennert, et al., Prognostic relevance of gene-environment interactions in patients with dilated cardiomyopathy: applying the MOGE(S) classification, *J. Am. Coll. Cardiol.* 66 (12) (2015) 1313–1323, <https://doi.org/10.1016/J.JACC.2015.07.023>.
- [112] R.E. Hershberger, J. Lindenfeld, L. Mestroni, C.E. Seidman, M.R.G. Taylor, J. A. Towbin, Genetic evaluation of cardiomyopathy—a Heart Failure Society of America practice guideline, *J. Card. Fail.* 15 (2) (2009) 83–97, <https://doi.org/10.1016/J.CARDFAIL.2009.01.006>.
- [113] E.D. Smith, N.K. Lakdawala, N. Papoutsidakis, et al., Desmoplakin cardiomyopathy, a fibrotic and inflammatory form of cardiomyopathy distinct from typical dilated or Arrhythmogenic right ventricular cardiomyopathy, *Circulation* 141 (23) (2020) 1872–1884, <https://doi.org/10.1161/CIRCULATIONAHA.119.044934>.
- [114] R. Alley, J.D. Grizzard, K. Rao, R. Markley, C.R. Trankle, Inflammatory episodes of Desmoplakin cardiomyopathy masquerading as myocarditis: unique features on cardiac magnetic resonance imaging, *JACC Cardiovasc. Imaging* 14 (7) (2021) 1466–1469, <https://doi.org/10.1016/J.JCMG.2020.07.028>.
- [115] M.F. Ortiz-Genga, S. Cuenca, M. Dal Ferro, et al., Truncating FLNC mutations are associated with high-risk dilated and Arrhythmogenic cardiomyopathies, *J. Am. Coll. Cardiol.* 68 (22) (2016) 2440–2451, <https://doi.org/10.1016/J.JACC.2016.09.927>.
- [116] M. Gigli, M. Merlo, S.L. Graw, et al., Genetic risk of arrhythmic phenotypes in patients with dilated cardiomyopathy, *J. Am. Coll. Cardiol.* 74 (11) (2019) 1480–1490, <https://doi.org/10.1016/J.JACC.2019.06.072>.
- [117] A. Paldino, G. De Angelis, M. Merlo, et al., Genetics of dilated cardiomyopathy: clinical implications, *Curr. Cardiol. Rep.* 20 (10) (2018), <https://doi.org/10.1007/S11886-018-1030-7>.
- [118] L. Maggi, N. Carboni, P. Bernasconi, Skeletal muscle laminopathies: a review of clinical and molecular features, *Cells* 5 (3) (2016) 33, <https://doi.org/10.3390/CELLS5030033>.
- [119] M. Pasotti, C. Klersy, A. Pilotto, et al., Long-term outcome and risk stratification in dilated cardiomyopathies, *J. Am. Coll. Cardiol.* 52 (15) (2008) 1250–1260, <https://doi.org/10.1016/J.JACC.2008.06.044>.
- [120] I.A.W. van Rijsingen, E.A. Nannenberg, E. Arbustini, et al., Gender-specific differences in major cardiac events and mortality in lamin A/C mutation carriers, *Eur. J. Heart Fail.* 15 (4) (2013) 376–384, <https://doi.org/10.1093/EURJHF/HFS191>.
- [121] T.E. Verstraelen, F.H.M. Van Lint, L.P. Bosman, et al., Prediction of ventricular arrhythmia in phospholamban p.Arg14del mutation carriers—reaching the frontiers of individual risk prediction, *Eur. Heart J.* 42 (29) (2021) 2842–2850, <https://doi.org/10.1093/EURHEARTJ/EHAB294>.
- [122] M. Merlo, M. Anzini, R. Bussani, et al., Characterization and long-term prognosis of postmyocarditic dilated cardiomyopathy compared with idiopathic dilated cardiomyopathy, *Am. J. Cardiol.* 118 (6) (2016) 895–900, <https://doi.org/10.1016/J.AMJCARD.2016.05.063>.
- [123] M. Merlo, E. Ammirati, P. Gentile, et al., Persistent left ventricular dysfunction after acute lymphocytic myocarditis: frequency and predictors, *PLoS One* 14 (3) (2019), <https://doi.org/10.1371/JOURNAL.PONE.0214616>.
- [124] E. Arbustini, N. Narula, L. Giuliani, A. Di Toro, Genetic basis of myocarditis: myth or reality? *Myocarditis* (2020) 45–89, [https://doi.org/10.1007/978-3-030-35276-9\\_4](https://doi.org/10.1007/978-3-030-35276-9_4).
- [125] A. Cannata, J. Artico, P. Gentile, M. Merlo, G. Sinagra, Myocarditis evolving in cardiomyopathy: when genetics and offending causes work together, *Eur. Heart J. Suppl.* 21 (Suppl B) (2019) B90, <https://doi.org/10.1093/EURHEARTJ/SUZ033>.
- [126] A.L.P. Caforio, S. Pankuweit, E. Arbustini, et al., Current state of knowledge on aetiology, diagnosis, management, and therapy of myocarditis: a position statement of the European Society of Cardiology Working Group on myocardial and pericardial diseases, *Eur. Heart J.* (2013), <https://doi.org/10.1093/eurheartj/eh210>. Published online.
- [127] M.B. Davis, Z. Arany, D.M. McNamara, S. Golland, U. Elkayam, Peripartum cardiomyopathy: JACC state-of-the-art review, *J. Am. Coll. Cardiol.* 75 (2) (2020) 207–221, <https://doi.org/10.1016/J.JACC.2019.11.014>.
- [128] J.S. Ware, J. Li, E. Mazaika, et al., Shared genetic predisposition in Peripartum and dilated cardiomyopathies, *N. Engl. J. Med.* 374 (3) (2016) 233–241, [https://doi.org/10.1056/NEJM0A1505517/SUPPL\\_FILE/NEJM0A1505517\\_DISCLOSURES.PDF](https://doi.org/10.1056/NEJM0A1505517/SUPPL_FILE/NEJM0A1505517_DISCLOSURES.PDF).
- [129] D.T. Kremastinos, D. Farmakis, Iron overload cardiomyopathy in clinical practice, *Circulation* 124 (20) (2011) 2253–2263, <https://doi.org/10.1161/CIRCULATIONAHA.111.050773>.
- [130] A. Spezzacatene, G. Sinagra, M. Merlo, et al., Arrhythmogenic phenotype in dilated cardiomyopathy: natural history and predictors of life-threatening



- arrhythmias, *J. Am. Heart Assoc.* (2015), <https://doi.org/10.1161/JAHA.115.002149>. Published online.
- [131] J.P. Kaski, P. Syrris, M. Burch, et al., Idiopathic restrictive cardiomyopathy in children is caused by mutations in cardiac sarcomere protein genes, *Heart*. 94 (11) (2008) 1478–1484, <https://doi.org/10.1136/HRT.2007.134684>.
- [132] J. Mogensen, T. Kubo, M. Duque, et al., Idiopathic restrictive cardiomyopathy is part of the clinical expression of cardiac troponin I mutations, *J. Clin. Invest.* 111 (2) (2003) 209–216, <https://doi.org/10.1172/JCI16336>.
- [133] T.S. Rai, S. Ahmad, T.S. Ahluwalia, et al., Genetic and clinical profile of Indian patients of idiopathic restrictive cardiomyopathy with and without hypertrophy, *Mol. Cell. Biochem.* 331 (1–2) (2009) 187–192. Accessed November 27, 2021, [https://www.academia.edu/1388785/Genetic\\_and\\_clinical\\_profile\\_of\\_Indian\\_patient\\_s\\_of\\_idiopathic\\_restrictive\\_cardiomyopathy\\_with\\_and\\_without\\_hypertrophy](https://www.academia.edu/1388785/Genetic_and_clinical_profile_of_Indian_patient_s_of_idiopathic_restrictive_cardiomyopathy_with_and_without_hypertrophy).
- [134] E. Arbustini, M. Pasotti, A. Pilotto, et al., Desmin accumulation restrictive cardiomyopathy and atrioventricular block associated with desmin gene defects, *Eur. J. Heart Fail.* 8 (5) (2006) 477–483, <https://doi.org/10.1016/J.EJHEART.2005.11.003>.
- [135] K. Wahbi, A. Béhin, P. Charron, et al., High cardiovascular morbidity and mortality in myofibrillar myopathies due to DES gene mutations: a 10-year longitudinal study, *Neuromuscul. Disord.* 22 (3) (2012) 211–218, <https://doi.org/10.1016/J.NMD.2011.10.019>.
- [136] J. Zhang, A. Kumar, H.J. Stalker, et al., Clinical and molecular studies of a large family with desmin-associated restrictive cardiomyopathy, *Clin. Genet.* 59 (4) (2001) 248–256, <https://doi.org/10.1034/J.1399-0004.2001.590406.X>.
- [137] A. Brodehl, R.A. Ferrier, S.J. Hamilton, et al., Mutations in FLNC are associated with familial restrictive cardiomyopathy, *Hum. Mutat.* 37 (3) (2016) 269–279, <https://doi.org/10.1002/HUMU.22942>.
- [138] A.R. Duraes, de Souza Lima Bitar Y, Roeber L, Neto MG., Endomyocardial fibrosis: past, present, and future, *Heart Fail. Rev.* 25 (5) (2020) 725–730, <https://doi.org/10.1007/S10741-019-09848-4>.
- [139] N.L. Pereira, M. Grogan, G.W. Dec, Spectrum of restrictive and infiltrative cardiomyopathies: part 2 of a 2-part series, *J. Am. Coll. Cardiol.* 71 (10) (2018) 1149–1166, <https://doi.org/10.1016/J.JACC.2018.01.017>.
- [140] S.M. Rivenes, D.L. Kearney, E.O.B. Smith, J.A. Towbin, S.W. Denfield, Sudden death and cardiovascular collapse in children with restrictive cardiomyopathy, *Circulation* (2000), <https://doi.org/10.1161/01.CIR.102.8.876>. Published online.
- [141] M.A. Walsh, M.A. Grenier, J.L. Jefferies, J.A. Towbin, A. Lorts, R.J. Czossek, Conduction abnormalities in pediatric patients with restrictive cardiomyopathy, *Circ. Heart Fail.* 5 (2) (2012) 267–273, <https://doi.org/10.1161/CIRCHEARTFAILURE.111.964395>.
- [142] P. Liu, N. Olivieri, Iron overload cardiomyopathies: new insights into an old disease, *Cardiovasc. Drugs Ther.* 8 (1) (1994) 101–110, <https://doi.org/10.1007/BF00877096>.
- [143] C. Díez-López, J. Comín-Colet, J. González-Costello, Iron overload cardiomyopathy: from diagnosis to management, *Curr. Opin. Cardiol.* 33 (3) (2018) 334–340, <https://doi.org/10.1097/HCO.0000000000000511>.
- [144] C.J. Murphy, G.Y. Oudit, Iron-overload cardiomyopathy: pathophysiology, diagnosis, and treatment, *J. Card. Fail.* 16 (11) (2010) 888–900, <https://doi.org/10.1016/J.CARDFAIL.2010.05.009>.
- [145] S.P. Gaine, R. Naeije, A.J. Peacock, The right heart, *Right Heart* 9781447123989 (2014) 1–323, <https://doi.org/10.1007/978-1-4471-2398-9>.
- [146] G. Thiene, A. Nava, D. Corrado, L. Rossi, N. Pennelli, Right ventricular cardiomyopathy and sudden death in young people, *N. Engl. J. Med.* 318 (3) (1988) 129–133, <https://doi.org/10.1056/NEJM198801213180301>.
- [147] D. Corrado, C. Basso, D.P. Judge, Arrhythmogenic cardiomyopathy, *Circ. Res.* 121 (7) (2017) 785–802, <https://doi.org/10.1161/CIRCRESAHA.117.309345/-/DC1>.
- [148] A. Nava, B. Bauce, C. Basso, et al., Clinical profile and long-term follow-up of 37 families with arrhythmogenic right ventricular cardiomyopathy, *J. Am. Coll. Cardiol.* 36 (7) (2000) 2226–2233, [https://doi.org/10.1016/S0735-1097\(00\)00997-9](https://doi.org/10.1016/S0735-1097(00)00997-9).
- [149] K. Pilichou, G. Thiene, B. Bauce, et al., Arrhythmogenic cardiomyopathy, *Orphanet J. Rare Dis.* 11 (1) (2016) 1–17, <https://doi.org/10.1186/S13023-016-0407-1/FIGURES/9>.
- [150] G. Thiene, C. Basso, Arrhythmogenic right ventricular cardiomyopathy: an update, *Cardiovasc. Pathol.* 10 (3) (2001) 109–117, [https://doi.org/10.1016/S1054-8807\(01\)00067-9](https://doi.org/10.1016/S1054-8807(01)00067-9).
- [151] S. Sen-Chowdhry, P. Syrris, S.K. Prasad, et al., Left-dominant arrhythmogenic cardiomyopathy: an under-recognized clinical entity, *J. Am. Coll. Cardiol.* 52 (25) (2008) 2175–2187, <https://doi.org/10.1016/J.JACC.2008.09.019>.
- [152] C. Basso, F. Ronco, F. Marcus, et al., Quantitative assessment of endomyocardial biopsy in arrhythmogenic right ventricular cardiomyopathy/dysplasia: an in vitro validation of diagnostic criteria, *Eur. Heart J.* 29 (22) (2008) 2760–2771, <https://doi.org/10.1093/EURHEARTJ/EHN415>.
- [153] D. Corrado, G. Thiene, A. Nava, L. Rossi, N. Pennelli, Sudden death in young competitive athletes: clinicopathologic correlations in 22 cases, *Am. J. Med.* 89 (5) (1990) 588–596, [https://doi.org/10.1016/0002-9343\(90\)90176-E](https://doi.org/10.1016/0002-9343(90)90176-E).
- [154] D. Corrado, C. Basso, G. Rizzoli, M. Schiavon, G. Thiene, Does sports activity enhance the risk of sudden death in adolescents and young adults? *J. Am. Coll. Cardiol.* 42 (11) (2003) 1959–1963, <https://doi.org/10.1016/J.JACC.2003.03.002>.
- [155] R. Bariani, A. Cipriani, S. Rizzo, et al., “Hot phase” clinical presentation in arrhythmogenic cardiomyopathy, *Europace*. 23 (6) (2021) 907–917, <https://doi.org/10.1093/EUROPACE/EUAA343>.
- [156] E. Monda, G. Palmiero, M. Rubino, et al., Molecular basis of inflammation in the pathogenesis of cardiomyopathies, *Int. J. Mol. Sci.* 21 (18) (2020) 1–14, <https://doi.org/10.3390/IJMS21186462>.
- [157] J. Karmouch, A. Protonotarios, P. Syrris, Genetic basis of arrhythmogenic cardiomyopathy, *Curr. Opin. Cardiol.* 33 (3) (2018) 276–281, <https://doi.org/10.1097/HCO.0000000000000509>.
- [158] B. Bauce, A. Nava, G. Beffagna, et al., Multiple mutations in desmosomal proteins encoding genes in arrhythmogenic right ventricular cardiomyopathy/dysplasia, *Heart Rhythm*. 7 (1) (2010) 22–29, <https://doi.org/10.1016/J.HRTHM.2009.09.070>.
- [159] I. Rigato, B. Bauce, A. Rampazzo, et al., Compound and digenic heterozygosity predicts lifetime arrhythmic outcome and sudden cardiac death in desmosomal gene-related arrhythmogenic right ventricular cardiomyopathy, *Circ. Cardiovasc. Genet.* 6 (6) (2013) 533–542, <https://doi.org/10.1161/CIRCGENETICS.113.000288>.
- [160] F.I. Marcus, W.J. McKenna, D. Sherrill, et al., Diagnosis of arrhythmogenic right ventricular cardiomyopathy/dysplasia: proposed modification of the task force criteria, *Circulation*. 121 (13) (2010) 1533–1541, <https://doi.org/10.1161/CIRCULATIONAHA.108.840827>.
- [161] P.M. Elliott, A. Anastakis, A. Asimaki, et al., Definition and treatment of arrhythmogenic cardiomyopathy: an updated expert panel report, *Eur. J. Heart Fail.* 21 (8) (2019) 955–964, <https://doi.org/10.1002/EJHF.1534>.
- [162] D. Corrado, M. Perazzolo Marra, A. Zorzi, et al., Diagnosis of arrhythmogenic cardiomyopathy: the Padua criteria, *Int. J. Cardiol.* 319 (2020) 106–114, <https://doi.org/10.1016/J.IJCARD.2020.06.005>.
- [163] A.S.J.M. Te Riele, H. Tandri, D.A. Bluemke, Arrhythmogenic right ventricular cardiomyopathy (ARVC): cardiovascular magnetic resonance update, *J. Cardiovasc. Magn. Reson.* 16 (1) (2014) 1–15, <https://doi.org/10.1186/S12968-014-0050-8/FIGURES/7>.
- [164] D. Corrado, P.J. Van Tintelen, W.J. McKenna, et al., Arrhythmogenic right ventricular cardiomyopathy: evaluation of the current diagnostic criteria and differential diagnosis, *Eur. Heart J.* 41 (14) (2020) 1414–1427b, <https://doi.org/10.1093/EURHEARTJ/EHZ669>.
- [165] D. Corrado, T. Wichter, M.S. Link, et al., Treatment of Arrhythmogenic right ventricular cardiomyopathy/dysplasia: an international task force consensus statement, *Circulation*. 132 (5) (2015) 441–453, <https://doi.org/10.1161/CIRCULATIONAHA.115.017944>.
- [166] B. Bauce, A. Rampazzo, C. Basso, et al., Clinical phenotype and diagnosis of arrhythmogenic right ventricular cardiomyopathy in pediatric patients carrying desmosomal gene mutations, *Heart Rhythm*. 8 (11) (2011) 1686–1695, <https://doi.org/10.1016/J.HRTHM.2011.06.026>.
- [167] A.S.J.M. Te Riele, C.A. James, A.C. Sawant, et al., Arrhythmogenic right ventricular dysplasia/cardiomyopathy in the pediatric population: clinical characterization and comparison with adult-onset disease, *JACC Clin. Electrophysiol.* 1 (6) (2015) 551–560, <https://doi.org/10.1016/J.JACEP.2015.08.004>.
- [168] N. Protonotarios, A. Tsatsopoulou, P. Patsourakos, et al., Cardiac abnormalities in familial palmoplantar keratosis, *Br. Heart J.* 56 (4) (1986) 321–326, <https://doi.org/10.1136/HRT.56.4.321>.
- [169] E.E. Norgett, S.J. Hatsell, L. Carvajal-Huerta, et al., Recessive mutation in desmoplakin disrupts desmoplakin-intermediate filament interactions and causes dilated cardiomyopathy, woolly hair and keratoderma, *Hum. Mol. Genet.* 9 (18) (2000) 2761–2766, <https://doi.org/10.1093/HMG/9.18.2761>.
- [170] U. Costabel, G. Hunninghake, ATS/ERS/WASOG statement on sarcoidosis. Sarcoidosis statement committee. American Thoracic Society. European Respiratory Society. World Association for Sarcoidosis and Other Granulomatous Disorders, *Eur. Respir. J.* 14 (4) (1999).
- [171] D.H. Birnie, W.H. Sauer, F. Bogun, et al., HRS expert consensus statement on the diagnosis and management of arrhythmias associated with cardiac sarcoidosis, *Heart Rhythm*. 11 (7) (2014) 1304–1323, <https://doi.org/10.1016/J.HRTHM.2014.03.043>.
- [172] A. Ichinose, H. Otani, M. Oikawa, et al., MRI of cardiac sarcoidosis: basal and Subepicardial localization of myocardial lesions and their effect on left ventricular function, *Cardiac. Imaging Original Res.* (2008), <https://doi.org/10.2214/AJR.07.3089>. Published online.
- [173] B. Philips, S. Madhavan, C.A. James, et al., Arrhythmogenic right ventricular dysplasia/cardiomyopathy and cardiac sarcoidosis: distinguishing features when the diagnosis is unclear, *Circ. Arrhythm. Electrophysiol.* 7 (2) (2014) 230–236, <https://doi.org/10.1161/CIRCEP.113.000932>.
- [174] W. Okumura, T. Iwasaki, T. Toyama, et al., Usefulness of Fasting 18 F-FDG PET in Identification of Cardiac Sarcoidosis, 2022.
- [175] D.H. Birnie, W.H. Sauer, F. Bogun, et al., HRS expert consensus statement on the diagnosis and management of arrhythmias associated with cardiac sarcoidosis, *Heart Rhythm*. 11 (7) (2014) 1304–1323, <https://doi.org/10.1016/J.HRTHM.2014.03.043>.
- [176] M.A. Judson, B.W. Thompson, D.L. Rabin, et al., The diagnostic pathway to sarcoidosis, *Chest*. 123 (2) (2003) 406–412, <https://doi.org/10.1378/CHEST.123.2.406>.
- [177] R.P. Baughman, D. Valeyre, P. Korsten, et al., ERS clinical practice guidelines on treatment of sarcoidosis, *Eur. Respir. J.* (2021) 2004079, <https://doi.org/10.1183/13993003.04079-2020>. Published online June.