

# Microsurgical Salvage of Acute Lower Limb Ischemia after Iatrogenic Femoral Injury during Orthopedic Surgery in a Pediatric Patient

Mario D'Oria,<sup>1</sup> Kevin Mani,<sup>1</sup> and Andres Rodriguez Lorenzo,<sup>2</sup> Uppsala, Sweden

Acute lower limb ischemia (ALLI) in the pediatric population is rare but may lead to limb loss and life-long complications. We report the technique and outcomes of microsurgical salvage of ALLI in a preterm newborn after open reduction of congenital hip dysplasia. A 2-month-old girl was born premature at week 36 with congenital bilateral hip dysplasia. The initial management attempted was conservative and entailed placement of bilateral Von Rosen splints. The treatment was successful on the left side, but the patient had recurrent unstable hip dislocation on the right side. Subsequently, 2 attempts at close reduction under general anesthesia were done and both were unsuccessful in maintaining the right hip in the acetabulum. Therefore, an open reduction of the right hip was planned through a medial/obturator approach. During the surgical procedure, the neurovascular femoral bundle (including the superficial femoral artery [SFA], femoral vein [FV], and femoral nerve) was accidentally transected with subsequent development of ALLI. Therefore, the FV was harvested distally to the injury site and a 4-cm long healthy segment was obtained. It was reversed, flushed with heparin, spatulated at both extremities, and interposed to the SFA in end-to-end fashion using two 9/0 polypropylene interrupted sutures under microscope. Reperfusion of the limb was noted immediately after releasing the vascular clamps. The final ischemia time at completion of the surgical procedure was 6 hr. Thereby, prophylactic 4-compartment fasciotomies were performed in the right leg. The patient tolerated the procedure well and the postoperative clinical course was free from adverse events. Duplex ultrasound examination at 6 weeks after the intervention confirmed sustained clinical success and showed no signs of venous thromboembolism. At the same time, X-ray examination of the right hip confirmed adequate and stable reduction of the joint in the acetabulum. ALLI due to accidental arterial injury during orthopedic surgical procedures for congenital defects in newborns is a rare but potentially devastating complication. Microsurgical salvage is a safe, feasible, and effective option to restore limb flow. Multidisciplinary expertise and meticulous technique are mandatory in order to achieve satisfactory and durable outcomes.

*Funding:* None

*Conflicts of interest:* None

D'Oria helped in writing the manuscript; D'Oria, Mani, and Lorenzo helped in data collection, critical revision, approval of the manuscript, and Agreement to be accountable.

<sup>1</sup>Department of Surgical Sciences, Section of Vascular Surgery, Uppsala University, Uppsala, Sweden.

<sup>2</sup>Department of Plastic and Maxillofacial Surgery, Uppsala University Hospital, Uppsala, Sweden.

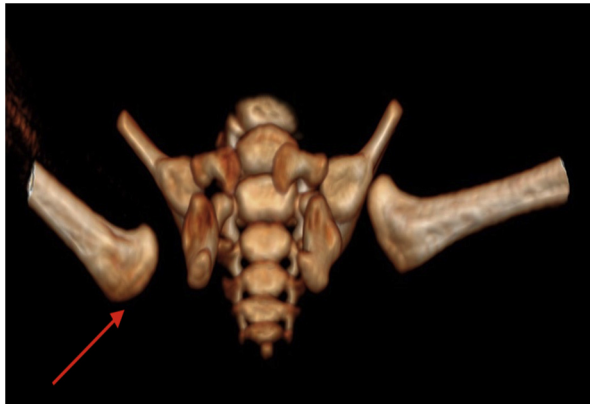
Correspondence to: Mario D'Oria, MD, Department of Surgical Sciences, Section of Vascular Surgery, Uppsala University, Uppsala SE 75185, Sweden; E-mail: [mario.doria88@outlook.com](mailto:mario.doria88@outlook.com)

*Ann Vasc Surg* 2020; 69: 452.e5–452.e11

<https://doi.org/10.1016/j.avsg.2020.06.064>

© 2020 The Author(s). Published by Elsevier Inc. This is an open access article under the CC BY license (<http://creativecommons.org/licenses/by/4.0/>).

Manuscript received: April 27, 2020; manuscript accepted: June 28, 2020; published online: 4 July 2020



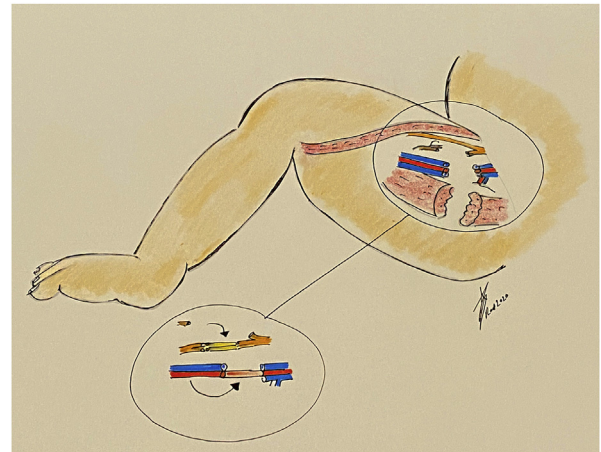
**Fig. 1.** Computed tomography angiography with 3-dimensional volume reconstruction showing wide dislocation of the right hip from the acetabulum (red arrow) after 2 unsuccessful attempts at close reduction.

Acute lower limb ischemia (ALLI) in the pediatric population is rare but may lead to limb loss and life-long complications. Iatrogenic injury from vessel catheterization is the most frequent cause of ALLI in infants and children; in contrast with adults, it can be managed nonoperatively with anticoagulation alone likely because of the greater ability to develop arterial collaterals.<sup>1,2</sup> Current clinical practice guidelines recommend that, for infants and children younger than 2 years of age with ALLI, initial conservative management with heparin is recommended (level of evidence: 1C).<sup>3</sup> However, persistent iliofemoral thrombosis is a risk factor for limb length discrepancy with growth.<sup>4</sup> Furthermore, contemporary series demonstrate that, when needed, surgical revascularization in pediatric patients may achieve excellent immediate as well as long-term outcomes.<sup>5,6</sup> Herein we report the technique and outcomes of microsurgical salvage of ALLI in a preterm newborn after open reduction of congenital hip dysplasia. Both parents expressed written informed consent to writing of the case and thereby authorized reproduction of anonymized pictures.

## CASE REPORT

The patient was a 36-week premature girl (length 45 cm, weight 5.5 kg) who was born premature with congenital bilateral hip dysplasia. She was otherwise healthy but had a positive family background of skeletal dysplastic disorders in the lower extremities.

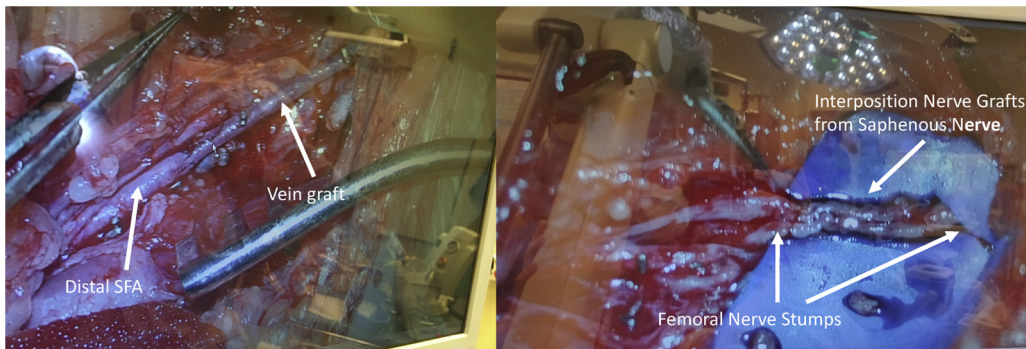
Upon time of birth, ultrasound examination showed bilateral Graf type IV developmental hip dysplasia (i.e., complete dislocation). The hips were reduced and positioned in an abduction brace (von Rosen splint). The treatment was successful on the left side, but the patient's right



**Fig. 2.** Schematic drawing showing the complete transection of the right neurovascular femoral bundle (left box). Reconstruction was made using the femoral vein and the saphenous nerve as interposition grafts for the superficial femoral artery and femoral nerve, respectively (right box).

hip could not be held in stable reduction. Subsequently, an arthrogram was performed, the hip manually reduced, and a Spica cast applied under general anesthesia. However, despite 2 attempts the hip could not be held in place and dislocated posteriorly (Fig. 1). Owing to failure of multiple attempts at nonsurgical management of the hip dislocation, an open reduction of the right hip was planned. The operative plan entailed capsulorrhaphy through an ilioinguinal approach with concomitant tenotomy of the long adductor and iliopsoas muscle via a separate medial incision.

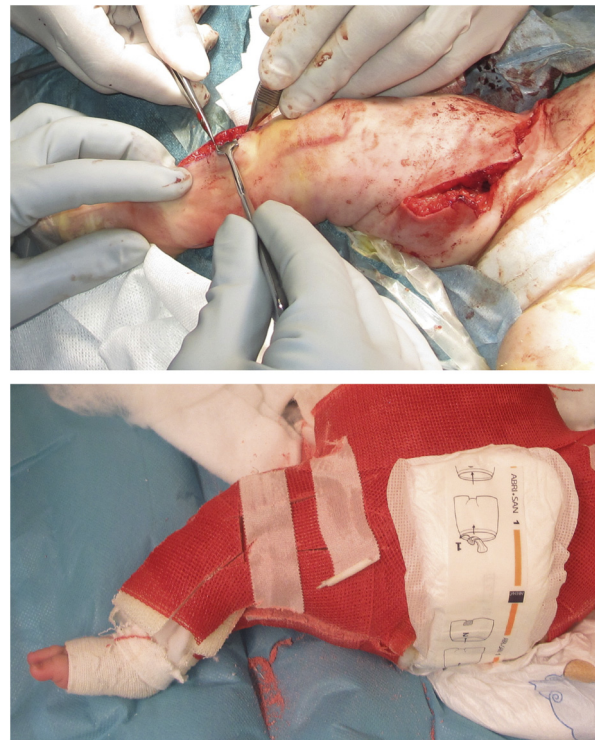
Open reduction of the right hip was undertaken when the patient was 2 months old. During the surgical procedure, the neurovascular femoral bundle (including the superficial femoral artery [SFA], femoral vein [FV], and femoral nerve [FN]) was accidentally transected with subsequent development of ALLI (Fig. 2). The traumatism occurred while performing tenotomy of the iliopsoas muscle, during which a bleeding vessel was confronted and ligated over mosquito clamps. The maneuver resulted in the leg becoming mottled, with complete loss of all Doppler signals from the knee down to the foot. The vascular surgeon on call was consulted and felt that, owing to the extremely small caliber of the anatomical structures involved (SFA diameter around 1.5 mm), reconstructive microsurgical competence was required. After further dissection of the neurovascular femoral bundle and securing of healthy vascular stumps for the anastomosis the final resulting defect was 3-cm long. This was with the patient with the hip maintained abducted in order to hold the position in the acetabulum. Given the relatively long arterial defect, direct end-to-end reconstruction was deemed an unfeasible choice. The natural choice for a vein graft in this case would be the use of the ipsilateral great saphenous vein (GSV); however, there was observed a substantial caliber discrepancy



**Fig. 3.** Intraoperative images showing the final reconstruction of the superficial femoral artery (*left box*) and the femoral nerve (*right box*).

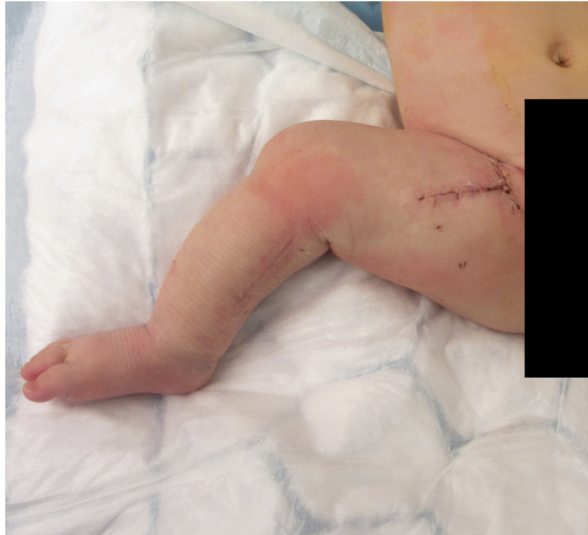between the GSV and the SFA (1:3) in this case, making it not an optimal choice due to the high risk of thrombosis. After exploration of the distal FV, it was noted that the vessel was of a similar caliber to the SFA. Therefore, the FV was harvested distally to the injury site and a 4-cm long healthy segment was obtained. It was reversed, flushed with heparin, spatulated at both extremities, and interposed to the SFA in end-to-end fashion with 9/0 polypropylene simple interrupted sutures using an operating microscope (Leica Microsystems M720 OH5). A bolus of intravenous heparin (100 units) was administered, but no systemic administration of medications against arterial spasm was given. However, after completion of the anastomoses, the vascular reconstruction was irrigated with 1 mL of papaverine solution (40 mg/mL). The FN was also reconstructed with 2 cable nerve grafts obtained from the saphenous nerve at the thigh using the same surgical incision and sutured with 9/0 polypropylene simple interrupted sutures that were sealed with fibrin glue (Fig. 3). The FV was left unreconstructed. Reperfusion of the limb was noted immediately after releasing the vascular clamps. The final ischemia time at completion of the surgical procedure was 6 hr. Thereby, prophylactic 4-compartment fasciotomy was performed in the right leg. The patient was then positioned in a Spica cast to maintain both hips in place (Fig. 4).

The patient tolerated the procedure well and the postoperative clinical course was free from major adverse events. Low molecular weight heparin (Fragmin®) was administered subcutaneously, with an equivalent dose of 100 units/kg/day. This anticoagulation regimen was maintained throughout the hospitalization with close monitoring of coagulation Factor Xa levels and for 1 month after the operation. Mild swelling developed in the right lower extremity which persisted for several days but eventually resolved within 2 weeks without additional treatment (Fig. 5). All surgical incisions healed completely, and the patient was discharged from the hospital on postoperative day 16. Duplex ultrasound examination at 6 weeks after the intervention confirmed sustained clinical success and



**Fig. 4.** After the neurovascular reconstruction was completed, 4-compartment fasciotomies of the right lower limb were performed (*left box*). A splint was then put to secure both hips into a stable position (*right box*).

showed no signs of venous thromboembolism. At the same time, X-ray examination of the right hip confirmed adequate and stable reduction of the joint in the acetabulum. At the last clinical follow-up available (6 months postoperatively), no signs of recurrent ischemia of the right leg were noted and the patient was following a normal growth chart as expected. Clinically, no swelling of the limb was noted and good activation of the quadriceps muscle with full knee extension was present.



**Fig. 5.** At 2 weeks postoperatively, the right lower limb was well perfused with residual mild swelling. All surgical incisions were completely healed.

## DISCUSSION

Surgical reduction of congenital hip dislocation is technically challenging and usually reserved for those patients who have failed nonoperative treatment, which is the first-line strategy. The 2 most common complications that can occur after surgical reduction of hip dislocation are recurrent dislocation of the joint and avascular necrosis of the femoral epiphysis.<sup>7</sup> Inadvertent femoral injury during the surgical procedure is an extremely rare, although possible, event. In the case presented above, the iatrogenic damage resulted in complete transection of the entire neurovascular femoral bundle. This was effectively rescued during the same operation using microvascular techniques. Microsurgical salvage rescue resulted in effective restoration of vascular and neurologic function, with clinical evidence of good limb perfusion and recovered muscular function at 6-month follow-up after the operation.

Although anticoagulation alone appears to be a relatively safe early strategy in the majority of cases (allowing partial or complete resolution of thrombus, development of collaterals, and recovery of limb perfusion at the price of a small risk of bleeding complications),<sup>8–11</sup> long-term outcomes of conservative management have also been evaluated, suggesting that up to 15% of infants with ALLI will experience either intermittent claudication or impaired growth resulting in limb discrepancy.<sup>1,12–14</sup> Indeed, conservative management with systemic heparinization has been the mainstay of

ALLI treatment in children but is mostly based on expert opinion and small case series, as literature is scarce and there are no randomized controlled trials allowing for direct head-to-head comparison of conservative management versus intervention in the pediatric population. In the presented case, it was elected to proceed with immediate surgical revascularization for several reasons. First, since the damaged vascular structures were already exposed in the operative field, it was felt unethical to leave them unrepaired at that time. Furthermore, given the massive surgical trauma and inherent risk for postoperative bleeding, a long-term course of anti-coagulation was deemed to expose the patient to the potential risk for severe bleeding complications. Finally, given the preexisting risk for limb discrepancy owing to the underlying orthopedic condition, the operators elected to perform complete limb reperfusion in order to allow for optimal growth conditions after surgery.

Although the principles of revascularization are the same in both pediatric and adult patients, some intraoperative factors specific to children are worth mentioning. Pediatric patients are typically not finished growing, and any implanted graft should be able to grow with them. Therefore, when lower extremity bypass surgery is to be performed in pediatric patients, use of autologous material with the potential for remodeling in the long run must be employed. Synthetic conduit or cryopreserved homograft should be employed with extreme caution because of their known shortcomings including reduced long-term patency, higher risk of infection, and tendency to degenerate over time.<sup>15,16</sup> Previous series have reported excellent outcomes with a native reversed saphenous vein graft in the pediatric population, with minimal graft dilation or stenosis on long-term follow-up.<sup>17–19</sup> However, the technical challenge imposed in our case was to reconstruct the long gap in the SFA with a tiny GSV (diameter around 0.5 mm). Although vein arterialization is a natural phenomenon observed after peripheral bypass surgery, we felt that using a <1-mm donor conduit with a 1:3 diameter mismatch compared with the recipient vessel would have likely resulted in insufficient anastomosis and disturbed flow hemodynamic with the subsequent risk for early and late failure. Given the necessity to promptly and completely re-establish limb perfusion to allow for optimal post-surgical results, we elected to use the ipsilateral FV instead, which is a well-known material for vascular reconstruction in the adult population where it has been mainly used for in situ reconstruction after removal of infected abdominal aortic

grafts.<sup>20–22</sup> Although it might be argued that harvesting the vein from the ipsilateral side could add to the overall damage on the operated limb, it must be noted that preparation of this vessel usually involves a deep surgical trauma and entails a potential (although rare) risk for both acute and chronic venous morbidity in the donor limb. For the above reasons, the ipsilateral FV was used, with harvesting distal to the site of injury and the vein itself was left unreconstructed at this stage. It did not result in any major venous morbidity of the limb, aside from mild swelling initially, and we expect collateral venous pathways to develop over time.

Vascular reconstructions in infants and neonates are complicated by small, thin-walled vessels with a tendency to spasm and this may lead to discouraging outcomes after emergency revascularization. A few previous cases have already demonstrated the application of microvascular techniques for arterial reconstruction in the pediatric population.<sup>23–25</sup> In that sense, some technical points must be properly addressed to ensure satisfactory and durable outcomes. Considering interrupted rather than running suture is prudent to avoid narrowing of the anastomosis with growth of the child. In addition, single length autogenous vein should be implanted whenever feasible. Furthermore, pediatric vessels aggressively narrow with surgical handling as a result of significant transient vasospasm, and the addition of papaverine to the saline housing the freshly harvested vein can help mitigate this phenomenon. In the reported case, spasm was noted at the level of both the proximal and distal arterial stumps, as well as in the healthy segments closer to the traumatized edges. However, no further spasm was evident after interposition of the vein graft and completion of the vascular reconstruction. Microsurgical instruments are designed to minimize trauma at the site of anastomosis; this may reduce the risk of thrombotic complications following reconstruction. Vessel damage can be prevented by avoiding strong manipulation of the vessel wall or endothelial surface directly, and instead grasping the vessel using the adventitial tissue surrounding the artery. However, both the donor and the recipient vessel should be carefully dissected at the site of anastomosis to ensure that no adventitial tissue may be inadvertently incorporated into the anastomosis site, which may act as a thrombogenic focus. Finally, despite the lack of large prospective studies, local flushing of the vessels with heparin before the microvascular anastomoses is commonplace at many institutions<sup>26</sup> and currently adopted in our practice as it has been shown to enhance patency of microvascular reconstructions in experimental animal models.<sup>27</sup>

Compartment syndrome (CS) is a known and feared complication after revascularization for ALLI as it can have both limb-threatening and life-threatening consequences. In the adult population, patients often undergo prophylactic 4-compartment fasciotomy at the time of revascularization to avoid developing CS and its associated complications. However, fasciotomy carries its own morbidity and surgeons may opt against this initially, but the subsequent development of CS would mandate fasciotomy in a delayed fashion. Evidence from the literature on ALLI in adults suggest that, when fasciotomy is not performed early, the subsequent development of CS requiring delayed fasciotomy may be associated with increased risk of major amputation at 30 days.<sup>28</sup> This could suggest that a liberal approach to prophylactic fasciotomy at the time of revascularization may improve limb salvage rates and that early fasciotomy should be implemented after surgical revascularization for lower extremity arterial injury.<sup>29</sup> However, the literature on this topic in the pediatric population is lacking and, given the rarity of the pathology, decisions are to be made on a case-by-case basis. In our case, we elected to perform prophylactic fasciotomy at the time of revascularization based on the assumption that the intrinsic additional morbidity carried by the procedure was lower than the expected benefits. Indeed, the long ischemic time (6 hr) at completion of revascularization in a patient with an already occurred peripheral nervous injury made us feel that prophylactic fasciotomy was justified.

Optimal antithrombotic therapy after lower limb revascularization in the pediatric population is ill defined. The duration of anticoagulation in pediatric ALLI is subject to consensus guidelines rather than prospective data. Current clinical practice guidelines recommend a 5- to 7-day course of therapeutic anticoagulation with unfractionated heparin or low molecular weight heparin for neonates or children with acute femoral artery thrombosis (level of evidence: 2C).<sup>30</sup> Aspirin remains the most common antiplatelet agent used in pediatrics. The dose of aspirin for optimal inhibition of platelet aggregation is not known and empirical doses of 1–5 mg/kg/day have been proposed by current clinical practice guidelines (level of evidence: 2C).<sup>31</sup> The relatively low doses of aspirin used as antiplatelet therapy, compared with the much higher doses used for anti-inflammatory therapy, seem to seldom cause adverse side effects. For instance, although aspirin has been associated with Reye syndrome, this appears to be a dose-dependent effect of aspirin and usually is associated with doses >40 mg/kg/day.<sup>32–34</sup> There are no guidelines, however, to

inform on postoperative medical therapy after surgical revascularization. As such, the expected benefits of better patency should be weighed against the potential risks of more bleeding (especially intracranial hemorrhage) in this delicate population. In our case, given the absence of any clinical and ultrasonographic findings of venous thromboembolism or technical defect of the surgical reconstruction, we elected to withdraw all antithrombotic drugs after 1 month.

## CONCLUSION

ALLI due to accidental arterial injury during orthopedic surgical procedures for congenital defects in newborns is a rare but potentially devastating complication. Microsurgical salvage is a safe, feasible, and effective option to restore limb flow. Multidisciplinary expertise and meticulous technique are mandatory in order to achieve satisfactory and durable outcomes.

## REFERENCES

- Kaissy A, Shaikh F, Roche-Nagle G, et al. Management of acute limb ischemia in the pediatric population. *J Vasc Surg* 2014;60:106–10.
- Sadat U, Hayes PD, Varty K. Acute limb ischemia in pediatric population secondary to peripheral vascular cannulation: literature review and recommendations. *Vasc Endovasc Surg* 2015;49:142–7.
- Björck M, Earnshaw JJ, Acosta, et al. European Society for Vascular Surgery (ESVS) 2020 clinical practice guidelines on the management of acute limb ischaemia. *Eur J Vasc Endovasc Surg* 2020;59:173–218.
- Andraska EA, Jackson T, Chen H, et al. Natural history of iatrogenic pediatric femoral artery injury. *Ann Vasc Surg* 2017;42:205–13.
- Kirkilas M, Notrica DM, Langlais CS, et al. Outcomes of arterial vascular extremity trauma in pediatric patients. *J Pediatr Surg* 2016;51:1885–90.
- Wang SK, Drucker NA, Raymond JL, et al. Long-term outcomes after pediatric peripheral revascularization secondary to trauma at an urban level I center. *J Vasc Surg* 2019;69:857–62.
- Glorion C. Surgical reduction of congenital hip dislocation. *Orthop Traumatol Surg Res* 2018;104:S147–57.
- Lim S, Javorski MJ, Halandras PM, et al. Epidemiology, treatment, and outcomes of acute limb ischemia in the pediatric population. *J Vasc Surg* 2018;68:182–8.
- Rizzi M, Kroiss S, Kretschmar O, et al. Long-term outcome of catheter-related arterial thrombosis in infants with congenital heart disease. *J Pediatr* 2016;170:181–7.
- Downey C, Aliu O, Nemir S, et al. An algorithmic approach to the management of limb ischemia in infants and young children. *Plast Reconstr Surg* 2013;131:573–81.
- Lin PH, Dodson TF, Bush RL, et al. Surgical intervention for complications caused by femoral artery catheterization in pediatric patients. *J Vasc Surg* 2001;34:1071–8.
- Matos JM, Fajardo A, Dalsing MC, et al. Evidence for nonoperative management of acute limb ischemia in infants. *J Vasc Surg* 2012;55:1156–9.
- Lazarides MK, Georgiadis GS, Papas TT, et al. Operative and nonoperative management of children aged 13 years or younger with arterial trauma of the extremities. *J Vasc Surg* 2006;43:72–6.
- Wang SK, Lemmon GW, Drucker NA, et al. Results of nonoperative management of acute limb ischemia in infants. *J Vasc Surg* 2018;67:1480–3.
- Albertini JN, Barral X, Branchereau A, et al. Long-term results of arterial allograft below knee bypass grafts for limb salvage: a retrospective multicenter study. *J Vasc Surg* 2000;31:426–35.
- Ziza V, Canaud L, Gandet T, et al. Outcomes of cold-stored venous allograft for below knee bypasses in patients with critical limb ischemia. *J Vasc Surg* 2015;62:974–83.
- Dalsing MC, Cikrit DF, Sawchuk AP. Open surgical repair of children less than 13 years old with lower extremity vascular injury. *J Vasc Surg* 2005;41:983–7.
- Fayiga YJ, Valentine RJ, Myers SI, et al. Blunt pediatric vascular trauma: analysis of forty-one consecutive patients undergoing operative intervention. *J Vasc Surg* 1994;20:419–24.
- Cardneau JD, Henke PK, Upchurch GR Jr, et al. Efficacy and durability of autogenous saphenous vein conduits for lower extremity arterial reconstructions in preadolescent children. *J Vasc Surg* 2001;34:34–40.
- Dirven M, van der Jagt MF, Barendregt WB, et al. The efficacy and durability of autologous femoro-popliteal vein reconstruction for primary aortic and aortic graft infection. *Ann Vasc Surg* 2015;29:1188–95.
- Dorweiler B, Neufang A, Chaban R, et al. Use and durability of femoral vein for autologous reconstruction with infection of the aortiliofemoral axis. *J Vasc Surg* 2014;59:675–83.
- Heinola I, Kantonen I, Jaroma M, et al. Editor's choice – Treatment of aortic prosthesis infections by graft removal and in situ replacement with autologous femoral veins and fascial strengthening. *Eur J Vasc Endovasc Surg* 2016;51:232–9.
- LoGiudice JA, Adamson K, Ghanayem N, et al. Microvascular surgery in the congenital cardiac patient: a case series exploring feasibility and practical applications. *J Plast Reconstr Aesthet Surg* 2017;70:639–45.
- Adamson K, Braza ME, LoGiudice JA, et al. Microsurgical repair of neonatal iliac artery injuries with saphenous vein grafts. *J Neonat Perinat Med* 2018;11:105–8.
- Zuo KJ, Draginov A, Panossian A, et al. Microvascular hepatic artery anastomosis in pediatric living donor liver transplantation: 73 consecutive cases performed by a single surgeon. *Plast Reconstr Surg* 2018;142:1609–19.
- Froemel D, Fitzsimons S-J, Frank J, et al. A review of thrombosis and antithrombotic therapy in microvascular surgery. *Eur Surg Res* 2013;50:32–43.
- Fu K, Izquierdo R, Walenga JM, et al. Comparative study on the use of anticoagulants heparin and recombinant hirudin in a rabbit traumatic anastomosis model. *Thromb Res* 1995;78:421–8.
- Rothenberg KA, George EL, Trickey AW, et al. Delayed fasciotomy is associated with higher risk of major amputation in patients with acute limb ischemia. *Ann Vasc Surg* 2019;59:195–201.
- Farber A, Tan TW, Hamburg NM, et al. Early fasciotomy in patients with extremity vascular injury is associated with decreased risk of adverse limb outcomes: a review of the National Trauma Data Bank. *Injury* 2012;43:1486–91.

30. Monagle P, Chan AK, Goldenberg NA, et al. Antithrombotic therapy in neonates and children: antithrombotic therapy and prevention of thrombosis, 9th ed: American College of Chest Physicians Evidence-Based Clinical Practice Guidelines. *Chest* 2012;141(2 Suppl):e737–801S.
31. Porter JD, Robinson PH, Glasgow JF, et al. Trends in the incidence of Reye's syndrome and the use of aspirin. *Arch Dis Child* 1990;65:826–9.
32. Remington P, Shabino CL, McGee H, et al. Reye syndrome and juvenile rheumatoid arthritis in Michigan. *Am J Dis Child* 1985;139:870–2.
33. Starko KM, Ray CG, Dominguez LB, et al. Reye's syndrome and salicylate use. *Pediatrics* 1980;66:859–64.
34. Young RS, Torretti D, Williams RH, et al. Reye's syndrome associated with long-term aspirin therapy. *JAMA* 1998;251:754–6.