




Contents lists available at ScienceDirect

Seminars in Orthodontics

journal homepage:



Customized HIRME vs Haas expander: A 3-dimensional volumetric and surface evaluation

Lucia Pozzan^{a,*}, Daniela Lupini^b, Alessandra Bertoli^c, Domenico Tripodi^d, Jasmina Primožič^e, Luca Contardo^a

^a Department of Medicine, Surgery and Health Sciences, University of Trieste, Trieste, Italy

^b Department of Medicine, Surgery and Health Sciences, University of Trieste, Private Practice of Orthodontics in Giulianova Italy, Italy

^c Department of Orthodontics and Jaw Orthopedics, Medical Faculty, University of Ljubljana, Vrazov trg 2, SI-1000, Ljubljana, Slovenia

^d Department of Medical, Oral and Biotechnological Sciences, University of Chieti, Italy

^e DDS, MS, Private Practice in Maniago (PN), Italy

ARTICLE INFO

Keywords:

Rapid maxillary expansion
Deciduous teeth
Digital orthodontics
Palatal Volume
Three-dimensional Treatment Evaluation

ABSTRACT

Rapid Maxillary Expansion (RME) is a commonly used intervention to address posterior crossbite and alleviate functional issues associated with anterior crowding. The purpose of the study is to compare the quality and quantity of expansion of two different Haas devices with anchorage on deciduous elements, one custom-made (HIRME), through a three-dimensional analysis of the changes in the palatine vault after expansion. The study retrospectively examined a total of 30 patients, equally divided into two groups, and showed an average increase in palatal surface area of 28.81 % for the traditional Haas expander and 24.38 % for the HIRME device. The increase in surface and volume was significant for both devices ($p < 0.001$), while no significant differences in surface or volume increase were found between the two devices (Haas: $p = 0.365$; Hirme: 0.354). This study underlined the efficacy of the custom HIRME device in increasing palatal surface and volume in patients with transverse discrepancy.

Introduction

Rapid Maxillary Expansion (RME) is a commonly used intervention to address transverse deficiency in developing individuals.¹ The primary mechanism involves expanding the transverse dimensions by inducing separation of the incompletely ossified mid-palatal suture in its two halves, followed by buccal movement of posterior teeth and alveolar processes.² In contemporary clinical practice, transverse maxillary deficiency is common and is often linked to posterior crossbite and anterior crowding. Orthopedic skeletal expansion is recommended, particularly in growing patients before complete craniofacial suture calcification, to prevent skeletal asymmetries.³ According to Baccetti et al.,⁴ RME should be implemented before the peak of skeletal growth to achieve more pronounced transverse craniofacial modifications at the skeletal level, while minimizing dental compensatory effects.⁵ With advancing age, the increase in resistance of various craniofacial structures becomes evident.¹ Despite diverse expansion protocols, RME remains a widely employed early treatment strategy to address posterior crossbite and alleviate functional issues associated with abnormal breathing patterns.^{6,7} Successful RME treatment conventionally aims at minimal tooth movement and maximal skeletal adjustments, facilitated by hyalinization of the periodontal ligament of the anchor teeth.⁸

During the active phase of the maxillary expansion treatment, significant forces are applied to anchor the teeth to initiate the opening of the mid-palatal suture, the intensity of the force gradually diminishing over the following 5 to 7 weeks, constituting the retention phase.⁹ Post-expansion, basal bones continue to experience relapse for up to 10 months, and anchor teeth may exhibit changes such as exostosis, pulp stones, and root resorption.^{10,11} Molars often tilt buccally in cases of transverse deficiency to compensate for a narrow palate, especially noticeable when using first permanent molars as anchor teeth.¹²⁻¹⁴ In particular, Asanza et al.¹⁵ found that RME anchored to permanent molars resulted in changes in tooth angulation rather than genuine skeletal expansion.

To mitigate potential adverse effects, especially during the mixed dentition stage, it is recommended to use deciduous teeth as anchors for RME.¹⁶ Studies investigating RME anchored to deciduous teeth reveal changes in dental tipping compared to RME anchored to first permanent molars or deciduous molars.¹⁶⁻¹⁹

Ugolini et al. and Cerruto et al. observed that RME on second primary molars resulted in reduced molar angulation compared to RME anchored on permanent teeth.¹⁸ RME anchored on deciduous teeth led to a net increase in maxillary intercanine distance, indicating a more stable anterior arch expansion and spontaneous alignment of upper

* Corresponding author at: Department of Medicine, Surgery and Health Sciences, University of Trieste, Piazza Ospitale 1, 34125, Trieste, Italy.
E-mail address: lucia.pozzan@phd.units.it (L. Pozzan).

<https://doi.org/10.1053/j.sodo.2024.07.001>

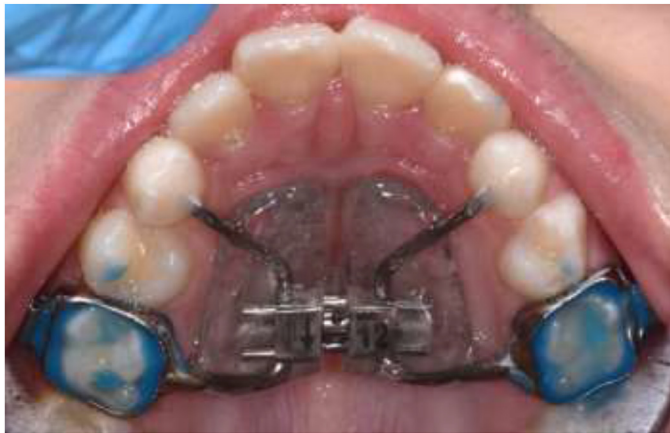

Fig. 1. Haas-type expander.

incisors.¹⁸ Mutinelli et al. emphasized the viability of using deciduous teeth as anchors for heavy forces during RME treatment, proposing it as an effective strategy to address transverse maxillary deficits.^{18–19} RME anchored to deciduous molars may also offer advantages in hyperdivergent subjects by controlling vertical dimensions and counteracting changes in mandibular posture during expansion, particularly when RME is anchored to permanent teeth.

Many different appliances have been implemented for maxillary expansion over the years. HIRME is an acronym that stands for "Hass Inspired Rapid Maxillary Expander," it is a Haas expander anchored on the deciduous CDE manufactured with CAD/CAM and Laser Melting technologies.

The purpose of the study is to compare the quality and quantity of expansion of two different Haas devices with anchorage on deciduous elements, one custom-made (HIRME) and one traditional, through a three-dimensional analysis of the changes in the palatine vault after expansion.

Materials and methods

The study retrospectively examined a total of 30 patients. 15 patients underwent interceptive treatment to correct the transverse discrepancy with traditional Haas expander anchored on E (Fig. 1), treated by residents of the Orthodontic Department of the University of Trieste, Trieste (Italy); the second group of 15 patients was treated at a private facility with a custom Haas expander (HIRME). The patients in the two groups were enrolled consecutively. The sample size of 30 patients was calculated to detect a 10 % difference between two independent means in surface and volume between the HIRME and the Haas groups.

Inclusion criteria were i) the presence of a transverse deficit (TD) between 3 and 3.5 mm, calculated as the difference between the palatal-vestibular cuspids of the upper first molars and the central fossae of the lower first molars; and ii) early or intermediate mixed dentition. Exclusion criteria were i) absent or decayed deciduous upper second molars or unsuitable for the application of an expander on E for advanced root resorption.

Baseline characteristics of the two samples at T_0 are summarized on Table 1.

Table 1
baseline characteristics at T_0 for age and transverse discrepancy (TD). Values are indicated as mean \pm standard deviation.

	HIRME	Haas
Age \pm SD at T_0	8.4 \pm 1.8	8.2 \pm 1.4
TD \pm SD at T_0	-3.29 \pm 0.17	-3.35 \pm 0.14

HIRME is an acronym that stands for "Haas Inspired Rapid Maxillary Expander," and it is a Haas expander anchored on the deciduous CDE elements using a cast structure to be bonded and a metal shield that replaces the resin shield of the traditional Haas expander; once the HIRME expander is designed, it is molded by a laser-melting procedure and the lab technician welds the expansion screw to the metal shield on the expander (Fig. 2).²⁰ In detail, the is fabricated through Direct Metal Laser Sintering (DMLS) or Selective Laser Melting (SLM), and unlike traditional laboratory-made devices, it is entirely digitally designed and manufactured. The digital process, from generating the STL file from the optical scan to the final solidification, is conducted within a CAD environment. Once the design is complete, the native file is exported as an STL file, validated, and sent to a printing service. The sintered metal product is then returned to the laboratory.

In parallel, a prototype of the dental arch model is produced in acrylic metal using a specialized 3D printer (DWS D 20, 3DRPD, Mouilleron-le-Capitf, France). This model facilitates the positioning of the initial device and supports the "post-printing process" in the dental lab. During this stage, the structure is finished using metal cutters to remove roughness and inspect undercut areas. Rubber pads are employed to refine the margins around the teeth, the frame of the arms, and the screw housing. The external surface of the HIRME is then smoothed and polished. Subsequently, the screw (Forestadent-Palatal split screw type "S" 169–1323) is laser-welded to the structure, integrating it into a single unit. The finalized device is placed on the model and delivered to the dentist. The end product is a Haas-inspired rapid maxillary expander, constructed entirely from cobalt-chrome and custom-fitted to the patient's oral anatomy.

The expansion protocol was the same in the two groups (4 activations the first day, followed by 2 activations/day for 7–14 days, based on the amount of correction needed). All patients received a 2 mm of overcorrection.

Digital impressions were taken with Itero Element® intraoral scanner (Align Technology, Inc., San Jose, CA) before the expansion device was placed and after removal (8–12 months after positioning). Digital analysis was performed with Rapidform XOR3 software (Inus Technology, Inc.). The surface area was calculated considering a line connecting the palatal gingival margin of each tooth, starting from most distal element on one side and ending on the most distal element on the contralateral side (Fig. 3). The same limit-together with a plane designed to be orthogonal to the most distal surfaces on both sides was used to calculate the palatal volume. The group of patients with HIRME-type expander was identified as "cases", while the group of patients treated with conventional Haas expander was identified as "controls." The increase in surface area and volume, in number and percentage, before and after expansion was calculated for each patient.

The Shapiro-Wilks test was used to verify the normal distribution of the sample; the paired *t*-test was used to determine the significance of the effects of the expansion in terms of surface and volume in the two groups, while the Student *t*-test was used to assess the significance of the difference between the two groups. Significance was set at $p \geq 0.05$.

The sample size of 15 subjects per group was set to detect an effect size coefficient of 1.09, based on previous unpublished data.

Results

For the Haas group, the mean age was 8.2 years \pm 1.4, while for the Hirme group it was 8.4 years \pm 1.8. The average time between the first and second scans was 12.7 months \pm 3.6 in the Hirme group and 16.6 months \pm 8.6 in the Haas group.

Table 2 shows the values of surface and volume at T_0 and T_1 , and the mean increase in the area and volume of the palatine vault following expansion and the relative percentage value (Table2).

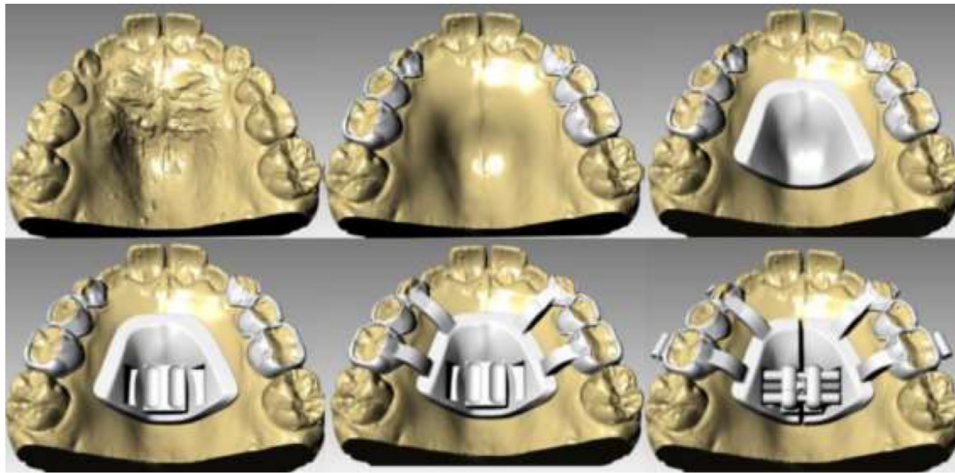

Fig. 2. digital phases of the design of the HIRME expander.

The increase in surface and volume was significant for the Haas and the Hirme appliances ($p < 0.001$), while no significant differences in surface or volume increase were found between the two devices (Haas: $p = 0.365$; Hirme: $p = 0.354$).

Discussion

This study aimed to compare the effects of rapid palatal expansion in terms of palatal and surface increase for two types of designs: a classical Haas-type expander and a new, fully digital custom-made expander called HIRME. The advantages of a HIRME-type expander over a hyrax expander are that, as with a Haas-type, the palatal shield maintains mucosal traction during the counting period, preventing the recurrence

of expansion.²¹ However, unlike a traditional Haas device, however, the use of metal shields means that the thickness can be greatly reduced, resulting in greater patient comfort, greater cleanability, and fewer risks of mucosal inflammation and reaction. What's more, the use of a completely digital process makes this device extremely time-efficient and more comfortable for the patient.²⁰ Finally, the use of cobalt-chrome, a material stiffer than those used for a traditional device, leads to greater stability.²⁰

The methodology used in this study, that is, three-dimensional analysis of models derived from a digital impression, allows an in-depth study of all dimensions of the palate, without sacrificing detail but avoiding patient exposure to additional radiogenic doses. All with a focus on patient comfort and a highly cost-effective approach.

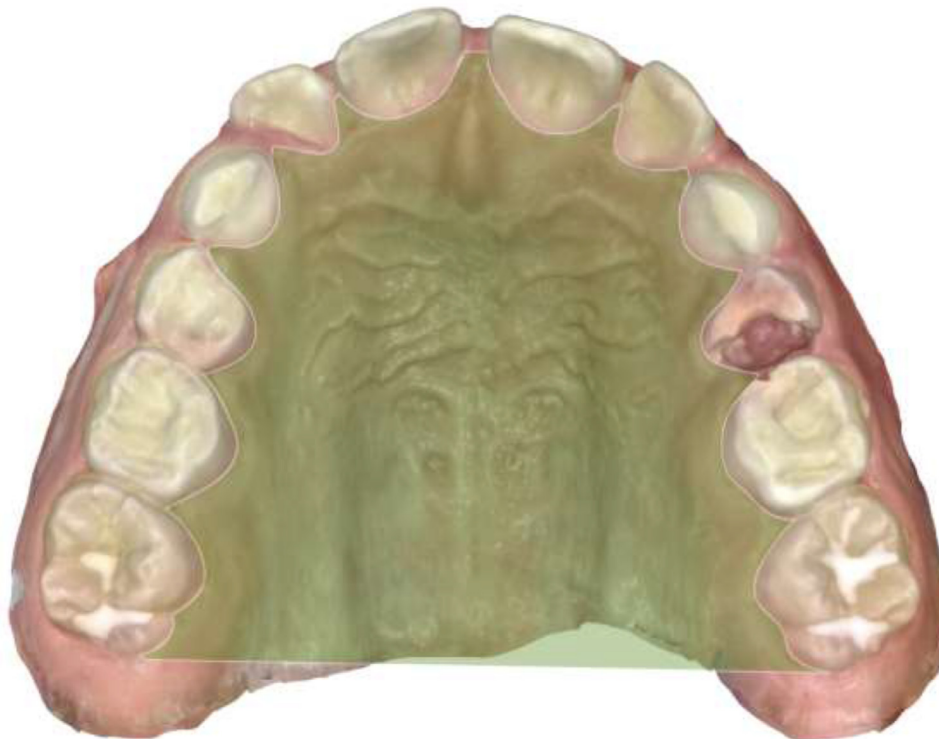

Fig. 3. Visual representation of the reference points used for surface calculation.

Table 2
descriptive statistics for the surface and volume increase in the two groups.

	Group	T ₀	T ₁	T ₁ -T ₀	Percentage Increase (%)	Sign.
Surface (mm ²)	Haas	2474.13 ± 932.99	3032.17 ± 938.51	*558.05 ± 249.49	28.81	NS
	HIRME	2454.58 ± 843.10	2931.48 ± 791.07	*476.05 ± 232.98	24.38	
Volume (mm ³)	Haas	7741.41 ± 3016.81	9703.40 ± 3244.49	*1961.99 ± 899.32	29.25	NS
	HIRME	5190.73 ± 1961.02	6814.09 ± 2602.60	*1623.36 ± 1060.55	32.32	

* paired *t*-test revealed significance of the difference between T₁ and T₀ for surface and volume for both expanders (*p* < 0.001). Sign.: significance; NS: non-significant.

Our study analyzed 30 patients, equally divided into two groups, and showed an average increase in palatal surface area of 28.81 % for the Haas group and 24.38 % for the HIRME group. As for palatal volume, the increases were 29.25 % and 32.32 % in the two groups, respectively. These differences were found to be not statistically significant. Both devices proved to be effective for palatal expansion, both in terms of surface increase and volume increase.

Given the novelty of the HIRME approach, this is the first study in the literature to analyze its effects at the palatal vault level, while in terms of the traditional Haas device a study found a 15.41 % increase in surface and a 20.78 % increase in volume (Haas on first permanent molars) .²²

The main limit of this study was that no stratification regarding age or sex was made.

While the volume increase was not statistically significant, the HIRME-treated group exhibited a more pronounced increase. This discrepancy may be attributed to several factors. Firstly, the HIRME method anchors over a larger surface area of the dental elements, providing a more stable structure that reduces the likelihood of tipping among the anchoring elements. Additionally, the rigidity and precision of the metal shield, created via intraoral scanning, enhance its conformity to the palatal vault. In contrast, traditional resin shields are prone to inaccuracies stemming from potential errors in both the material and the impression technique. These factors together suggest that the HIRME treatment's design and construction offer superior stability and precision compared to conventional methods.

Conclusions

This study underlined the efficacy of the custom HIRME device in increasing palatal surface and volume in patients with transverse discrepancy. Despite the absence, to date, of significant differences with the traditional Haas expander, the design and material of the HIRME expander aims to achieve better maintenance of the volume obtained by expansion in the short-term and better control of bone collapse at the sutural level in the months following expansion due to the rigidity of the structure and better adaptation of the metal shield to the surface of the palate.

Patient consent

Patient consent was obtained.

Funding

No funding or grant support received.

Author contributions

All authors attest that they meet the current ICMJE criteria for authorship.

Declaration of competing interest

The authors declare that they have no known competing financial interests or personal relationships that could have appeared to influence the work reported in this paper.

References

- Lione R, Pavoni C, Laganà G, Fanucci E, Ottria L, Cozza P. Rapid maxillary expansion: effects on palatal area investigated by computed tomography in growing subjects. *Eur J Paediatr Dent.* 2012;13(3):215–218. Sep.
- Sari Z, Uysal T, Usumez S, Basciftci FA. Rapid maxillary expansion. Is it better in the mixed or in the permanent dentition? *Angle Orthod.* 2003;73(6):654–661. [https://doi.org/10.1043/0003-3219\(2003\)073<0654:Rmeib>2.0.Co;2](https://doi.org/10.1043/0003-3219(2003)073<0654:Rmeib>2.0.Co;2). Dec.
- Lagravere MO, Major PW, Flores-Mir C. Long-term skeletal changes with rapid maxillary expansion: a systematic review. *Angle Orthod.* 2005;75(6):1046–1052. [https://doi.org/10.1043/0003-3219\(2005\)75\[1046:Lscwrm\]2.0.Co;2](https://doi.org/10.1043/0003-3219(2005)75[1046:Lscwrm]2.0.Co;2). Nov.
- Baccetti T, Franchi L, McNamara JA. The cervical vertebral maturation (CVM) method for the assessment of optimal treatment timing in dentofacial orthopedics. *Semin Orthod.* 2005;11(3):119–129. <https://doi.org/10.1053/j.sodo.2005.04.005>. 2005/09/01/.
- Baccetti T, Franchi L, Cameron CG, McNamara Jr JA. Treatment timing for rapid maxillary expansion. *Angle Orthod.* 2001;71(5):343–350. [https://doi.org/10.1043/0003-3219\(2001\)071<0343:Tftrme>2.0.Co;2](https://doi.org/10.1043/0003-3219(2001)071<0343:Tftrme>2.0.Co;2). Oct.
- Martina R, Cioffi I, Farella M, et al. Transverse changes determined by rapid and slow maxillary expansion—a low-dose CT-based randomized controlled trial. *Orthod Craniofac Res.* Aug 2012;15(3):159–168. <https://doi.org/10.1111/j.1601-6343.2012.01543.x>.
- da Silva Filho OG, Montes LA, Torelly LF. Rapid maxillary expansion in the deciduous and mixed dentition evaluated through posteroanterior cephalometric analysis. *Am J Orthod Dentofacial Orthop.* 1995;107(3):268–275. [https://doi.org/10.1016/s0889-5406\(95\)70142-7](https://doi.org/10.1016/s0889-5406(95)70142-7). Mar.
- Caprioglio A, Pastuca R, Zecca PA, et al. Cellular midpalatal suture changes after rapid maxillary expansion in growing subjects: a case report. *Int J Mol Sci.* 2017;18(3). <https://doi.org/10.3390/ijms18030615>. Mar 11.
- Zimring JF, Isaacson RJ. Forces produced by rapid maxillary expansion. 3. forces present during retention. *Angle Orthod.* 1965;35:178–186. [https://doi.org/10.1043/0003-3219\(1965\)035<0178:Fpbrme>2.0.Co;2](https://doi.org/10.1043/0003-3219(1965)035<0178:Fpbrme>2.0.Co;2). Jul.
- Krebs A. Midpalatal suture expansion studies by the implant method over a seven-year period. *Rep Congr Eur Orthod Soc.* 1964;40:131–142.
- Timms DJ, Moss JP. An histological investigation into the effects of rapid maxillary expansion on the teeth and their supporting tissues. *Trans Eur Orthod Soc.* 1971:263–271.
- Wertz RA. Skeletal and dental changes accompanying rapid midpalatal suture opening. *Am J Orthod.* 1970;58(1):41–66. [https://doi.org/10.1016/0002-9416\(70\)90127-2](https://doi.org/10.1016/0002-9416(70)90127-2). Jul.
- Franchi L, Baccetti T, Cameron CG, Kucipal EA, McNamara Jr. JA. Thin-plate spline analysis of the short- and long-term effects of rapid maxillary expansion. *Eur J Orthod.* 2002;24(2):143–150. <https://doi.org/10.1093/ejo/24.2.143>. Apr.
- Geran RG, McNamara Jr. JA, Baccetti T, Franchi L, Shapiro LM. A prospective long-term study on the effects of rapid maxillary expansion in the early mixed dentition. *Am J Orthod Dentofacial Orthop.* 2006;129(5):631–640. <https://doi.org/10.1016/j.ajodo.2005.01.020>. May.
- Asanza S, Cisneros GJ, Nieberg LG. Comparison of Hyrax and bonded expansion appliances. *Angle Orthod.* 1997;67(1):15–22. [https://doi.org/10.1043/0003-3219\(1997\)067<0015:Cohabe>2.3.Co;2](https://doi.org/10.1043/0003-3219(1997)067<0015:Cohabe>2.3.Co;2).
- Cozzani M, Rosa M, Cozzani P, Siciliani G. Deciduous dentition-anchored rapid maxillary expansion in crossbite and non-crossbite mixed dentition patients: reaction of the permanent first molar. *Prog Orthod.* 2003;4:15–22. <https://doi.org/10.1034/j.1600-9975.2002.02034.x>.
- Ugolini A, Cerruto C, Di Vece L, et al. Dental arch response to Haas-type rapid maxillary expansion anchored to deciduous vs permanent molars: a multicenter randomized controlled trial. *Angle Orthod.* 2015;85(4):570–576. <https://doi.org/10.2319/041114-269.1>. 2015/07//.
- Cerruto C, Ugolini A, Di Vece L, Doldo T, Caprioglio A, Silvestrini-Biavati A. Cephalometric and dental arch changes to Haas-type rapid maxillary expander anchored to deciduous vs permanent molars: a multicenter, randomized controlled trial. *J Orofac Orthod.* 2017;78(5):385–393. <https://doi.org/10.1007/s00056-017-0092-2>.

19. Mutinelli S, Manfredi M, Guiducci A, Denotti G, Cozzani M. Anchorage onto deciduous teeth: effectiveness of early rapid maxillary expansion in increasing dental arch dimension and improving anterior crowding. *Prog Orthod.* 2015;16:22. <https://doi.org/10.1186/s40510-015-0093-x>.
20. Cozzani M, Antonini S, Lupini D, Decesari D, Anelli F, Doldo T. A new proposal: a digital flow for the construction of a Haas-inspired rapid maxillary expander (HIRME). *Materials (Basel).* 2020;13(13). <https://doi.org/10.3390/ma13132898>. Jun 28.
21. Haas AJ. The treatment of maxillary deficiency by opening the midpalatal suture. *Angle Orthod.* 1965;35:200–217. [https://doi.org/10.1043/0003-3219\(1965\)035<0200:Ttomdb>2.0.Co;2](https://doi.org/10.1043/0003-3219(1965)035<0200:Ttomdb>2.0.Co;2). Jul.
22. Abdelsalam R, Nucci L, Carrino R, et al. Comparison of palatal volume and surface changes between bone-borne and tooth-tissue-borne maxillary expansion on cone beam computed tomography digital cast models. *Angle Orthod.* 2023;93(3):282–288. <https://doi.org/10.2319/040922-278.1>. Jan 31.