

A child without kneecaps

Question

A 5-year-old boy was referred to the orthopaedic department for genu valgum. During the physical examination, kneecaps could not be seen or palpated bilaterally (Fig. 1). No other clinical abnormalities were found, except for the presence of hypoplastic nails on both thumbs (Fig. 2). In the suspect of nail-patella syndrome (NPS), a pelvic X-ray was performed (Fig. 3). What is the typical finding associated with this condition? (Answer on page 552)

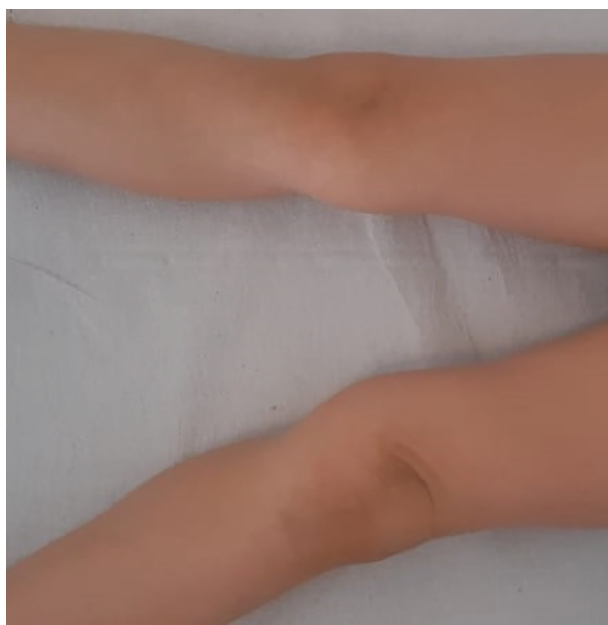





Fig 1 Patient's knees with non-palpable kneecaps.

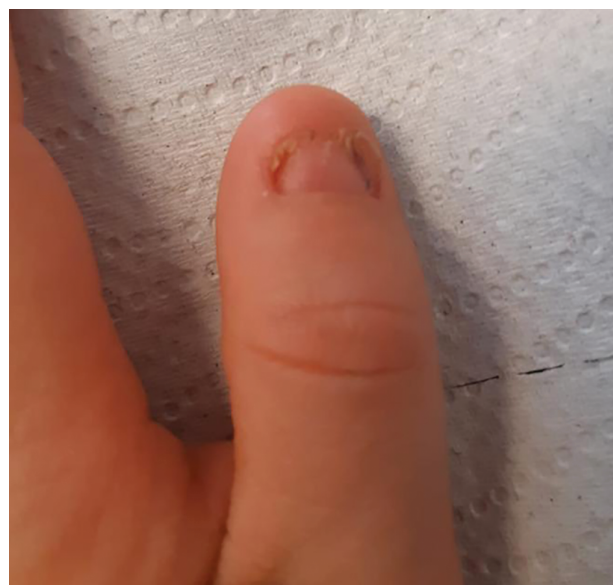

Fig 2 Hypoplastic thumbnail.

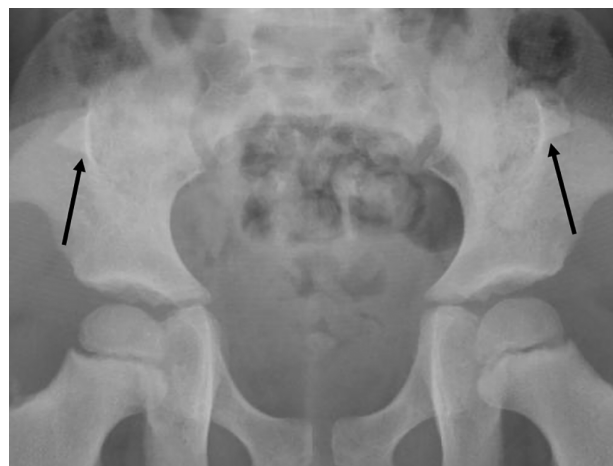

Fig 3 Iliac horns on pelvic X-ray.

Dr Francesco Baldo ¹
 Dr Andrea Magnolato ²
 Dr Irene Bruno ²
 Dr Flavio Faletra ³
 Dr Marco Carbone⁴
 Professor Egidio Barbi ^{1,2}

¹Department of Medicine, Surgery, and Health Sciences,
University of Trieste

Departments of ²Pediatrics, ³Genetics, and ⁴Orthopedics, Institute for
Maternal and Child Health Burlo Garofolo, Trieste, Italy