

## Case Report

# Spontaneous Dural Carotid-Cavernous Fistula Treated with Microcoil Insertion

Alessandro Meduri <sup>1</sup>, Giovanni William Oliverio <sup>1,\*</sup>, Lillina Di Silvestre <sup>2</sup>, Leandro Inferrera <sup>1</sup>, Pier Federico Fiorini <sup>2</sup> and Pasquale Aragona <sup>1</sup>

<sup>1</sup> Ophthalmology Clinic, Department of Biomedical Sciences, University Hospital of Messina, 98124 Messina, Italy

<sup>2</sup> Department of Ophthalmology, Hospital Maggiore, Largo Nigrisoli 2, 40133 Bologna, Italy

\* Correspondence: gioliverio@unime.it

**Abstract:** This report includes a case of a 65-year-old woman presenting with a spontaneous dural carotid-cavernous fistula. Biomicroscopic examination of the anterior segment showed significant conjunctival chemosis, dilatation of the episcleral vessels, narrow anterior chamber, and a proptosis of the right eye, whereas the fellow eye was unremarkable. Retinal examination revealed an impaired arteriovenous ratio (A/V) from 1–4 to 1–2 and two extensive cotton exudates. An ultrasound scan (US) demonstrated congestion of the upper ophthalmic vein. Selective brain angiography through right femoral catheterization revealed a dural fistula of the wall of the cavernous right sinus. The patient underwent surgery on the superior ophthalmic vein and insertion of a micro-catheter in the cavernous sinus under CT guidance. Furthermore, a trans-femoral catheter was placed in the carotid artery on the same side as the fistula to allow arteriographic controls after micro coil positioning and embolization. Angiographic follow-up immediately after positioning the coils showed the occluded fistula and a regular flow circulation between the internal and the external carotid arteries. After treatment, the patient presented a complete resolution of symptoms. Conservative management is effective and safe in treating patients with carotid-cavernous fistula and mild clinical features because of a good chance of spontaneous or secondary thrombosis after arteriographic occlusion.

**Keywords:** carotid-cavernous fistula; episcleral stasis; interventionist neuroradiology

**Citation:** Meduri, A.; Oliverio, G.W.; Di Silvestre, L.; Inferrera, L.; Fiorini, P.F.; Aragona, P. Spontaneous Dural Carotid-Cavernous Fistula Treated with Microcoil Insertion. *Appl. Sci.* **2022**, *12*, 10103. <https://doi.org/10.3390/app121910103>

Academic Editor: Qi-Huang Zheng

Received: 22 July 2022

Accepted: 4 October 2022

Published: 8 October 2022

**Publisher's Note:** MDPI stays neutral with regard to jurisdictional claims in published maps and institutional affiliations.



**Copyright:** © 2022 by the authors. Licensee MDPI, Basel, Switzerland. This article is an open access article distributed under the terms and conditions of the Creative Commons Attribution (CC BY) license (<https://creativecommons.org/licenses/by/4.0/>).

## 1. Introduction

An arteriovenous fistula is an abnormal connection between artery and vein; the blood contained in these veins becomes arterialized, venous pressure increases, and venous flow is altered in speed and direction [1]. The clinical picture resulting in alteration of vascular dynamics is characterized by reduction of arterial perfusion, ocular hypoxia, and venous congestion.

Carotid-cavernous fistula (CCF) is an abnormal connection between the carotid arterial system (internal carotid artery and/or external carotid artery) and cavernous sinus.

According to the Barrow classification, CCFs are classified as direct (type A) and indirect (type B, C, and D) types [1,2].

Direct CCF, characterized by a direct connection between the internal carotid artery and cavernous sinus, are commonly post-traumatic [1,2].

Indirect carotid-cavernous fistula, also known as dural fistula of the cavernous sinus, is a special type of dural arteriovenous fistula where the immediate venous drainage is into the cavernous sinus [1,2]. Based on angiographic characteristics, dural fistula of cavernous sinus are classified into type B (the connection between dural branches of the internal carotid artery with cavernous sinus), type C (the connection between dural branches of the external carotid artery with cavernous sinus), and type D (the fistulous

connection between dural branches of both internal and external carotid artery with cavernous sinus). Type B is the least common, whereas type D is the most commonly observed in clinical practice [1,2].

The etiology of the indirect carotid-cavernous fistula is not completely known; however, these could be associated with arterial hypertension, cerebral arteriosclerosis, diabetes, collagen diseases (Ehlers–Danlos syndrome, collagenosis), and post-menopausal age in women [1–3].

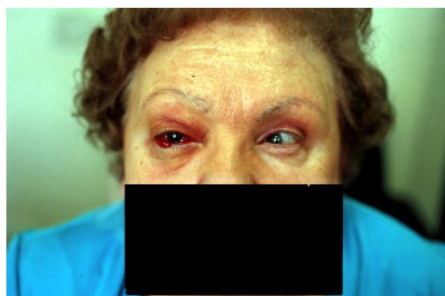Although dural carotid-cavernous fistula could be approached with conservatory therapy, untreated patients could present severe ocular and neurological complications, in particular the presence of ocular risk factors, such as increased intraocular pressure (IOP), retinal ischemia, and optic nerve edema [3].

The advent of endovascular treatments significantly reduced the morbidity related to cavernous carotid fistula.

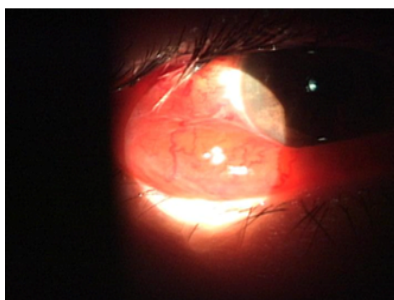
In this report, we describe a case of spontaneous dural carotid-cavernous fistula that occurred in a healthy woman, successfully treated with endovascular micro coil insertion.

## 2. Case Report

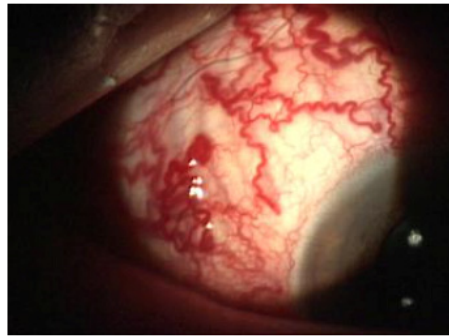
A 65-year-old woman presented to our attention complaining of two days of swelling in the right eye, reduced visual acuity, diplopia, and mild pain. The history was negative for recent trauma and confirmed good general health conditions. The physical examination revealed complete ophthalmoplegia (Figure 1), non-pulsatile reducible axile exophthalmos, eyelid edema, significant chemosis, and conjunctival ectropion (Figure 2). Visual acuity at the time of admission was 5/10 in the right eye and 10/10 in the left eye. The biomicroscopic examination of the anterior segment showed an important stasis of the episcleral vessels (Figure 3) and a shallow anterior chamber, whereas the fellow eye was unremarkable.



**Figure 1.** Exophthalmos and ophthalmoplegia in right eye.

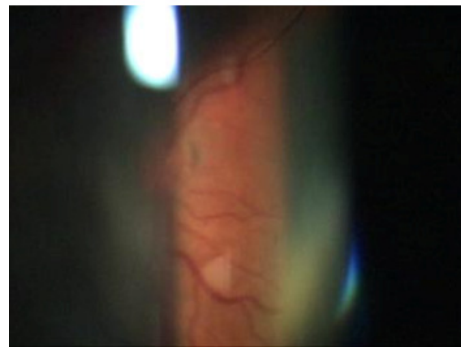


**Figure 2.** Extensive conjunctival chemosis.



**Figure 3.** Dilatation of the episcleral vessels.

Fundus examination showed an alteration of the normal arterio-venous ratio (A/V) from 1–4 to 1–2 and two extensive cotton exudates at the posterior pole (Figure 4).



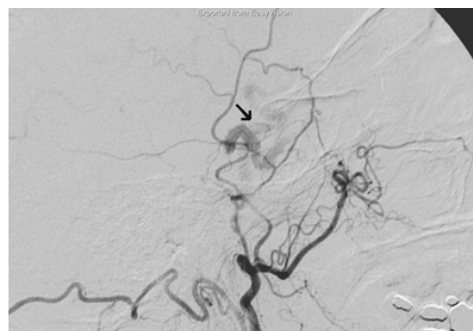
**Figure 4.** Retinal cotton exudates.

The intraocular pressure (IOP) was 30 mmHg in the right eye and 12 mmHg in the left eye.

To reduce the IOP, the patient was suddenly treated with intravenous 18% Mannitol, topical Timolol Maleate 5 mg/mL, and Dorzolamide 20 mg/mL drops twice a day.

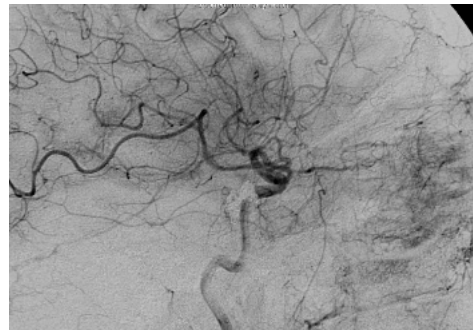
Furthermore, US showed congestion at the level of the superior ophthalmic vein.

The selective cerebral angiography (Figure 5), carried out through right femoral catheterization, revealed a dural fistula of the right cavernous sinus wall between the branches of the internal maxillary artery, most likely of the accessory meningeal artery, and the cavernous sinus with early opacification of the ophthalmic vein that presented an increased caliber.



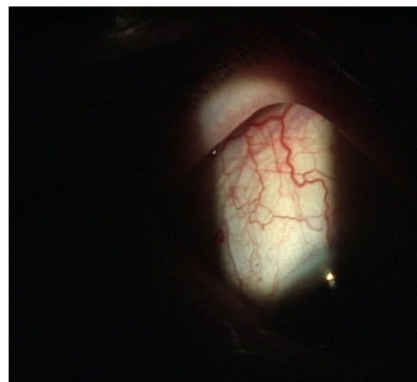
**Figure 5.** The selective cerebral angiography revealing a dural fistula of the right cavernous sinus (arrow).

The multidisciplinary team involved in this case comprised neurosurgeons and interventional neuroradiologists. The treatment decided was carried out two times; the first provided the insertion of a cannula needle in the right orbital vein by a trans-palpebral anterior approach, while the second provided for the embolization of the cavernous sinus seat of the venous part of the fistula, through the placement of 5 spirals (Vortex 2x5, Boston), up to the complete exclusion of the fistula. The angiographic control performed immediately after the affixing of the spirals showed the complete normalization of the circulation between the internal and external carotid (Figure 6).

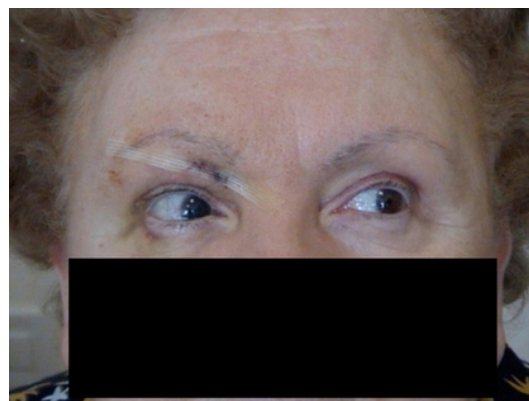


**Figure 6.** The selective cerebral angiography revealing a dural fistula of the right cavernous sinus (arrow).

On the third post-operative day, the clinical condition was significantly improved in the following ways: a clear reduction of the exophthalmos and the congestion of the episcleral vessels (Figure 7), a complete recovery of ocular motility (Figure 8), visual acuity improved to 10/10, IOP was 14 mmHg, the disappearance of cotton exudates, and a normalization of the A/V ratio. Fifteen days after the surgery, the ocular conditions were stable.



**Figure 7.** Resolution of the dilatation of the episcleral vessels, exophthalmos, and ophthalmoplegia.



**Figure 8.** Resolution of the dilatation of the episcleral vessels, exophthalmos, and ophthalmoplegia.

### 3. Discussion

Dural fistulas represent a challenging disease to treat, either because of the difficulty of a prompt diagnosis or because of the difficulty of the intervention dictated by the size and tortuosity of the vessels and, not least, the difficulty of coordinating the multidisciplinary team [1,2].

All these problems must be promptly overcome in order to have integrative restitution of the whole visual apparatus.

Ophthalmologists are often the first doctors to come into contact with patients with carotid-cavernous fistula, and they should recognize and indicate the necessary examinations in a timely manner. The typical clinical manifestations are: unilateral proptosis, the tumescence of the eyelid, conjunctival chemosis, caput medusae, pulsation of the eyeball (always observed in direct fistula), increased IOP, and diplopia. Furthermore, these clinical features should be differentiated into endocrine orbitopathy, orbital-cellulitis, posterior scleritis, thrombosis of the sinus cavernous, and malignancies.

In some cases, when the diagnosis is delayed, the visual functionality could be irreparably damaged, with severe ocular and neurological complications [1,2].

A conservative approach could be indicated for patients with few clinical signs, in particular for indirect fistula, because of a good chance of spontaneous occlusion of the fistula; however, it is also necessary to ensure regular observation of psycho-physical functions, IOP, and the ocular fundus [4–7].

In our case, the increased IOP and the ischemic retinal features justified the urgency of treatment aimed at prompt fistula occlusion.

Currently, the most common treatment is endovascular embolization using means of spirals, detachable flasks, and, as a last resort given the side effects (such as diffuse thrombosis and post-operative inflammatory reaction), the use of a sclerotic substance [8–10].

Transvenous via through the inferior petrosal sinus is the most common approach; however, when this access is absent for anatomical variations or thrombosis, direct access to the superior ophthalmic vein represents an alternative technique. Heran et al., in a recent study, reported successful results of imaging-guided percutaneous superior ophthalmic vein access in 20 patients with carotid-cavernous fistula treatment [10].

In conclusion, our case demonstrated that a prompt diagnosis and multidisciplinary management are essential for clinical resolution and to preserve the visual function of the patient.

**Author Contributions:** Conceptualization, P.F.F. and L.D.S.; methodology, G.W.O.; investigation, P.F.F. and L.D.S.; resources, A.M.; data curation, L.I.; writing—original draft preparation, G.W.O.; writing—review and editing, G.W.O. and A.M.; supervision, A.M. and P.A. project administration, P.A.; funding acquisition, A.M. All authors have read and agreed to the published version of the manuscript.

**Funding:** The authors did not receive any financial support from any public or private sources. The authors have no financial or proprietary interest in a product, method, or material described.

**Informed Consent Statement:** Informed consent was obtained from all subjects involved in the study.

**Conflicts of Interest:** The authors declare no conflict of interest.

### References

1. Ke, L.; Yang, Y.-N.; Yuan, J. Bilateral carotid-cavernous fistula with spontaneous resolution: A case report and literature review. *Medicine* **2017**, *96*, e6869.
2. Henderson, A.D.; Miller, N.R. Carotid-cavernous fistula: Current concepts in aetiology, investigation, and management. *Eye* **2018**, *32*, 164–172.
3. Guo, H.; Yin, Q.; Liu, P.; Guan, N.; Huo, X.; Li, Y. Focus on the target: Angiographic features of the fistulous point and prognosis of transvenous embolization of cavernous sinus dural arteriovenous fistula. *Interv. Neuroradiol.* **2018**, *24*, 197–205.

4. Feiner, L.; Bennett, J.; Volpe, N.J. Spontaneous carotido-cavernous fistulas: Phlebographic appearance. *Curr. Neurol. Neurosci. Rep.* **2003**, *3*, 415–420.
5. De Keizer, R. Carotid-cavernous and orbital arteriovenous fistulas: Ocular features, diagnostic and hemodynamic considerations in relation to visual impairment and morbidity. *Orbit* **2003**, *22*, 121–142.
6. Jozef, Č. Carotid-cavernous fistula from the perspective of an ophthalmologist A Review. *Czech Slovak Ophthalmol.* **2019**, *76*, 203–210. <https://doi.org/10.31348/2020/8>.
7. Fattahi, T.T.; Brandt, M.T.; Jenkins, W.S.; Steinberg, B. Traumatic carotid—Cavernous fistula: Pathophysiology and treatment. *J. Craniofacial Surg.* **2003**, *14*, 240–246.
8. Gioulekas, J.; Mitchell, P.; McNab, A.A. Embolization of carotid cavernous fistulas via the superior ophthalmic vein. *Aust. N. Z. J. Ophthalmol.* **1997**, *25*, 47–53.
9. Lim NC, Lin HA, Ong CK, Sundar G. Treatment of Dural Carotid-Cavernous Fistulas via the Medial Ophthalmic Vein. *Orbit.* **2015**;34(6):345-50.
10. Heran, M.K.S.; Volders, D.; Haw, C.; Shewchuk, J.R. Imaging-Guided Superior Ophthalmic Vein Access for Embolization of Dural Carotid Cavernous Fistulas: Report of 20 Cases and Review of the Literature. *AJNR Am. J. Neuroradiol.* **2019**, *40*, 699–702.

