

Central Mound Technique in Oncoplastic Surgery: A Valuable Technique to Save Your Bacon

Chiara Stocco,¹ Vito Cazzato,¹ Nadia Renzi,² Mariastella Manara,²
Vittorio Ramella,² Serena Scomersi,³ Margherita Fezzi,³ Marina Bortul,^{1,3}
Zoran Marj Arnez,^{1,2} Giovanni Papa^{1,2}

Abstract

Breast-conserving surgery (BCS) is a valid method for the reconstruction of partial breast defects, however, there is a great variety of final aesthetic outcomes depending on the location of the tumor in the breast and also on the initial breast volume and the degree of ptosis. Specifically, defects affecting the upper inner/central quadrant represent a reconstructive challenge with not always satisfactory final results. For this purpose, the authors investigated the use of the central mound technique in BCS. This technique is widely applied for breast reduction, but it has never been used to achieve volume displacement after breast cancer excision. The aim of the study was to apply the central mound as an oncoplastic technique and assess the satisfaction rate of the patients with pre- and postoperative (3 months and 9 months) Breast-Q questionnaire (breast conserving therapy module). After 9 months the author found a major increase of all BREAST-Q parameters. None of the patients experienced a decreased in the quality of life related to the surgical procedure. The authors believe that this technique has useful functional and aesthetic results particularly appreciated by patients who have a slightly or moderately breast ptosis and a small cup size.

Introduction: Breast-conserving surgery (BCS) is a valid method for the reconstruction of partial breast defects, however, there is a great variety of final aesthetic outcomes depending on the location of the tumor in the breast and also on the initial breast volume and the degree of ptosis. Specifically, defects affecting the upper inner/central quadrant represent a reconstructive challenge with not always satisfactory final results. For this purpose, the authors investigated the use of the central mound technique in breast-conserving surgery. The aim of the study was to apply the central mound as an oncoplastic technique and assess the satisfaction rate of the patients. **Materials and Methods:** This was a retrospective study that involved 40 patients (80 breast) underwent breast conserving surgery and contextual bilateral breast remodeling with central mound technique. A pre- and postoperative Breast-Q questionnaire (breast conserving therapy module) was given to all the patients before the surgery, 3 months and 9 months after. The statistical analysis with chi-square test was performed. **Results:** After 9 months the author found a major increase of all BREAST-Q parameters; the most valuable increments concerned the “Satisfaction with breast” and “Psychosocial well-being.” None of the patients experienced a decreased in the quality of life related to the surgical procedure. **Conclusion:** The authors believe that this technique has useful functional and aesthetic results particularly appreciated by patients with upper pole lesion who have a slightly or moderately breast ptosis and a small cup size.

Introduction

Breast-conserving surgery (BCS) and oncoplastic surgery with subsequential radiotherapy has become a valid alternative to mastectomy for breast cancer, in selected patients with the correct indication. Oncoplastic surgery is defined as a method to reconstruct partial breast defects following tumor resection.^{1,2} This approach

¹Department of Medicine, Surgery and Health Sciences, University of Trieste, Trieste, Italy

²Department of Plastic and Reconstructive Surgery, Azienda Sanitaria Universitaria Giuliano-Isontina, Trieste University Hospital, Trieste, Italy

³Department of General Surgery, Azienda Sanitaria Universitaria Giuliano-Isontina, Trieste University Hospital, Trieste, Italy

Figure 1 Intraoperative detail after upper pole quadrantectomy

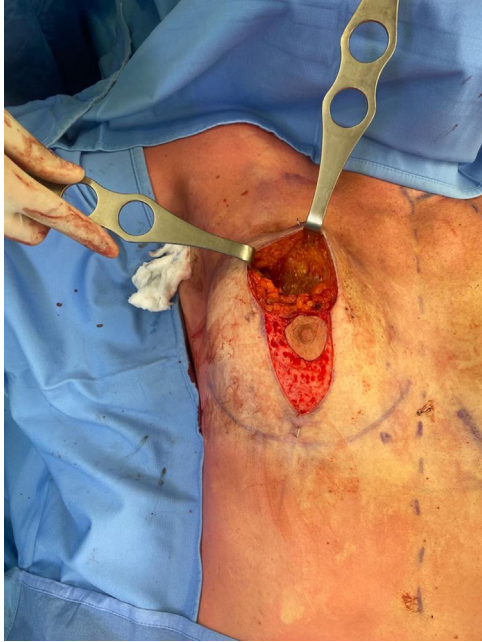
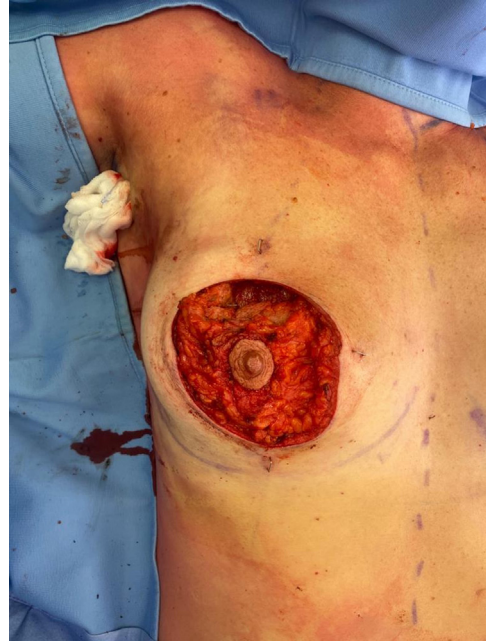
Figure 2 Intraoperative detail after mobilization of the gland based on its central pedicle



proved to be valuable and safe and to add several advantages both from the oncologic and reconstructive point of view and has amplified its popularity and use compared to breast-conserving surgery alone.³⁻⁵

From an anatomical analysis, the gland and breast skin are vascularized from the thoracoacromial artery, internal mammary perforators (60% of the overall breast perfusion), lateral thoracic artery, intercostal perforators, and thoracodorsal artery⁶ Several surgical approaches and variations have been reported regarding the reduction mammoplasty, each relying on different vascular pedicles.⁷⁻¹⁰

However, in a variable percentage of patients undergoing breast-conserving/oncoplastic surgery the aesthetic outcome is considered not satisfactory.¹¹ The reasons of this dissatisfaction can be attributed to different factors, ranging from the preoperative breast appearance and surgical indication to the postoperative effect of the radiotherapy, through the overall healing process and breast symmetry. In addition, the tumor location can play a fundamental role on the type of oncoplastic technique to be used and on the global final aspect of the breast. For all these reasons, it is important that the approach is a combined general surgeon and plastic surgeon one, as the extensive knowledge of the gland vascularization after tumor excision is even more crucial in in this type of breast surgery.

To this extent, the central mound technique, first described in 1981 and mainly applied for breast reduction, has been a topic of increased recent interest in the literature.¹²⁻¹⁴ This surgical approach can be even more useful when dealing with breast-conserving surgery specifically when treating tumors located in the upper pole

of breast. In these scenarios the breast volume displacement that can be done with the most used nipple-areola complex pedicle (superior, supero-medial, supero-lateral, inferior) cannot always guarantee the upper pole fullness or contour preservation.

The present study is the first that exploits the use of the central mound technique in breast-conserving surgery in tumors located in the upper pole in order to obtain a safe, pleasant and reliable breast reconstruction.

The aim of the study was to apply the central mound as an oncoplastic technique and assess the surgical outcome along with the satisfaction rate of the patients.

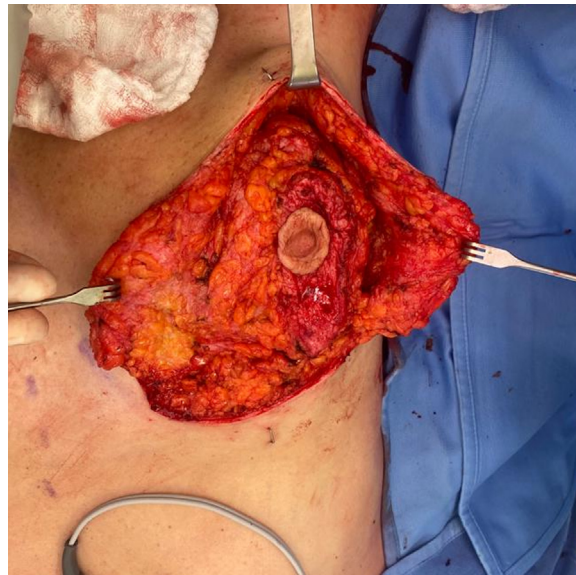Patients and Methods

From January 2020 to June 2021, all patients with indication for breast-conserving surgery and oncoplastic reconstruction with malignant breast tumor located in the upper breast pole were enrolled. During the same surgery, both the affected and the non-affected breasts were treated with the central mound technique, allowing for a simultaneous contralateral breast symmetrization.¹⁵ Bilateral central mound mastopexy/breast reduction was performed using the periareolar/vertical/wise pattern approach, tailored for each patient.

Before the surgery, all the patients were radiologically marked allowing for a precise tumor location and the day prior to the surgery they received the lymphoscintigraphy to identify the sentinel node (as per standard protocol).

During the surgery, specimens were sent for histopathologic exam and clear margins were also confirmed on the definitive pathologic

Figure 3 Intraoperative detail: the same technique is carried out on the contralateral side



report (within 1 month from the surgery). All patients underwent radiation therapy on the breast cancer side, as per standard protocol. Patients' demographics and comorbidities, operative details, postoperative complications were recorded. In addition, a pre- and postoperative Breast-Q questionnaire (breast conserving therapy module) was given to all the patients before the surgery, 3 months and 9 months after and the following parameters were analyzed: wellbeing social setting, sexual well-being pre-post, physical wellbeing of the chest, satisfaction with breasts. The statistical analysis with χ^2 test was performed.

Operating Technique

Under general anesthesia, the patients underwent the tumor excision phase performed by the accredited oncologic breast surgeon, and the sentinel node biopsy. At the same time, the plastic surgeon started to de-epithelialized the nonaffected breast, following the preoperative markings. Once that the clear margin confirmation arrived, the plastic surgeon started to mobilize the breast gland of the affected side using the central mound technique. Instead of removing the whole circular area around the gland as described for the aesthetic approach,¹⁶ the skin was detached from the gland leaving the glandular tissue to be attached only on its deep (central) surface. Surgical clips were positioned at the 4 margins of the excision and on the deep surface (as per standard procedure, allowing for the precise location of the tumor excision for the radiological follow-up). The glandular tissue was therefore moved with no tension allowing for a proper breast volume replacement with no distortion. On the nonaffected breast, the amount of glandular tissue to be removed in order to gain the best symmetry was then assess and the same technique was performed. All the specimens were weighted in the operating room and sent for histopathology report. (see [Figures 1, 2, 3, 4](#))

Results

From January 2020 to June 2021 a total of 40 patients underwent breast conserving surgery and contextual bilateral breast remodeling with central mound technique (80 breasts). The mean patients age was 46, (range 32-58 years old) and the average body mass index was 24.1 (range 19-27,3). The average breast tissue removed was 37 gr on the tumor side and 31 gr on the healthy breast. Mean follow-up time was 11 months (range 8-18 months). All the patients' variables examined are listed in [Table 1](#).

Three breast seromas and 1 hematoma were reordered and were all treated conservatively. There were 2 cases of fibrotic retraction after radiotherapy, which did not change patient satisfaction. No other minor nor major complications were encountered (nipple/skin necrosis, asymmetry, infection, etc).

The most frequently breast cancer histotype was the invasive carcinoma of no special type, followed by the in situ ductal 1; 3 out of 40 patients underwent monolateral axillary node dissection.

All patients received adjuvant radiotherapy (with an average radiation dosage of 45.8 Gy and an average number of sessions of 18); 17 patients underwent chemotherapy after the surgery.

In 3 cases the definitive histopathology report showed tumor close margins, that were not detected with intraoperative assessment of margins; therefore, these 3 patients were brought back to the operating room for widening of the margins (mean time after first surgery 20 days – ranging 15-30 days) ([Table 2](#)).

Analyzing the Breast-Q questionnaire, 3 months after surgery, all the subjective parameter showed an increase, except for the physical well-being of the chest that showed a slight drop since preoperative value. In line with the preliminary results, after 9 months, we found a major increase of all BREAST-Q parameters ([Table 3](#)). The most valuable increments concerned the “Satisfaction with breast” and

Figure 4 Immediate postoperative picture showing no contour deformity especially in the lateral projection, after central mound mobilization of the gland and suture of the upper breast margins

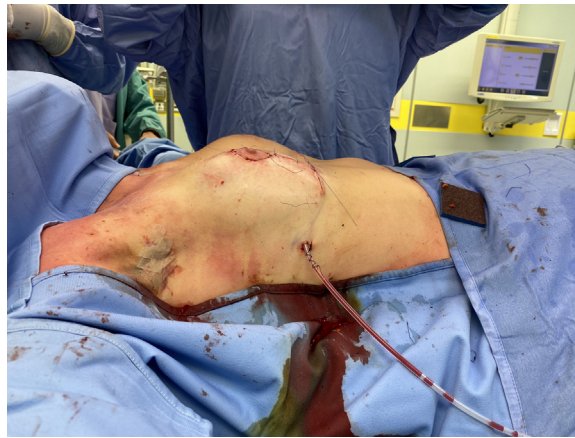

Table 1 Patients' Demographic and Characteristics

Mean age	46 (range 32-58)
BMI	24.1 (19-27,3)
Total breast	80 breasts (40 patients)
Right breast cancer side	24 patients
Left breast cancer side	16 patients
Mean cup size	
A	31%
B	39%
C	23%
D	7%
Smokers	8
Comorbidities	2 diabetics 17 overweights 3 T. Hashimoto
Ptosis classification (sec. Regnault)	
Normal	10
I	9
II	19
III	2

“Psychosocial well-being.” None of the parameters showed a statistical significance evidence but the trend showed an improvement trend.

Discussion

Selection criteria regarding the indication for breast-conserving/oncoplastic surgery have been widely described and investigated. The plastic surgery technique that can be performed can be divided into 2 major categories: volume displacement and volume replacement.

To date various technique for partial breast reconstruction have been described. The oncoplastic approach proved to be valid and to

provide excellent results and the plastic surgery technique to be used range from mastopexy to reduction patterns.¹⁷

Is it of fundamental importance that the onco-breast surgeon and the plastic surgeon work as a multidisciplinary team, sharing the indication regarding the surgery and, possibly, performing the surgery together (from the demolition to the reconstruction). In this way a real multidisciplinary approach is possible, and it is the only condition that can lead to an improved overall long-term result with 360 degrees care of the oncologic breast patient: both general and plastic surgeon share the surgical indication, the surgical procedure, the postoperative long-term follow-up.

One of the main concerns regarding the reconstructive part is the necessity to obtain a pleasant breast shape and to avoid nipple-areola necrosis. Safe and effective maintenance of a robust blood supply to the nipple is mandatory and even more critical than in the common aesthetic procedures (mastopexy/breast reduction) as the nipple vascularization can be even more impaired due to the tumor resection.¹⁸

In this regard, when dealing with tumors located in the upper pole, especially in small/medium sized breast,¹⁹ the difficulty regarding the best reconstructive option is even more challenging.

The central mound reduction technique has, among its advantages, the characteristic of being supplied from multiple sources. The base (deep plane) is never violated and for this reason it holds the perforators from the internal mammary, intercostal, thoracoacromial, and some branches of the lateral thoracic arteries. Since these vascular peculiarities, the central mound technique is a tool of fundamental importance in the oncoplastic surgery, where the risk of nipple-areola necrosis is higher than in the standard breast reduction/mastopexy.

The central mound approach applied in the oncoplastic field has the following significant advantages:

- It allows for a safe, reliable, and pleasant reconstruction, especially in patients where the tumor is located in the upper pole, in small/medium sized breast.

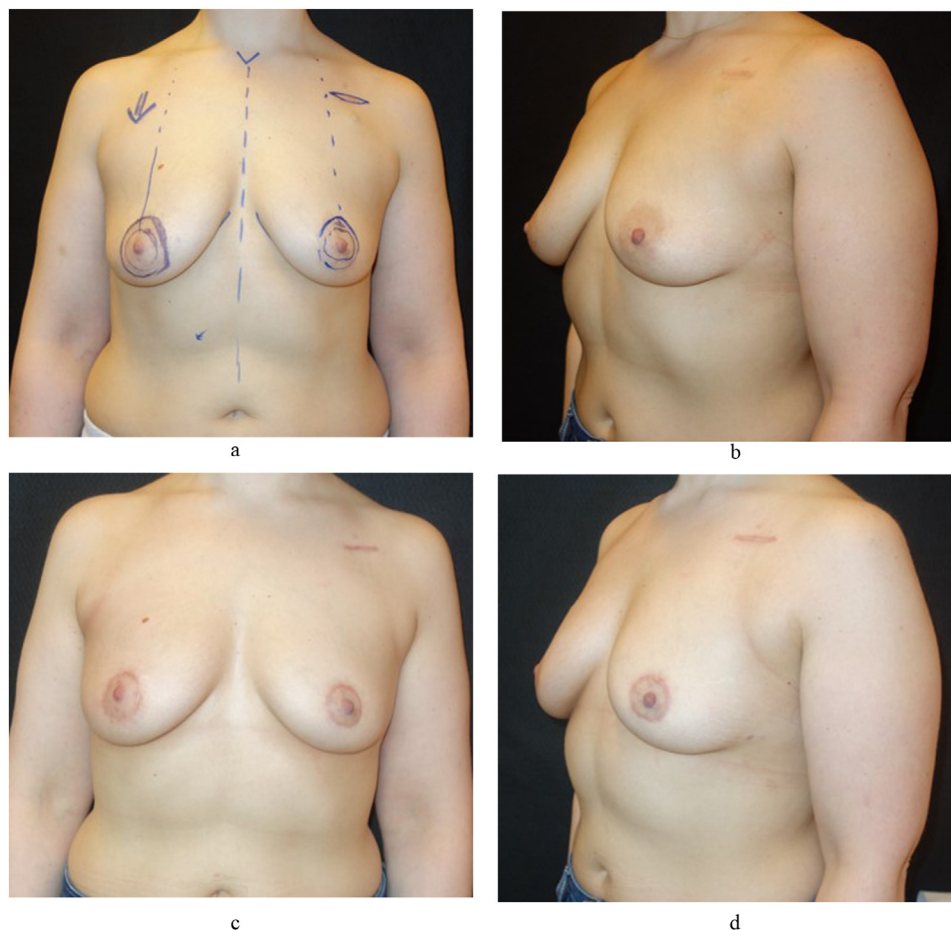
Table 2 Surgical Details

Mean gland removal (tumor side)	37 gr (range 14-73)
Mean gland removal (non-affected side)	31 gr (range 15-69)
Type of tumor	29 invasive carcinoma of no special type 10 in situ ductal 1 Papillary carcinoma
Seroma	3
Hematoma	1
Infections	0
Partial NAC necrosis	0
Total NAC necrosis	0
Follow-up (months)	11 mo (range 8-18 mo)
Adjuvant CT	17

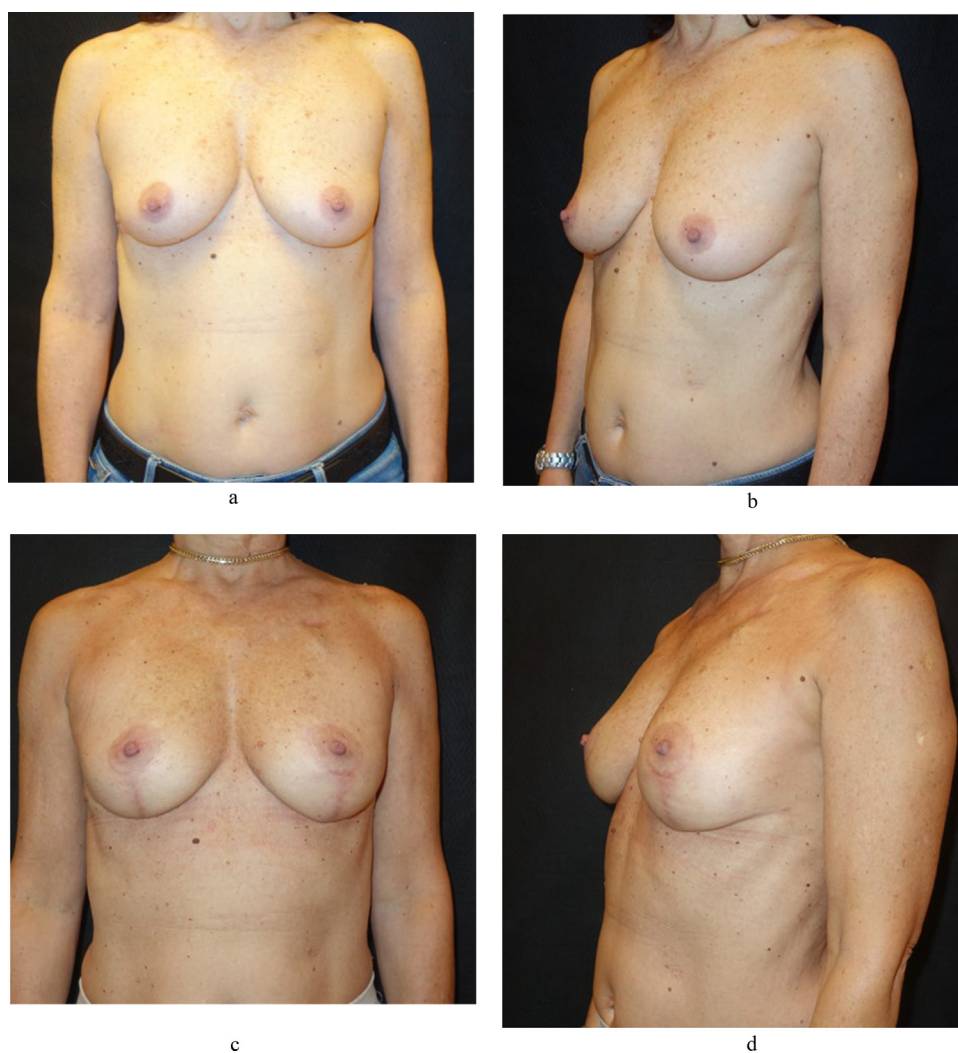Figure 5 Cancer of the inner-upper pole of the right breast; preoperative frontal views (5A, 5B) and results after 12 months follow-up

Table 3 Breast-Q Questionnaire Results

Breast Q Questions	Scores (mean)				
	Preoperative	After 3 Mo	p Value	After 9 Mo	p Value
Psychosocial well-being	63,29	72,16	NS	82,78	NS
Sexual well-being	58,15	60,89	NS	72,13	NS
Satisfaction with breast	61,36	74,25	NS	86,52	NS
Physical well-being: chest	71,71	66,1	NS	77,33	NS

Figure 6 Six months after right central upper quadrantectomy, bilateral periareolar central mound and porth-a cat removal before (6A, 6B) and after (6C, 6D)

- It is suitable for all the breasts.
- All the type of skin pattern can be applied (periareolar/vertical/inverted T scar) based on the appearance and cup size of the breast.
- Since the glandular remodeling is limited compared to the other techniques, it is easier and very straightforward to retrieve the specific tumor site in case of the presence of close/involved margins in the definitive histopathology response (with no doubt regarding the margin to be treated) and the need for reintervention for margins widening of the margins.

- Wide skin undermining allows for a re-shape of the breast skin envelope in a precise and controlled manner
- Limited glandular remodeling preserves glandular blood supply and protects breast tissue from fat necrosis after radiotherapy. It also allows a precise and oncological safe reoperation procedure in case of involved margins.
- An internal parenchyma mastopexy is usually possible, suturing the upper pole of the breast mound to the pectoralis major fascia.
- The skin closure is tension-free because the skin flaps do not carry the weight of supporting the new breast mound.

There are no real contraindications for this surgical approach, as long as the breast conserving indication is correct. In our experience, we prefer not to perform oncoplastic procedure in patients affected by lobular cancer, due to the difficult preoperative correct tumor extension and due to the probability to have or to develop a contralateral malignant lesion.

Concerning the effectiveness of the central mound technique, several studies demonstrated the validity and safety of this procedure, even in previously irradiated breasts.²⁰⁻²³ In our series, we observed a substantial satisfaction in the appearance questions from the BREAST-Q breast conserving therapy module (asked on a Likert like scale ranging from 1 to 5). (Figure 5 A, B, C, D)

All the parameters assessed (social setting well-being, sexual well-being, pre- and postoperative satisfaction with breasts, physical well-being of the chest) showed an increased or maintained overall feeling and social life. None of the patients experienced a decreased in the quality of life related to the surgical procedure. Moreover, the substantial increase of psychosocial well-being and of breast satisfaction showed that this technique has useful functional and aesthetic results particularly appreciated by patients who have a slightly or moderately breast ptosis and a small cup size. (Figure 6 A, B, C, D)

Three out of 40 patients underwent monolateral axillary node dissection and among these, 2 reported mild discomfort of the upper affected arm, with no signs or symptoms of lymphedema.

Even though a statistical analysis and comparison between different technique is not possible (mainly due to patients' differences, different type of tumors, different tumors locations, amount of resected tissue), in the present study, we recorded a lower complication rate (especially regarding the seroma rate and the partial/total NAC necrosis) compared to that than can be encountered in our institutional experience and that previously described in other studies.^{24,25,14,26}

The data we provide do not permit a final comparison between the central mound oncoplastic approach and all the other approaches but they supply evidence that it represents a safe, valid, reliable, and consistent alternative for oncoplastic breast approach.

The limit of the study is represented by the relatively small cohort of patients, due also to the need of placing the right onco-plastic indication; further evaluation will be required to assess advantages and disadvantaged compared to other techniques.

Conclusions

The central mound oncoplastic approach offers a safe, reliable, and long-lasting result, especially in patient with tumor localization in the upper pole in small to moderate breast size. It is the result of a combined breast surgeon-plastic surgeon surgical plan. Benefits of this approach include a versatile shaping of the breast but, above all, the possibility to identify the exact area in which the tumor was located, even after the remodeling phase. Further research is needed to compare the outcome of this approach to alternative reduction/mastopexy techniques.

Clinical Practice Points

- The study applies the use of the central mound technique in oncoplastic surgery and evaluates its effectiveness assessing satisfaction rate of the patients. - The central mound oncoplastic approach

offers a safe, reliable, and long-lasting result, especially in challenge patient with tumor localization in the upper pole in small to moderate breast size.

Acknowledgments

The authors have no commercial associations with or financial interests in any of the drugs, products, devices, or instruments used in this study.

Disclosure

The authors have stated that they have no conflicts of interest.

References

1. Audretsch WP, Rezaei M, Kolotas C, Zamboglou N, Schnabel T, Bojar H. Tumor-specific immediate reconstruction in breast cancer patients. *Semin Plast Surg.* 1998;11:71-100.
2. Clough KB, Cuminet J, Fitoussi A, Nos C, Mosseri V. Cosmetic sequelae after conservative treatment for breast cancer: classification and results of surgical correction. *Ann Plast Surg.* 1998;41:471-481.
3. McIntosh J, O'Donoghue JM. Therapeutic mammoplasty—a systematic review of the evidence. *Eur J Surg Oncol.* 2012;38:196-202.
4. De La Cruz L, Blankenship SA, Chatterjee A, Geha R, Nocera N, Czerniecki BJ, et al. Outcomes after Oncoplastic breast-conserving surgery in breast cancer patients: a systematic literature review. *Ann Surg Oncol.* 2016;23:3247-3258.
5. Losken A, Styblo TM, Carlson GW, Jones GE, Amerson BJ. Management algorithm and outcome evaluation of partial mastectomy defects treated using reduction or mastopexy techniques. *Ann Plast Surg.* 2007;59:235-242.
6. Jesinger RA. Breast anatomy for the interventionalist. *Tech Vasc Interv Radiol.* 2014;17:3-9.
7. Matarasso A. Suction mammoplasty: the use of suction lipectomy alone to reduce large breasts. *Clin Plast Surg.* 2002;29:433-443.
8. Spear SL, Howard MA. Evolution of the vertical reduction mammoplasty. *Plast Reconstr Surg.* 2003;112:855-868.
9. Ramirez OM. Reduction mammoplasty with the "owl" incision and no undermining. *Plast Reconstr Surg.* 2002;109:512-522 discussion 523-524.
10. Abramo AC. A superior vertical dermal pedicle for the nipple- areola: an alternative for severe breast hypertrophy and ptosis. *Aesthetic Plast Surg.* 2012;36:134-139.
11. D'Aniello C, Grimaldi L, Barbato A, Bosi B, Carli A. Cosmetic results in 242 patients treated by conservative surgery for breast cancer. *Scand J Plast Reconstr Surg Hand Surg.* 1999;33:419-22.
12. Balch CR. The central mound technique for reduction mammoplasty. *Plast Reconstr Surg.* 1981;67:305-311.
13. Hester Jr TR, Bostwick J III, Miller L, et al. Breast reduction utilizing the maximally vascularized central breast pedicle. *Plast Reconstr Surg.* 1985;76:890-900.
14. See MH. Central pedicle reduction mammoplasty: a reliable technique. *Gland Surg.* 2014;3:51-54.
15. Deigni OA, Baumann DP, Adamson KA, et al. Immediate contralateral mastopexy/breast reduction for symmetry can be performed safely in oncoplastic breast-conserving surgery. *Plast Reconstr Surg.* 2020;145:1134-1142.
16. DeLong MR, Chang I, Farajzadeh M, et al. The central mound pedicle: a safe and effective technique for reduction mammoplasty. *Plast Reconstr Surg.* 2020 Oct;146(4):725-733.
17. Clough KB, Lewis JS, Couturau B, Fitoussi A, Nos C, Falcou MC. Oncoplastic techniques allow extensive resections for breast-conserving therapy of breast carcinomas. *Ann Surg.* 2003;237:26-34.
18. American Society of Plastic Surgeons. 2017 Plastic surgery statistics report. Available at: <https://www.plasticsurgery.org/documents/News/Statistics/2017/plastic-surgery-statistics-full-report-2017.pdf>.
19. Gillies H, Marino H. The "periwinkleshell" principle in the treatment of the small ptotic breast. *Plast Reconstr Surg.* 1958;21:1-7.
20. Swanson E. A review and measurement study of the central mound pedicle for breast reduction. *Plast Reconstr Surg Glob Open.* 2021;9:e3615.
21. Weichman KE, Urbinelli L, Disa JJ, Mehrara BJ. Breast reduction in patients with prior breast irradiation: outcomes using a central mound technique. *Plast Reconstr Surg.* 2015;135:1276-1282.
22. Parrett BM, Schook C, Morris D. Breast reduction in the irradiated breast: evidence for the role of breast reduction at the time of lumpectomy. *Breast J.* 2010;16:498-502.
23. Tenna S, Morelli Coppola M, Salzillo R, et al. Delayed mastopexy following breast-conserving surgery and radiation therapy: a case-control study to evaluate safety and versatility of the central mound technique. *Aesthetic Plast Surg.* Oct 2022;46(5):2164-2173. doi:10.1007/s00266-021-02615-7.
24. Ogunleye AA, Leroux O, Morrison N, Preminger AB. Complications after reduction mammoplasty: a comparison of Wise pattern/inferior pedicle and vertical scar/superomedial pedicle. *Ann Plast Surg.* 2017;79:13-16.

25. Bauermeister AJ, Gill K, Zuriarrain A, Earle SA, Newman MI. Reduction mammoplasty with superomedial pedicle technique: a literature review and retrospective analysis of 938 consecutive breast reductions. *J Plast Reconstr Aesthetic Surg.* 2019;72:410–418.
26. Manahan MA, Buretta KJ, Chang D, Mithani SK, Mallalieu J, Shermak MA. An outcomes analysis of 2142 breast reduction procedures. *Ann Plast Surg.* 2015;74:289–292.