

The CO₂ waveguide laser with flexible fiber in transoral resection of oral and oropharyngeal cancers: a retrospective cohort study on postoperative and quality of life outcomes

Nicoletta Gardenal¹  · Stefania Rigo¹ · Francesca Boscolo Nata² · Mario Marcos Fernández-Fernández³ · Paolo Boscolo-Rizzo¹ · Annalisa Gatto¹ · Giancarlo Tirelli¹

Abstract

The aim of this study was to evaluate the CO₂ waveguide laser (WG CO₂ laser) with flexible fiber (Lumenis Ltd., Yokneam, Israel) in the treatment of oral and oropharyngeal cancers, specifically focusing on postoperative outcomes, pain, and quality of life (QoL). Eighty-one patients, 43 women and 38 men, with oral or oropharyngeal cancer who consecutively underwent transoral resection by WG CO₂ laser from August 2015 to April 2020 were retrospectively enrolled. Resections were performed in super pulsed mode with a power setting ranging between 3 and 10 W. Data about frozen sections, reconstruction, complication rate, length of hospital stay, tracheostomy rate and time to decannulation, nasogastric feeding tube rate and time to oral feeding, pain, and QoL were reviewed. Continuous variables were presented as mean and standard deviation. Concordance between intraoperative frozen section examination and definitive histology was calculated using Cohen's κ test of agreement. The mean length of hospital stay was 13 days. The feeding tube rate was 81%; the tracheostomy rate was 35%; the feeding tube was left in place for 8 days on average, and the time to decannulation was 9 days. The only complication was a postoperative bleeding in 4 patients. The median postoperative pain score measured by the Numeric Pain Rating Scale on postoperative days 1, 3, and 5 was 0 and there was a constant decrease in painkiller use over the days. The overall mean composite QoL score was 77 ± 14 , with excellent results in saliva, taste, pain, and speech domains. Frozen section evaluation had a specificity of 99% and a negative predictive value of 98%. WG CO₂ laser is a good and safe tool for transoral tailored resection of oral and oropharyngeal cancers. It ensures a good overall QoL and guarantees fast recovery and a very low postoperative pain.

Keywords Oral cancer · Oropharyngeal cancer · Transoral surgery · Quality of life · CO₂ laser · Laser surgery

Introduction

In recent years, oncologic surgery for oral and oropharyngeal squamous cell carcinoma has evolved as a result of improvements in the technological equipment for transoral

mini-invasive approaches. This reduces the need for invasive open surgery and complex reconstructions, allowing shorter hospitalization, lower surgical morbidity, an increased quality of life, and without any worsening in prognosis [1, 2].

A widespread technique is transoral laser microsurgery (TLM), which has become a preferred organ-preserving technique, initially for laryngeal cancer [3] and later for oral and pharyngeal cancers [4, 5].

However, TLM is not free from technical limitations such as the complexity to achieve optimal exposure with microscopic vision from outside of the mouth, especially for some blind areas of the oropharynx: the laser beam from the micromanipulator travels in a straight line to the target, contraindicating its use in some anatomic sites, such as the base of the tongue. In recent years, these limitations have been overcome by the introduction of a new generation of

✉ Nicoletta Gardenal
nicolettagardenal@gmail.com

¹ ENT Clinic, Head and Neck Department, Cattinara Hospital, University of Trieste, Strada di Fiume 447, 34149 Trieste, Italy

² Otorhinolaryngology Unit, Ospedali Riuniti Padova Sud “Madre Teresa Di Calcutta” Hospital Monselice (Padova)-ULSS, 6 Euganea, Padua, Italy

³ Department of Otolaryngology, Hospital Universitario Gregorio Marañón, Madrid, Spain

CO₂ laser, known as the CO₂ waveguide laser (WG CO₂ laser). This is a very thin tool that is highly suited to head and neck surgeons as it allows resections to be performed at any operating angle, following the surgeon's wrist movements, thanks to different length handpieces. When coupled with magnification tools other than the microscope, such as rigid or flexible tip endoscopes, it allows for angulated views and reduces the blind areas.

In a previous study, WG CO₂ laser with flexible fiber (Lumenis, Santa Clara, CA) was evaluated in 48 patients surgically treated for oral and oropharyngeal cancer, specifically focusing on lateral thermal damage (LTD) induced by this instrument and the consequent reliability of frozen sections. The low LTD found in that series (164.7 μm), allowed an accuracy of 95.8% of the frozen sections [6].

The aim of the present study was to assess the good postoperative outcomes, including postoperative pain and quality of life (QoL), of a broader group of patients with oral and oropharyngeal cancer treated surgically with the WG CO₂ laser with flexible fiber (Lumenis Ltd., Yokneam, Israel).

Materials and methods

In this retrospective cohort study, data about consecutive patients with oral and oropharyngeal cancer who underwent their first tumor resection by WG CO₂ laser with flexible fiber from August 2015 to April 2020 at the Otolaryngology Department, Cattinara Hospital (Trieste, Italy) were collected. The AcuPulse™ Duo CO₂ Laser (Lumenis Ltd., Yokneam, Israel) and the FiberLase™ single-use CO₂ Laser fiber (Lumenis Ltd., Yokneam, Israel) were used for all the interventions. Resection was performed in super pulsed mode with a power setting ranging between 3 and 10 W. Data were collected in total anonymity, with previous acquisition of patient informed consent, and in full agreement with the Declaration of Helsinki and its later amendments, and with the approval of the Cattinara Hospital Ethics Committee. Exclusion criteria were previous surgery for oral and oropharyngeal cancer, previous radiotherapy or chemotherapy for head and neck cancers, cancers involving the hypopharynx or larynx, or medical conditions contraindicating general anesthesia. For each patient, the demographic data, the characteristics of the tumor (site, clinical stage, pathological stage, human papilloma virus status), of the surgery (frozen section evaluation, reconstruction, tracheostomy rate, nasogastric feeding tube rate, complication rate), and of the hospital stay (length of hospital stay, time to decannulation, time to oral feeding) were recorded. We considered as complications postoperative bleeding, surgical site infections, and salivary fistula.

Both superficial and deep margins were collected using WG CO₂ laser from the surgical bed and sent for frozen

section analysis. Superficial margins consisted of 3–4-mm-thick strips of tissue all around the tumor; deep margins consisted of one or two thin slices of tissue underlying the site of the tumor. In the case of positive response, we performed a margin enlargement in the same session as the primary tumor resection.

All patients were staged according to the American Joint Committee on Cancer (AJCC) TNM Staging Classification, 8th edition [7].

Postoperative pain was assessed by the Numeric Pain Rating Scale (NPRS) and in relation to the painkillers needed by the patients 1, 3, and 5 days after surgery [8].

To assess short-time QoL, the University of Washington Quality of Life Questionnaire was administered to patients 1 month after surgery [9]. The questionnaire is composed of 12 single-question items, which have between three and six possible responses scored evenly from zero to 100. The domains investigate pain, appearance, activity, recreation, swallowing, chewing, speech, shoulder, taste, saliva, mood, and anxiety. There are also four global questions about overall QoL, in which patients are asked to consider not only physical and mental health but also other social factors. The final score is expressed as a percentage as result of a weighted average, where zero corresponds to the worst QoL and 100 to the best.

Statistical analysis was performed using dedicated software (Statistical Package for the Social Sciences Version 25, SPSS Inc., Chicago, IL, USA). Results were presented as mean and standard deviation for continuous variables. Concordance between intraoperative frozen section examination and definitive histology was calculated using Cohen's *K* test of agreement.

Results

Eighty-one patients were enrolled for the study, with a mean age of 69 ± 13 years and a median age of 72 years. There were 43 (53%) women and 38 men (47%). The cancer was in the oral cavity in 89% of patients (*n* = 72) and in the oropharynx in 11% (*n* = 9). Table 1 summarizes the patients' demographic data and the features of the tumors. A CONSORT flowchart is provided in Fig. 1.

Tumor was transorally resected in 79 patients (97%). In one patient with carcinoma of the tongue base, the transoral approach did not permit proper exposure of the lesion; thus, a lateral pharyngotomy approach was used, while in another patient, a combined transoral–transmandibular approach was necessary, as the planned marginal mandibulectomy was unable to ensure a margin-free resection. An en bloc resection of the tumor was possible in 68 patients (84%), while a piecemeal resection was necessary in 13 patients (16%). We do not routinely perform neck dissection in oral T1 cancer

Table 1 Patients' demographic data and tumor features

	Oral cavity (72 pts)	Oropharynx (9 pts)
Age, mean \pm SD (range)	70 \pm 13 (36–91)	66 \pm 8 (52–75)
Sex no. (%)		
Female	40 (56%)	3 (33%)
Male	32 (44%)	6 (67%)
Subsite		
	Tongue 36 (50%)	Soft palate 5 (56%)
	Floor of the mouth 11 (15%)	Tonsil 2 (22%)
	Buccal mucosa 12 (17%)	Posterior pharyngeal wall 1 (11%)
	Retromolar trigone 4 (6%)	Tongue base 1 (11%)
	Upper and lower alveolar ridge 8 (11%)	
	Hard palate 1 (1%)	
pT stage no. (%)		
pT1	45 (63%)	3 (33%)
pT2	19 (26%)	5 (56%)
pT3	5 (7%)	1 (11%)
pT4a	2 (3%)	0 (0%)
pT4b	1 (1%)	0 (0%)
Neck dissection no. (%)	38 (53%)	4 (44%)
pN stage no. (%)		
pN0	30 (42%)	2 (22%)
pN1	6 (8%)	0 (0%)
pN2a	0 (0%)	1 (11%)
pN2b	1 (1%)	1 (11%)
pN2c	0 (0%)	0 (0%)
pN3a	0 (0%)	0 (0%)
pN3b	1 (1%)	0 (0%)

with clinically negative nodes, when microinvasive tumor is found in the preoperative biopsy and when magnetic resonance imaging shows a tumor depth of invasion either 2 mm or inferior to 2 mm; in our cohort, a total of 42 patients underwent lateral neck dissection.

In almost half of the cohort (49%), there was no need for reconstruction as the defect healed by secondary intention. When the surgical defect was considered too large, bovine pericardium fixed with fibrin glue (Tisseel fibrin sealant, Baxter Healthcare Corp, Deerfield, IL, USA) ($n=24$; 30%), a Thiersch graft ($n=2$; 2%), or buccal fat pad ($n=4$; 5%) were used in order to accelerate the healing process. Six patients (7%) underwent reconstruction with local flaps, whereas 4 patients (5%) required a free flap because of segmental mandibulectomy, wide exposure of the mandible, or a full thickness defect of the floor of the mouth.

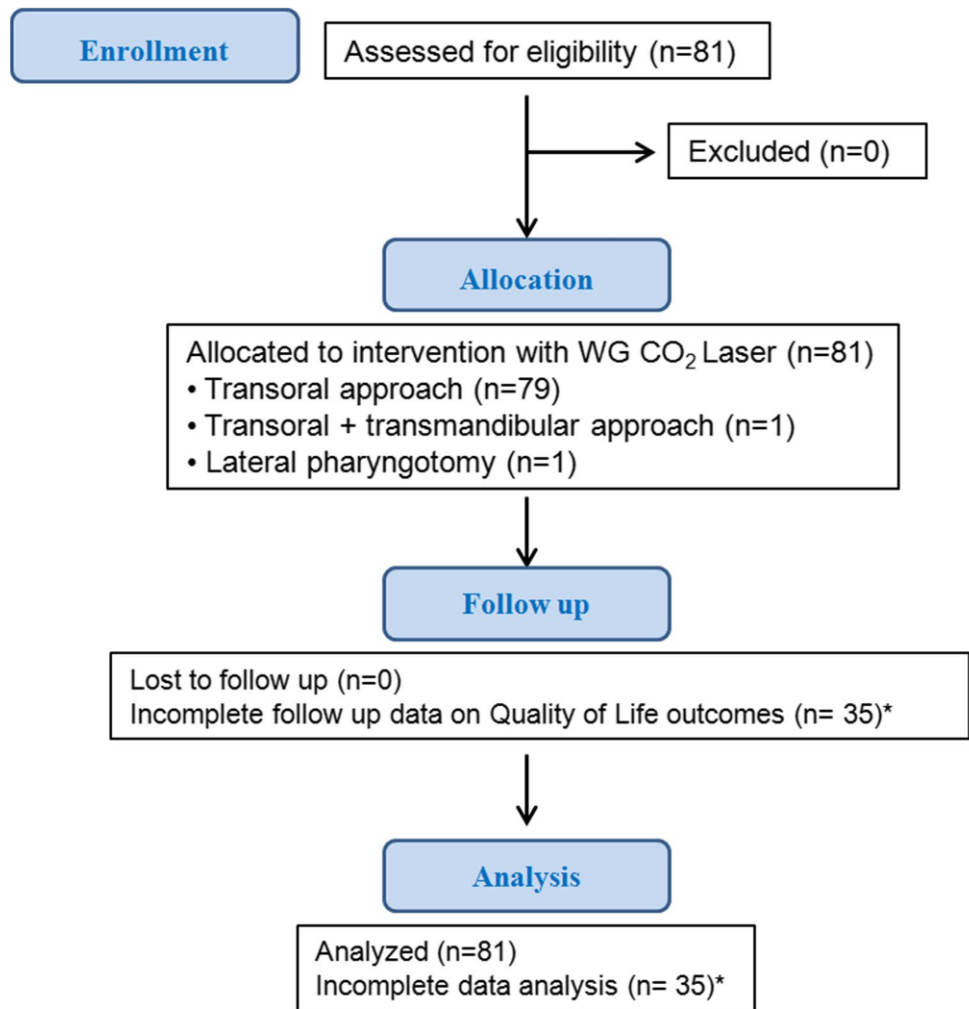
Among the patients with oral cavity cancer, only 17 were tested for human papilloma virus (HPV): 16 proved negative (22%) and 1 positive for HPV16. All patients with oropharyngeal cancer were tested for HPV, and all but one were HPV negative (89%).

Four patients (5%) experienced postoperative bleeding, while one patient (1%) had a mucosal hematoma. There were no cases of mucosal dehiscence or fistula or wound infection.

The mean length of hospital stay was 13 ± 6 days (range: 2–32). The feeding tube rate was 81% (66 patients), while the tracheostomy rate was 35% (28 patients). The feeding tube was left in place for a mean time of 8 ± 4 days, whereas the time to decannulation was 9 ± 4 days.

Frozen section evaluation of the resection margins was routinely performed. Globally, 319 margins were evaluated; we found a false positive rate of 1% (3 margins mistakenly considered dysplasia and 1 wrongly considered cancer) and a false negative rate of 2% (1 margin proved positive for carcinoma invasion at definite histology, while 5 proved positive for dysplasia). In this study, frozen section evaluation had a specificity of 99% and a negative predictive value of 98%. Comparison between frozen section evaluation and definitive histology showed fair agreement ($\kappa=0.36$, $p<0.0001$, $\beta=12\%$), with a discordance rate of 3%.

Fig. 1 CONSORT flowchart for a single-arm, non-randomized cohort study on the CO₂ wave-guide laser with flexible fiber use for transoral resection of oral and oropharyngeal cancers



* The QoL questionnaire at 1 month after surgery was completed by 46 patients. Thirty-five patients completed the first QoL questionnaire at 6 months after surgery and were therefore excluded from the analysis

A complete tumor resection was achieved with the first surgery in 66 patients overall (81.5%). The resection was considered complete when the final margin status was negative or when frozen sections were confirmed negative after definitive histology. In the case of close or positive margins (we consider a positive margin if dysplasia or cancer is found), delayed procedure is often scheduled as soon as possible. Among the 15 patients with incomplete resection, 6 patients underwent close follow-up with Narrow Band Imaging (Visera Elite OTV-S190 video processor and CLV-S190 light source, CH-S190-XZ HDTV camera, OEV261H 26'' LCD HD monitor — Olympus Medical Systems Corp, Tokyo, Japan — with rigid endoscopes), as only mild dysplasia was found, while surgical enlargement was performed in 9 patients with evidence of severe dysplasia or cancer. A complete resection was obtained

in 8 patients (89%), whereas in 1 patient, diffuse severe dysplasia was found, so we decided to proceed with a close follow-up with narrow band imaging (NBI).

Postoperative pain was measured by the NPRS scale: the median NPRS score on the first postoperative day was 0 (range: 0–10), as it was on the third (range: 0–3) and on the fifth postoperative day (range: 0–3). On the first postoperative day, in 15% of patients ($n=12$), there was no need for painkilling medications, 26% ($n=21$) of patients used acetaminophen (Paracetamol 10 mg/ml, Industria Farmaceutica Galenica Senese S.r.l., Monteroni D'Arbia (SI), Italy) to control the pain, 12% ($n=10$) of patients used opioids to control the pain, and 47% ($n=38$) of patients needed opioids (Contramal, Grudenthal Italia S.r.l, Milano, Italy) plus acetaminophen. There was a constant decrease in painkiller use over the days, with 73% of

patients requiring painkillers on the third postoperative and 60% on the fifth postoperative day.

The QoL questionnaire at 1 month after surgery was completed by 46 patients. Thirty-five patients completed the first QoL questionnaire at 6 months after surgery and were therefore excluded from the analysis. The QoL scores divided into domains are shown in Fig. 2. Overall, saliva (91 ± 18), taste (81 ± 27), pain (79 ± 17), and speech (79 ± 16) had the highest score, whereas chewing (64 ± 34) and shoulder complaints (69 ± 36) had the lowest score. Overall mean composite QoL score was 77 ± 14 .

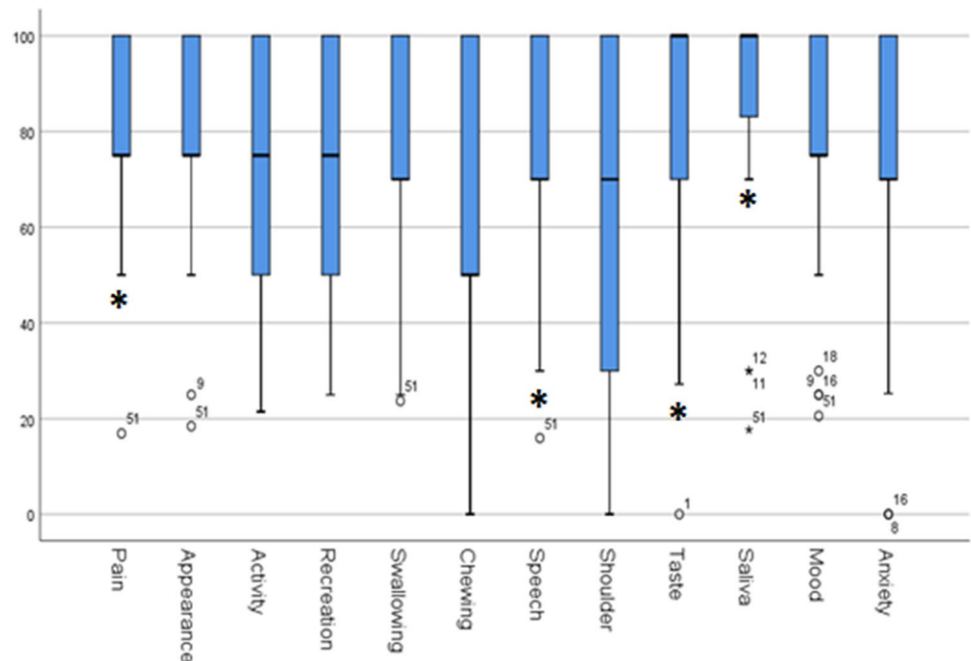
Discussion

During the last 20 years, the technologies and the expertise for transoral surgery have widely developed. Many cutting and sealing instruments have become available for head and neck surgeons. Among them, one of the most recent innovations is the WG CO₂ laser with flexible fiber. As the WG CO₂ laser is a relatively new tool, the literature does not provide specific information on the postoperative course of patients treated surgically for head and neck cancer with this tool. Consequently, we explored postoperative outcomes of a cohort of patients affected by oral and oropharyngeal cancer and analyzed the pros and cons of the use of this instrument in our hands.

While in the past, the aim of cancer treatments was to achieve surgical radicality irrespective of the patient's residual function, in recent years, postsurgical QoL and the balance between oncological and functional outcomes have

gained increasing attention. Oral cavity and oropharyngeal cancer survivors often suffer from bad cosmetic outcome; limited independence in daily activities and recreation; serious deficits in chewing, swallowing, and speech; and frequent mood and anxiety disorders, due to a highly destructive surgery with wide resections that can involve trans-mandibular approaches, neck dissection and flap reconstruction, and adjuvant radiotherapy, with consequent functional impairment [2]. In the present study, of 46 tested patients, a good overall postoperative QoL, and very good results for saliva, taste, pain, and speech were found, as already described for transoral approaches [10]. In particular, pain is the most cutting tool-related item. In the present study, the median postoperative pain level was low and well controlled by analgesics. On the other hand, chewing and shoulder complaints had the lowest score. Clearly, tumor resections that involve the oral cavity greatly affect chewing capacity so that it is especially important to direct patients to postoperative specialized dental rehabilitation after surgery. Shoulder pain, shoulder droop, and loss of shoulder active range of motion are very common postoperative complaints, especially if a neck dissection is performed. It must be noted that, while injury to the accessory nerve is an important risk factor for the development of shoulder dysfunction following neck dissection, shoulder impairment can still occur even if the accessory nerve has been preserved. Thus, it is essential to preoperatively acknowledge the potential for postoperative shoulder and neck musculoskeletal complications, which can occur even when the accessory nerve is preserved [11].

Fig. 2 QoL scores of different domains (University of Washington Quality of Life Questionnaire). Asterisks (*) indicate the items with the highest scores



The tracheostomy rate was 35%, with a mean duration of 9 ± 4 days; the hospitalization length for tracheotomy is concordant with the cohort of Kutter et al. [12] and generally lower than that of open surgery [13]. The literature does not provide general rules regarding the need for a safety tracheotomy. In our experience, tracheotomy is easily reversible, does not significantly increase the duration of surgery, and does not impact on recovery time; for these reasons, we usually perform a safety elective tracheotomy in patients with advanced oropharyngeal cancer, in patients with oral cavity tumors who take platelet aggregation inhibitors or anticoagulant therapy.

In most of the series (81% patients), we placed a nasogastric feeding tube to prevent the wound from being exposed to food with the risk of local infections and, concurrently, to accelerate the healing process. On average, the feeding tube was left in place for 8 days, in line with the existing literature [12].

The total mean hospital stay was 13 days, consistent with the series of Kutter et al. [12], but longer than the one reported by Remacle et al. [14]. However, it must be considered that the presented cohort was larger than the one reported by Remacle et al. and included patients with both early and advanced cancer, with more comorbidities and older.

The principal drawback of WG CO₂ laser with flexible fiber is the low coagulation capability; this tool cannot seal vessels larger than 0.5 mm, for which bipolar cauterization is required [15]. This is particularly true for transoral resection of oropharyngeal cancers, when intraoperative bleeding could negatively affect the vision of the surgical field, making the second surgeon's support (with aspiration and bipolar cautery) essential. Moreover, the need for a frequent hemostasis with bipolar cautery increases surgical time [6]. For these reasons, we think that WG CO₂ laser with flexible fiber is not the ideal tool for transoral resection of oropharyngeal cancer in highly vascularized subsites, such as the palatine tonsils and base of tongue. In these subsites, we usually prefer to sample superficial margins with the WG CO₂ laser to preserve margin specimen from a higher thermal damage, and then resect the tumor with a radiofrequency scalpel. Nevertheless, as preventing hemorrhage is better than facing a potentially life-threatening situation, we recommend meticulous hemostasis with transoral clipping, ligation or cautery of vessels more than 2 mm in diameter, and preventive ligation or clipping of the lingual and pharyngeal branches of the external carotid artery during neck dissection [16]. Likewise, the low coagulation capability increases the risk of postoperative bleeding; despite this in our cohort, we had a postoperative bleeding rate of 5%, which is consistent with the literature [16–18].

Another drawback of the WG CO₂ laser is the costs of the fibers. As they are single use, the impact on the finance

of a high-volume center is higher than that of the traditional CO₂ laser.

The CO₂ laser is a fundamental tool in a head and neck surgeon's equipment. Its major benefits reported in the literature are minimal postoperative swelling, improved wound healing with minimal scarring, decreased postoperative pain, better functional recovery, and less thermal damage on adjacent tissues than electrocautery [19, 20]. However, concern remains regarding the traditional microscope-mounted micromanipulator, in which the laser beam travels in a straight line, not well suited for the curvilinear shape of the oropharynx and for some subsites of the oral cavity. The introduction of fiber delivery CO₂ laser systems aims to overcome this limitation. They allow direct application of the laser shaft to the targeted tissue in a non-contact mode, 1 mm away from the tissue surface, via handheld handpieces [21, 22]. Therefore, the dissection follows the surgeon's wrist movements permitting different orientations of the beam towards tissues. This is particularly useful for the oropharynx, whose inferior and posterior margins are difficult to approach with the laser straight line from a micromanipulator [23]. In the oral cavity, it allows easier en bloc resections of the curvilinear vestibular region or oral pelvis. Furthermore, it makes it possible to perform thin and continuous mucosectomy for microinvasive tumors or dysplastic lesions through precise tangential cuts, even by splitting the mucosa from the periosteum on a bony plane (maxilla, mandible, or hard palate) [6]. Actually, premalignant lesions should be fully excised and not vaporized with the CO₂ laser in order to correctly evaluate the full-length histology of the lesion and to avoid malignant transformation [24]. In addition, performing the surgery under an electronic endoscope, instead of a microscope, has a remarkable advantage. The contrast enhancement function (such as NBI) makes it possible to accurately evaluate small lesions and their extension, which is sometimes difficult with normal light, by changing the image function mode to check the lesions whenever needed during surgery [25]. On the other hand, WG CO₂ laser with flexible fiber lacks the precise automation of the CO₂ laser microscopic scanning systems so that the precision of the cut and the amount of energy given to tissues depend on the surgeon's hand. This can impact mainly on margin sampling and on thermal artifacts on tissues. As it is known, the main goal in oral and oropharyngeal cancer surgery is to perform a complete tumor resection with clear margins. Failure to achieve clear surgical margins leads to high rates (up to 90%) of locoregional recurrence and decreased survival [26]. Complete tumor exposure and margin control may become challenging in transoral surgery, as the field is narrower than in classical open approaches (transmandibular, pull through) [27]. For this reason, radicality in transoral surgery is assessed step by step based on frozen section analysis. Given its fundamental role, frozen section collection

must be accurate to ensure that intraoperative histology will be confirmed after formalin embedding [28]. In our experience, we found a low discordance rate (3%) between frozen section analysis and definitive histology; moreover, it must be noted that frozen sections proved to be particularly helpful in confirming negative margins, as specificity was 99% and negative predictive value was 98%.

Conclusion

The WG CO₂ laser with flexible fiber is a valuable tool in transoral oral and oropharyngeal surgery thanks to its precision in cutting and its excellent maneuverability. It ensures a good overall QoL and, despite the surgical wound healing by secondary intention (the wound is left open to heal by granulation, contraction, and epithelialization) in almost half of patients, it guarantees a fast post-surgical recovery with very low level of postoperative pain. Drawbacks are related to the low haemostatic ability and to the costs of the fibers.

Author contribution Prof. GT and Prof. MMFF actively contributed to the conception and design of the study; FBN and AG contributed to the acquisition and analysis of data; NG and SR contributed to acquisition of data and drafted the manuscript; Prof PBR critically revised the manuscript.

Funding The work was supported by Lumenis Ltd., Yokneam, Israel, the manufacturer of the CO₂ waveguide laser with flexible fiber. The authors were trained in the use of the tool.

Data availability The data that support the findings of this study are available from the corresponding author, NG, upon reasonable request.

Declarations

Ethical approval All procedures performed in studies involving human participants were in accordance with the ethical standards of the institutional and/or national research committee and with the 1964 Helsinki Declaration and its later amendments or comparable ethical standards. The Ethics Committee on Clinical Investigation of the University of Trieste approved the study protocol (Report No. 58).

Informed consent Informed consent was obtained from all individual participants included in the study. Consent for publication was received from every participant patient.

Conflict of interest The authors declare no competing interests.

References

1. Tirelli G, Zacchigna S, Boscolo Nata F, Quatela E, Di Lenarda R, Piovesana M (2017) Will the miniminvasive approach challenge the old paradigms in oral cancer surgery? *Eur Arch Oto-Rhino-Laryngology* 274:1279–1289
2. Gobbo M, Bullo F, Perinetti G, Gatto A, Ottaviani G, Biasotto M, Tirelli G (2016) Diagnostic and therapeutic features associated with modification of quality-of-life's outcomes between one and six months after major surgery for head and neck cancer. *Braz J Otorhinolaryngol* 82:548–557
3. Strong MS, Jako GJ (1972) Laser surgery in the larynx early clinical experience with continuous CO₂ laser. *Ann Otol Rhinol Laryngol* 81:791–798
4. Haughey BH, Hinni ML, Salassa JR, Hayden RE, Grant DG, Rich JT, Milov S, Lewis JS Jr, Krishna M (2011) Transoral laser microsurgery as primary treatment for advanced-stage oropharyngeal cancer: a united states multicenter study. *Head Neck* 33:1683–1694
5. Sinha P, Hackman T, Nussenbaum B, Wu N, Lewis JS Jr, Haughey BH (2014) Transoral laser microsurgery for oral squamous cell carcinoma: oncologic outcomes and prognostic factors. *Head Neck* 36:340–351
6. Tirelli G, Boscolo Nata F, Bussani R, Gatto A, Quatela E, Rigo E, Piovesana M (2019) How we improve the transoral resection for oral and oropharyngeal cancer: the CO₂ waveguide laser. *Eur Arch Otorhinolaryngol* 276:2301–2310
7. Pfister DG, Spencer S, Adelstein D, Adkins D, Anzai Y, Brizel DM, Bruce JY, Busse PM, Caudell JJ, Cmelak AJ, Colevas AD, Eisele DW, Fenton M, Foote RL, Galloway T, Gillison ML, Haddad RI, Hicks WL, Hitchcock YJ, Jimeno A, Leizman D, Maghami E, Mell LK, Mittal BB, Pinto HA, Ridge JA, Rocco JW, Rodriguez CP, Shah JP, Weber RS, Weinstein G, Witek M, Worden F, Yom SS, Zhen W, Burns JL, Darlow SD (2020) Head and neck cancers, version 2.2020, NCCN clinical practice guidelines in oncology. *J Natl Compr Canc Netw* 18:873–898
8. Rodriguez CS, McMillan S, Yarandi H (2004) Pain measurement in older adults with head and neck cancer and communication impairments. *Cancer Nurs* 27:425–433
9. Weymuller EA Jr, Alsarraf R, Yueh B, Deleyiannis FW, Coltrera MD (2001) Analysis of the performance characteristics of the University of Washington Quality of Life instrument and its modification (UW-QOL-R). *Arch Otolaryngol Head Neck Surg* 127:489–493
10. Hinni ML, Nagel T (2015) Howard B (2015) Oropharyngeal cancer treatment: the role of transoral surgery. *Curr Opin Otolaryngol Head Neck Surg* 23:132–138
11. Gane EM, Michaleff ZA, Cottrell MA, McPhail SM, Hatton AL, Panizza BJ, O'Leary SP (2017) Prevalence, incidence, and risk factors for shoulder and neck dysfunction after neck dissection: a systematic review. *Eur J Surg Oncol* 43:1199–1218
12. Kutter J, Lang F, Monnier P, Pasche P (2007) Transoral laser surgery for pharyngeal and pharyngolaryngeal carcinomas. *Arch Otolaryngol Head Neck Surg* 133:139–144
13. Edney T, Pillevuit O, Soldati D et al (2004) 158 functional pharyngectomies and pharyngo-laryngectomies (1981–2001): complications and results. *Schweiz Med Forum* 4(suppl 16):98S-101S
14. Remacle M, Matar N, Lawson G, Bachy V, Delos M, Nollevaux MC (2012) Combining a new CO₂ laser wave guide with transoral robotic surgery: a feasibility study on four patients with malignant tumors. *Eur Arch Otorhinolaryngol* 269:1833–1837
15. Remacle M, Ricci-Maccarini A, Matar N, Lawson G, Pieri F, Bachy V, Nollevaux VBM (2012) Reliability and efficacy of a new CO₂ laser hollow fiber: a prospective study of 39 patients. *Eur Arch Otorhinolaryngol* 269:917–921
16. Tirelli G, Boscolo Nata F, Piovesana M, Quatela E, Gardenal N, Hayden RE (2018) Transoral surgery (TOS) in oropharyngeal cancer: different tools, a single mini-invasive philosophy. *Surg Oncol* 27:643–649
17. Vilaseca-González I, Bernal-Sprekelsen M, Blanch-Alejandro JL, Moragas-Lluis M (2003) Complications in transoral CO₂ laser

- surgery for carcinoma of the larynx and hypopharynx. *Head Neck* 25:382–388
18. Salassa JR, Hinni ML, Grant DG, Hayden RE (2008) Postoperative bleeding in transoral laser microsurgery for upper aerodigestive tract tumors. *Otolaryngol Head Neck Surg* 139:453–459
 19. Strauss RA (2000) Lasers in oral and maxillofacial surgery. *Dent Clin North Am* 44:851–873
 20. Bornstein MM, Winzap-Kälin C, Cochran DL, Buser D (2005) The CO₂ laser for excisional biopsies of oral lesions: a case series study. *Int J Periodontics Restorative Dentistry* 25:221–229
 21. Holsinger FC, Prichard CN, Shapira G, Weisberg O, Torres DS, Anastassiou C, Harel E, Fink Y, Weber RS (2006) Use of the photonic band gap fiber assembly CO₂ laser system in head and neck surgical oncology. *Laryngoscope* 116:1288–1290
 22. Zeitels SM, Kobler JB, Heaton JT, Faquin W (2006) Carbon dioxide laser fiber for laryngeal cancer surgery. *Ann Otol Rhinol Laryngol* 115:535–541
 23. Li RJ, Richmon JD (2012) Transoral endoscopic surgery: new surgical techniques for oropharyngeal cancer. *Otolaryngol Clin North Am* 45:823–844
 24. Mogedas-Vegara A, Hueto-Madrid JA, Chimenos-Küstner E, Bescós-Atín C (2016) Oral leukoplakia treatment with the carbon dioxide laser: a systematic review of the literature. *J Craniomaxillofac Surg* 44:331–336
 25. Araki K, Tomifuji M, Uno K, Suzuki H, Tanaka Y, Tanaka S, Kimura E, Shiotani A (2019) Feasibility of transnasal flexible carbon dioxide laser surgery for laryngopharyngeal lesions. *Auris Nasus Larynx* 46:772–778
 26. Eldeeb H, Macmillan C, Elwell C, Hammod A (2012) The effect of the surgical margins on the outcome of patients with head and neck squamous cell carcinoma: single institution experience. *Cancer Biol Med* 9:29–33
 27. Tirelli G, Boscolo Nata F, Gatto A, Bussani R, Spinato G, Zaccogna S, Piovesana M (2019) Intraoperative margin control in transoral approach for oral and oropharyngeal cancer. *Laryngoscope* 129:1810–1815
 28. Tirelli G, Hinni ML, Fernández-Fernández MM, Bussani R, Gatto A, Bonini P, Giudici F, Boscolo Nata F (2019) Frozen sections and complete resection in oral cancer surgery. *Oral Dis* 25:1309–1317

Publisher's note Springer Nature remains neutral with regard to jurisdictional claims in published maps and institutional affiliations.