














ORIGINAL ARTICLE

A risk-scoring model for the differential diagnosis of lentigo maligna and other atypical pigmented facial lesions of the face: The *facial iDScore*

Linda Tognetti¹  | Alessandra Cartocci^{1,2}  | Magdalena Żychowska³  | Imma Savarese⁴ | Elisa Cinotti¹ | Maria Antonietta Pizzichetta^{5,6}  | Elvira Moscarella⁷  | Caterina Longo^{8,9} | Francesca Farnetani⁹  | Stefania Guida^{10,11}  | John Paoli^{12,13}  | Aimilios Lallas¹⁴  | Danica Todorovic¹⁵ | Ignazio Stanganelli^{16,17} | Serena Magi¹⁶ | Emi Dika^{18,19}  | Iris Zalaudek⁵ | Mariano Suppa^{20,21,22}  | Giuseppe Argenziano⁷  | Giovanni Pellacani²³  | Jean Luc Perrot²⁴ | Chiara Miracapillo¹ | Giovanni Rubegni²⁵ | Gabriele Cevenini²⁶ | Pietro Rubegni¹

Correspondence

Linda Tognetti, Dermatology Unit, Department of Medical, Surgical and Neurosciences, University of Siena, Viale Bracci 16, S. Maria alle Scotte Hospital, Siena, Italy.
Email: linda.tognetti@dbm.unisi.it

Abstract

Background: Due to progressive ageing of the population, the incidence of facial lentigo maligna (LM) of the face is increasing. Many benign simulators of LM and LMM, known as atypical pigmented facial lesions (aPFLs—pigmented actinic keratosis, solar lentigo, seborrheic keratosis, seborrheic-lichenoid keratosis, atypical nevus) may be found on photodamaged skin. This generates many diagnostic issues and increases the number of biopsies, with a subsequent impact on aesthetic outcome and health insurance costs.

Objectives: Our aim was to develop a risk-scoring classifier-based algorithm to estimate the probability of an aPFL being malignant. A second aim was to compare its diagnostic accuracy with that of dermoscopists so as to define the advantages of using the model in patient management.

Materials and Methods: A total of 154 dermatologists analysed 1111 aPFLs and their management in a teledermatology setting: They performed pattern analysis, gave an intuitive clinical diagnosis and proposed lesion management options (follow-up/reflectance confocal microscopy/biopsy). Each case was composed of a dermoscopic and/or clinical picture plus metadata (histology, age, sex, location, diameter). The risk-scoring classifier was developed and tested on this dataset and then validated on 86 additional aPFLs.

Results: The *facial Integrated Dermoscopic Score (iDScore)* model consisted of seven dermoscopic variables and three objective parameters (diameter ≥ 8 mm, age ≥ 70 years, male sex); the score ranged from 0 to 16. In the testing set, the *facial iDScore*-aided diagnosis was more accurate (AUC = 0.79 [IC 95% 0.757–0.843]) than the intuitive diagnosis proposed by dermatologists (average of 43.5%). In the management study, the score model reduced the number of benign lesions sent for biopsies by 41.5% and increased the number of LM/LMM cases sent for reflectance confocal microscopy or biopsy instead of follow-up by 66%.

Conclusions: The *facial iDScore* can be proposed as a feasible tool for managing patients with aPFLs.

This is an open access article under the terms of the [Creative Commons Attribution-NonCommercial-NoDerivs](https://creativecommons.org/licenses/by-nc-nd/4.0/) License, which permits use and distribution in any medium, provided the original work is properly cited, the use is non-commercial and no modifications or adaptations are made.

© 2023 The Authors. *Journal of the European Academy of Dermatology and Venereology* published by John Wiley & Sons Ltd on behalf of European Academy of Dermatology and Venereology.

INTRODUCTION

Lentigo maligna (LM) is a subtype of melanoma that typically develops on photodamaged skin in association with solar elastosis. It consists of a proliferation of atypical melanocytes along the epidermal basal layer and adnexal structures.^{1,2} It can persist within the epidermis for decades before progressing to its invasive form, lentigo maligna melanoma (LMM).^{3–5} The face is the site most frequently involved, followed by the neck and hairless scalp.^{1,2} The incidence of LM has sharply increased over the last few decades.^{1–5} Although patients in the 7th and 8th decades of life have traditionally been considered the most frequently affected, the occurrence of LM in younger adults is increasingly reported.^{6–8}

In the last 20 years, dermoscopy has proven effective in aiding early recognition of LM/LMM.^{9–17} Particular emphasis has been dedicated to defining dermoscopic features of pigmented lesions of the face, including fully benign ones (i.e. solar lentigo—SL, seborrheic keratosis—SK, benign lichenoid keratosis—BLK and atypical nevus—AN), lesions at risk of malignant transformation (i.e. pigmented actinic keratosis—PAK) and malignant lesions (i.e. LM and LMM).^{12–20} However, several controversies have since arisen: (i) dermoscopic clues have been predominantly based on typical clear-cut lesions^{18–24}; (ii) there has been no firm consensus among researchers regarding the exact definitions and names for a variety of dermoscopic features observed in pigmented facial lesions, thus creating dozens of terms (nearly 50) and multiple describing the same feature (Table S1); (iii) in clinical practice, LM and LMM turn out to be very difficult to distinguish based on dermoscopic findings.^{6,25,26} Finally, we know that some pigmented facial lesions of benign histopathology, especially those on photodamaged skin and/or areas subject to repetitive microtrauma, may look clinically and dermoscopically atypical.^{6,12–15,27} In particular, we define as atypical pigmented facial lesions (aPFLs), all flat pigmented facial lesions displaying equivocal dermoscopic features, for which the dermatologist is uncertain about the diagnosis and needs a skin biopsy to rule out malignancy.²⁷ This currently generates many unnecessary surgical excisions in a delicate site, as is the face.^{13,28–31} In this regard, reflectance confocal microscopy (RCM) that provides in-vivo horizontal histology has proven a useful tool. However, this technique is not yet available in many centres, requires long training and its diagnostic accuracy on traumatized or inflamed lesions is limited.^{28,32–34}

Objectives

Based on these premises, our first aim was to investigate the features most frequently associated with a diagnosis of LM/LMM in a large series of histopathologically confirmed aPFLs paired with clinical and dermoscopic data. Our second aim was to develop a risk-scoring classifier-based algorithm, which we called *facial integrated Dermoscopic Score (iDScore)*, to estimate the probability of an aPFL being malignant. Our

third aim was to compare the accuracy of intuitive diagnoses by a large number of dermoscopists with *facial iDScore*-aided diagnosis. A fourth aim was to define the advantages of using this method in patient/lesion management.

MATERIALS AND METHODS

This retrospective multicentric study was approved by the local Ethics Committee (University Hospital of Siena. Study Protocol No. 16801) and carried out in compliance with the Helsinki Declaration. All data were de-identified before use.

Integrated aPFL dataset

As previously described,²⁷ we formed an international clinico-dermoscopic web registry that we named *facial iDScore dataset* for difficult-to-diagnose aPFLs. It contains 1197 histologically confirmed cases, that is LM ($n=353$), LMM ($n=146$), SL ($n=266$), PAK ($n=231$), AN ($n=125$), SK ($n=48$) and BLK ($n=28$). Each case consists of a standardized dermoscopic picture and four metadata items: maximum diameter, site (e.g. orbital area/forehead/nose/cheek/chin/mouth), age and sex; an anonymized clinical picture was available in 60% of cases.

Testing, training and validation sets

In order to train, test and validate the risk model, we obtained two separate sets from the original *facial iDScore dataset* (Table 1) by random split: the first set of 1111 aPFLs was used to develop the risk-scoring classifier (*training/testing phase*); the second set of 86 cases was the external validation set to confirm the results of the previous phase on a group of new lesions (*validation phase*). Then, proportions of 80% and 20% were chosen to divide the set of 1111 cases into *training* and *testing* subsets, respectively, maintaining the distribution of the histologies comparable.

Teledermoscopic test

All cases were examined online by means of a dedicated web platform (<https://en.idscore.net/projects/facial-lesions/facial-lesions-2021>), as previously described.²⁷ In particular, the set of 1111 cases was analysed by 154 participants across Europe (dermatologists and dermatology residents), while the validation set of 86 cases was examined by three expert dermoscopists (MZ, IS, EC). Participants have to register before examining cases, indicating his/her experience in dermoscopy (<1/1–5/5–8/>8 years), their affiliation, the country in which they were trained in Dermatology and preferred device (personal computer, smartphone, tablet or notebook).²⁹

TABLE 1 Descriptive statistics of the datasets of atypical pigmented facial lesions (aPFLs) used to train, test and validate the facial iDScore checklist.

Lesions/ Patients' data	Training-testing set (1111 aPFLs)							Validation set (86 aPFLs)						
	LM	LMM	PAK	AN	SL	SK	BLK	LM	LMM	PAK	AN	SL	SK	BLK
N (%)/mean (±SD)	329 (29.6)	143 (12.9)	209 (18.8)	111 (10)	260 (23.4)	38 (3.4)	21 (1.9)	24 (27.9)	3 (0.3) (3.5)	22 (25.6)	14 (16.3)	6 (7.0)	10 (11.6)	7 (8.1)
Maximum diameter (mm)	11.1 (5.4)	12.13 (8.01)	10.42 (5.97)	5.36 (3.66)	9.70 (5.34)	9.47 (7.36)	12.24 (7.52)	21.31 (19.6)	9.67 (4.7)	7.01 (5.09)	5.64 (4.53)	13.50 (13.1)	15.90 (16.9)	18.00 (17.6)
Lesion site														
Orbital area	36 (10.9)	13 (9.1)	18 (8.6)	10 (9.0)	39 (15.0)	4 (10.5)	5 (23.8)	1 (4.2)	0 (0.0)	2 (9.1)	1 (7.1)	0 (0.0)	0 (0.0)	0 (0.0)
Forehead	47 (14.3)	35 (24.5)	52 (24.9)	18 (16.2)	32 (12.3)	11 (28.9)	6 (28.6)	5 (20.8)	0 (0.0)	2 (9.1)	1 (7.1)	0 (0.0)	5 (50.0)	2 (33.3)
Nose	58 (17.6)	24 (16.8)	48 (23.0)	11 (9.9)	30 (11.5)	5 (13.2)	2 (9.5)	9 (37.5)	0 (0.0)	6 (27.3)	3 (21.4)	0 (0.0)	2 (20.0)	2 (33.3)
Cheek	180 (54.7)	58 (40.6)	83 (39.7)	62 (55.9)	146 (56.2)	17 (44.7)	8 (38.1)	7 (29.2)	3 (100)	11 (50)	9 (64.3)	7 (100)	2 (20)	2 (33.3)
Chin	1 (0.3)	12 (8.4)	6 (2.9)	8 (7.2)	10 (3.8)	0 (0)	0 (0)	1 (4.2)	0 (0)	0 (0)	0 (0)	0 (0)	1 (10)	0 (0.0)
Mouth	7 (2.1)	1 (0.7)	2 (1.0)	2 (1.8)	3 (1.2)	1 (2.6)	0 (0)	1 (4.2)	0 (0)	1 (4.5)	0 (0)	0 (0)	0 (0)	0 (0)
Age (years)	69.75 (13)	69.08 (12.9)	69.01 (11.3)	48.80 (13.9)	64.71 (12.3)	65.32 (15.1)	60.05 (12.5)	66.04 (11.4)	59.33 (13.6)	59.73 (16.4)	40.36 (10.9)	57.67 (9.20)	67.20 (9.38)	65.00 (11.1)
Sex (Male)	164 (49.8)	90 (62.9)	106 (50.7)	46 (41.4)	109 (41.9)	24 (64.9)	5 (23.8)	9 (37.5)	2 (66.7)	8 (36.4)	5 (35.7)	2 (33.3)	7 (70)	3 (42.9)

Abbreviations: AN, atypical nevus; BLK, seborrheic-lichenoid keratosis; LM, lentigo maligna; LMM, lentigo maligna melanoma; PAK, pigmented actinic keratosis; SK, seborrheic keratosis; SL, solar lentigo.

Each teledermoscopic test was composed of 20 blinded cases. Weighted random selection was designed with constraints to ensure that: (i) participants affiliated with one of the 11 contributing centres did not have to assess the images provided by their centre; (ii) participants affiliated with a centre outside these 11 centres could assess any lesion in the dataset; (iii) the individual test was composed of 60% benign and 40% malignant cases; (iv) all cases were analysed at least once and no case more than four times. The chance weight of each case per participant was defined by an assignment probability that considered the number of evaluations already performed, N_1 , and the number of times the case had been assigned but not evaluated, N_2 , according to the following formula: $\frac{1}{N_1 * 1 + 0.3 * N_2 + 1}$. To evaluate each case, participants had to complete five consecutive steps: 'pattern analysis', 'intuitive clinical diagnosis', 'confidence in diagnosis', 'case rating' and 'management decision'.

The pattern analysis relied on assessment of presence/absence of a series of 14 dermoscopic features (Table 2) which were selected from a pool of 47 definitions (Table S1) based on consensus strength and literature data, avoiding duplicates in terminology.¹⁵⁻²⁴ At the end of the testing and validation phases, a dermoscopic pattern was defined as present/absent in a specific lesion on the basis of majority consensus among the evaluators.

The participants then had to propose an intuitive clinical diagnosis in each case by choosing one of seven aPFL histotypes (LM/LMM/PAK/SL/BLK/AN/SK). In the next step, they had to express their confidence in this diagnosis by choosing among: 'very confident/mildly confident/uncertain/mildly under-confident/not confident' and to rate the case as 'very easy/easy/moderate/difficult/very difficult'. Finally, they proposed a management decision of 'follow-up', 'RCM examination' or 'biopsy'. At the end of each case, participants indicated the type of device they used to perform the teledermoscopic evaluation. All responses were recorded through the web platform and analysed as follows.

Statistical analysis

Descriptive statistics with mean and standard deviation (mean ± SD) were done for quantitative variables and with absolute frequencies and percentages for qualitative variables. Univariate analysis was used for dermoscopic and clinical/personal data (Table 1). Association of the 14 dermoscopic features with the seven aPFL histotypes was evaluated by chi-squared statistics on the whole dataset of 1197 cases. Multiple comparison chi-squared tests were performed, correcting for false-discovery rate, to investigate significant relationships between the different pairs (Table 2). A forward-backward stepwise logistic regression based on the area under the ROC curve (AUC) was used to develop the scoring model: At each step, a variable was added/removed from the model if the AUC with/without the variable increased by at least 0.3%.

TABLE 2 Distribution and association analysis (*p*) of 14 dermoscopic features, assessed by 154 dermoscopists among 1111 atypical pigmented facial lesions (aPFLs) in a teledermoscopy setting.

Dermoscopic features	AN (111)	LM (329)	LMM (143)	PAK (209)	SK (38)	BLK (21)	SL (260)	<i>p</i>
	<i>n</i> (%) of positive observations according to 3/4 concordant participant							
Hyperpigmented follicular openings	28 (25.2%)	191 (58.1%)	81 (56.6%)	59 (28.2%)	12 (31.6%)	5 (23.8%)	75 (28.8%)	<0.001 ^{a,b,h,i,j,k,l,m,n,o}
Target-like pattern	15 (13.5%)	79 (24.0%)	41 (28.7%)	24 (11.5%)	5 (13.2%)	1 (4.8%)	13 (5%)	<0.001 ^{b,f,h,k,l,m,o,r}
Annular-granular pattern	23 (20.7%)	142 (43.2%)	57 (39.9%)	77 (36.8%)	9 (23.7%)	17 (81%)	63 (24.2%)	<0.001 ^{a,b,c,d,i,j,k,m,o,p,r,s,t}
Pigment rhomboids/polygons	17 (15.3%)	149 (45.3%)	72 (50.3%)	47 (22.5%)	7 (18.4%)	4 (19%)	32 (12.3%)	<0.001 ^{a,b,h,i,j,k,l,m,p}
Obliterated follicular openings	29 (26.1%)	98 (29.8%)	78 (54.5%)	25 (12%)	8 (21.1%)	1 (4.8%)	18 (6.9%)	<0.001 ^{a,b,h,i,j,k,l,m,n,o,r}
Red structures and lines	9 (8.1%)	58 (17.6%)	22 (15.4%)	73 (34.9%)	6 (15.8%)	2 (9.5%)	24 (9.2%)	<0.001 ^{c,h,k,l,r}
Keratin plugs	16 (14.4%)	70 (21.3%)	38 (26.6%)	69 (33%)	12 (31.6%)	2 (9.5%)	45 (17.3%)	<0.001 ^{c,h,r}
Lightbrown fingerprint-like structures/areas	13 (11.7%)	45 (13.7%)	26 (18.2%)	20 (9.6%)	12 (31.6%)	2 (9.5%)	78 (30%)	<0.001 ^{e,r,j,k,o,q,r}
Moth-eaten borders	18 (16.2%)	64 (19.5%)	28 (19.6%)	34 (16.3%)	12 (31.6%)	6 (28.6%)	111 (42.7%)	<0.001 ^{f,k,o,r}
Diffuse opaque yellow-brown pigmentation	22 (19.8%)	77 (23.4%)	19 (13.3%)	51 (24.4%)	9 (23.7%)	3 (14.3%)	127 (48.8%)	<0.001 ^{f,g,k,l,o,r,t,u}
Fat fingers	5 (4.5%)	16 (4.9%)	7 (4.9%)	5 (2.4%)	6 (15.8%)	2 (9.5%)	30 (11.5%)	<0.001 ^{k,q,r}
Milia-like cysts	13 (11.7%)	23 (7%)	14 (9.8%)	16 (7.7%)	5 (13.2%)	0 (0%)	29 (11.2%)	0.274
Comedo-like openings	14 (12.6%)	29 (8.8%)	19 (13.3%)	15 (7.2%)	9 (23.7%)	2 (9.5%)	24 (9.2%)	0.054
Evident and regular follicular openings	39 (35.1%)	123 (37.4%)	39 (27.3%)	110 (52.6%)	17 (44.7%)	7 (33.3%)	144 (55.4%)	<0.001 ^{c,f,h,k,l,o}

Note: ^aAN – LM are statistically different; ^bAN – LMM are statistically different; ^cAN – PAK are statistically different; ^dAN – BLK are statistically different; ^eAN – SK are statistically different; ^fAN – SL are statistically different; ^gLM – LMM are statistically different; ^hLM – PAK are statistically different; ⁱLM – BLK are statistically different; ^jLM – SK are statistically different; ^kLM – SL are statistically different; ^lLMM – PAK are statistically different; ^mLMM – BLK are statistically different; ⁿLMM – SK are statistically different; ^oLMM – SL are statistically different; ^pPAK – BLK are statistically different; ^qPAK – SK are statistically different; ^rPAK – SL are statistically different; ^sBLK – SK are statistically different; ^tBLK – SL are statistically different; ^uSK – SL are statistically different.

Abbreviations: AN, atypical nevus; BLK, seborrheic-lichenoid keratosis; LM, lentigo maligna; LMM, lentigo maligna melanoma; PAK, pigmented actinic keratosis; SK, seborrheic keratosis; SL, solar lentigo.

Score thresholds were estimated on the training dataset. The initial set of variables consisted of the 14 dermoscopic patterns, sex, age (categorized with a cut-off that increased in 10-year steps) and maximum diameter (categorized with a cut-off in 2-mm steps). AUC, sensitivity and specificity for selected cut-offs were assessed to evaluate the performance of the stepwise model. A significance level of 95% was chosen. Statistical analysis was performed with R version 4.1.1.

RESULTS

Participant data

The 154 online participants had an average age of 36.5 years (± 10.6 SD; range 24–67 years); 72 males (46.8%) and 82

females (53.2%); 102 (66.2%) were dermatologists and 52 (33.8%) dermatology residents. They were from 17 countries (in Europe, the United States, South America and Australia). Thirty-four participants (22.1%) had <1 year of experience in dermoscopy (skill level I), 44 (28.6%) had 1 to 4 years (level II), 22 (14.3%) had 5 to 8 years (level III) and 54 (35.1%) had >8 years of experience (level IV).

Integrated aPFL dataset

The descriptive statistics of the aPFL datasets used to train, test and validate the *facial iDScore* are reported in Table 1. Average lesion diameter was 10.4 mm (range 1–53 mm), and 50% of aPFLs were on the cheek; patients averaged 65.4 ± 14.2 years of age, and the F/M distribution was

51.5%/48.5%. Benign cases were 698 (58.3%), while malignant (LM + LMM) were 499 (41.6%).

Teledermoscopic test

Table 1 shows the results of pattern analysis of the subset of 1111 lesions (descriptive statistics and association analysis). Table S2 shows the results of pattern analysis performed by the three experts on the validation set of 86 lesions: A pool of 34.2 parameters was obtained from 2445 online evaluations of the 14 patterns. Four patterns showed a predominance in malignant aPFLs compared with benign aPFLs, namely ‘hyperpigmented follicular openings’ (in 58.1% LM and 56.6% of LMM), ‘pigment rhomboids/polygons’ (in 45.3% of LM and 50.3% of LMM), ‘obliterated follicular openings’ (in 29.8% of LM and 54.5% of LMM) and ‘target-like pattern’ (24% and 28.7%). Then, the ‘annular-granular pattern’ was prevalent in BLK group (i.e. 81% of cases), the ‘red structures and lines’ and ‘keratin plugs’ were prevalent in PAK group (35% and 33% of cases, respectively). The ‘evident and regular follicular openings’, ‘diffuse opaque yellow-brown pigmentation’ and ‘moth-eaten borders’ were prevalent in the SL group (55.4%, 48.8% and 42.7% of cases). The ‘comedo-like openings’, ‘fat fingers’ and ‘milia-like cysts’ were slightly more prevalent in the SK group (23.7%, 15.8% and 13.2% of cases, respectively). Finally, the ‘lightbrown fingerprint-like structures/areas’ were prevalent in SK (31.6%) and SL (30%) groups than in other aPFLs classes.

Figure 1 compares the intuitive clinical diagnoses with the histopathological diagnoses: (i) the most common misdiagnosis was LM instead of LMM (41%), followed by SL instead of PAK (19%), LM instead of AN (19%), SL instead of LM (15%), SK instead of AN (15%) and LMM instead of LM (12%); (ii) BLK showed the highest percentage of correct intuitive diagnosis (67%), followed by SL (50%), AN (45%), PAK (42%), LMM/LM (both 41%) and SK (37%). Concerning the device used, we observed a predominance (70%) of personal computer alone (i.e. 1637 out of 2445 online evaluations), followed by notebook (n = 420), smartphone (n = 261) and tablet (n = 65). Multiple devices were used as follows: personal computer + notebook (22 times), smartphone + notebook (33 times) or all three together (5 times).

Facial iDScore model

The facial iDScore model was created with 10 parameters: three objective clinical data items (i.e. maximum diameter ≥ 8 mm, age ≥ 70 years, male sex), and seven dermoscopic features, each associated with a different partial score (Table 3). Presence of rhomboidal structures, obliterated follicle openings or target-like pattern was rated 2, presence of hyperpigmented follicle openings was rated 1, absence of diffuse opaque yellow-brown pigmentation or light brown fingerprint-like structures/areas or red structures and lines was also rated 1. Table 4 illustrates the distribution of

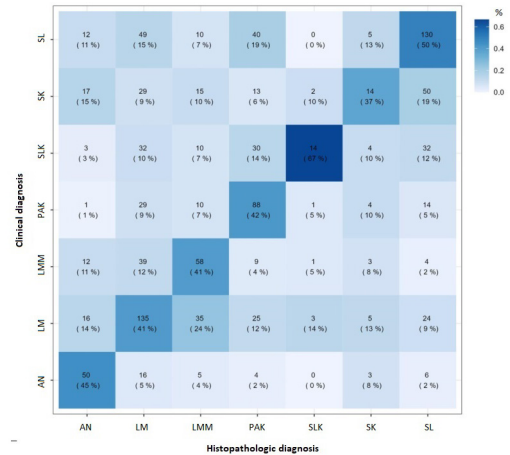


FIGURE 1 Comparison of intuitive clinical diagnosis assessed by 154 dermatologists on the subset of 1111 atypical pigmented facial lesions with the corresponding histopathologic reports.

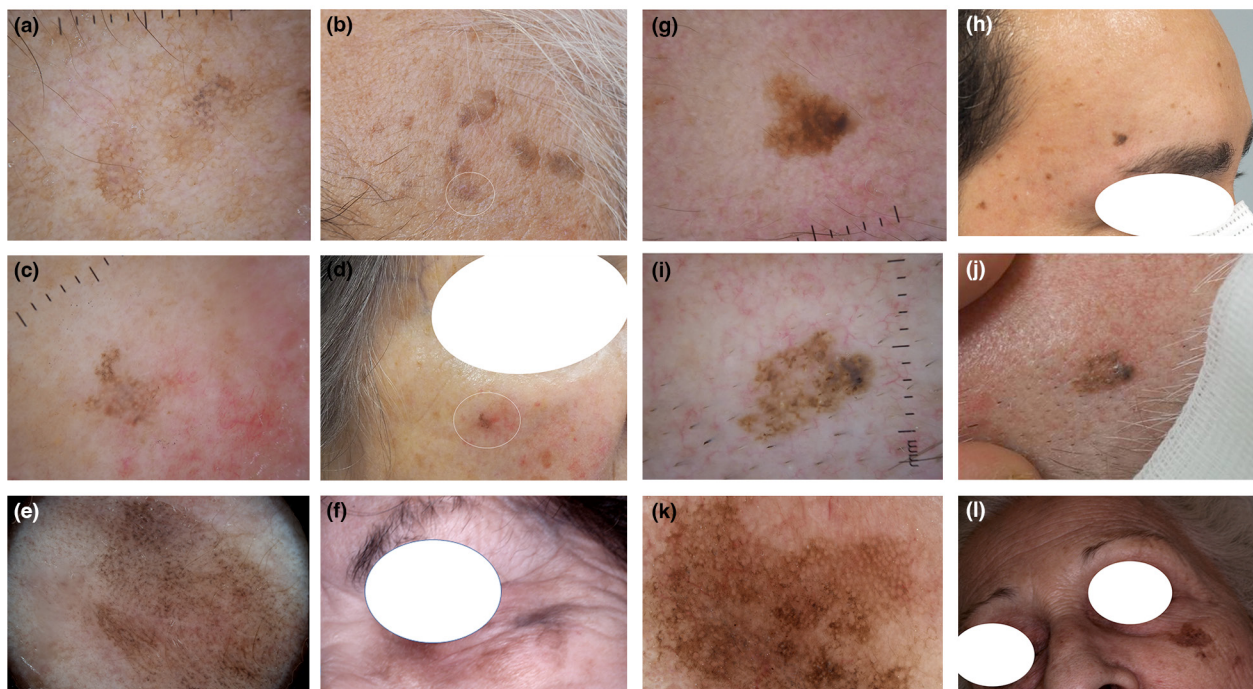
TABLE 3 Checklist selected by risk scoring classifier system for the differential diagnosis of LM/LMM from other clinically and dermoscopically atypical pigmented facial lesions (aPFLs).

10 Variables	Coefficient	
Maximum diameter ≥ 8 mm	3	
Age ≥ 70 years	2	
Male sex	1	
Presence of rhomboidal structures	2	
Presence of obliterated follicular openings	2	
Presence of target-like pattern	2	
Presence of hyperpigmented follicular openings	1	
Absence of diffuse opaque yellow-brown pigmentation	1	
Absence of lightbrown fingerprint-like structures/ areas	1	
Absence of red structures and lines	1	
Total score	0–16	
Partial score	Risk classification	Management suggestion
S = 0–2	Low-risk lesion	Short follow-up
S = 3–9	Medium-risk lesion	RCM/biopsy
S = 10–16	High-risk lesion	Biopsy/ complete excision

partial scores (S) between the sets of 1111 and 86 aPFLs in the training, testing and validation phases. An aPFL with S = 0–2 was considered low-risk, and only monitoring was suggested; an aPFL with S = 3–9 was considered medium-risk, and RCM examination was suggested (or if not available, a punch biopsy); an aPFL with S = 10–16 was considered high-risk, and immediate biopsy or complete excision was suggested. Figure 2 shows some examples of challenging aPFLs with overlapping clinical and dermoscopic features and facial iDScores.

TABLE 4 Frequency of distribution of partial score throughout the training, testing and validation set according to 2396 dermoscopic assessments on atypical pigmented facial lesions (aPFLs).

Risk score	Training phase (dataset of 1111 aPFLs)		Testing phase (dataset of 1111 aPFLs)		Validation phase (dataset of 86 aPFLs)	
	Frequency in 673 evaluations of 472 LM/LMM cases	Frequency in 1042 evaluations of 639 other aPFLs cases	Frequency in 168 evaluations of 472 LM/LMM cases	Frequency in 261 evaluations of 639 other aPFLs cases	Frequency in 75 evaluations of 27 LM/LMM cases	Frequency in 177 evaluations of 59 aPFLs cases
0	0 (0.0%)	1 (0.1%)	0 (0.0%)	0 (0.0%)	0 (0.0%)	4 (2.3%)
1	0 (0.0%)	18 (1.7%)	0 (0.0%)	1 (0.4%)	0 (0.0%)	10 (5.6%)
2	0 (0.0%)	55 (5.3%)	1 (0.6%)	14 (5.4%)	0 (0.0%)	20 (11.3%)
S=0-2	0 (0.0%)	74 (7.1%)	1 (0.6%)	15 (5.7%)	0 (0.0%)	34 (19.2%)
3	2 (0.3%)	95 (9.1%)	4 (2.4%)	22 (8.4%)	0 (0.0%)	26 (14.7%)
4	9 (1.3%)	119 (11.4%)	5 (3.0%)	21 (8.0%)	13 (17.3%)	33 (18.6%)
5	26 (3.9%)	152 (14.6%)	4 (2.4%)	53 (20.3%)	8 (10.7%)	25 (14.1%)
6	51 (7.6%)	170 (16.3%)	12 (7.1%)	43 (16.5%)	11 (14.7%)	27 (15.3%)
7	60 (8.9%)	139 (13.3%)	14 (8.3%)	32 (12.3%)	7 (9.3%)	6 (3.4%)
8	95 (14.1%)	120 (11.5%)	21 (12.5%)	30 (11.5%)	11 (14.7%)	9 (5.1%)
9	94 (14.0%)	74 (7.1%)	30 (17.9%)	15 (6.1%)	5 (6.7%)	4 (2.3%)
S=3-9	337 (50.1%)	869 (83.4%)	90 (53.6%)	216 (82.8%)	75 (73.3%)	130 (73.4%)
10	74 (11.0%)	48 (4.6%)	15 (8.9%)	14 (5.4%)	6 (8.0%)	4 (2.3%)
11	87 (12.9%)	35 (3.4%)	15 (8.9%)	9 (3.4%)	2 (2.7%)	6 (3.4%)
12	54 (8.0%)	12 (1.2%)	14 (8.3%)	3 (1.1%)	2 (2.7%)	0 (0.0%)
13	52 (7.7%)	2 (0.2%)	14 (8.3%)	0 (0.0%)	4 (5.3%)	1 (0.6%)
14	36 (7.7%)	2 (0.2%)	11 (6.5%)	2 (0.8%)	0 (0.0%)	0 (0.0%)
15	24 (3.6%)	0 (0.0%)	5 (3.0%)	0 (0.0%)	6 (8.0%)	2 (1.1%)
16	9 (1.3%)	0 (0.0%)	3 (1.8%)	1 (0.4%)	0 (0.0%)	0 (0.0%)
S=10-16	336 (49.9%)	99 (9.5%)	77 (45.8%)	29 (11.1%)	20 (26.7%)	13 (7.3%)
Total evaluations	673	1042	168	261	75	177

**FIGURE 2** Example of different aPFLs of the face and corresponding iDScore: 10 mm pigmented actinic keratosis in the temporal area of a 73-year-old woman (a, b) score 5; a 8.5 mm lentigo maligna on the forehead of a 75-year-old man, score 14 (c, d); a 6 mm seborrheic-lichenoid keratosis of the orbital area in a 81-year-old woman, score 3 (e, f); a 5 mm atypical nevus of the forehead in a 43-year-old man, score 2 (g, h); a 7 mm seborrheic keratosis on the cheek of a 50-year-old man; a 15 mm solar lentigo on the cheek of a 88-year-old woman (k, l).

Diagnosis study

Figure 3 compares the performance obtained with *facial iDScore*-aided diagnosis and with intuitive clinical diagnosis by 157 dermatologists/residents in the training, testing and validation phases. On average, the *facial iDScore*-aided diagnosis was more accurate in differentiating LM/LMM from other aPFLs (+40%). AUC values for the *facial iDScore* were 0.83, 0.79 and 0.77 on the training, testing and validation set, respectively. For a score threshold of $S_t=2$, sensitivity was 100% (Table 4) and specificity 19.2%; for $S_t=9$, sensitivity was 73.3% and specificity 26.7%. On the contrary, the average diagnostic accuracy of intuitive clinical diagnosis was 43.5%, including a mean accuracy of 45.1% on 444 cases with both clinical and dermoscopic data, and 41.2% on 667 cases with dermoscopic picture only. Less experienced dermatologists (skill levels I and II) reached an average accuracy of 42.1%, while more experienced dermatologists (skill levels III + IV) obtained a mean accuracy of 44.2%.

Management study

Figure 4 compares the management response rates (follow-up/reflectance confocal microscopy/biopsy) of the 157 dermatologists/residents assessed through 2445 online evaluations with the corresponding *facial iDScores*. In the malignant aPFLs group ($n=499$), dermatologists/residents chose follow-up in 23%, RCM in 24% and biopsy in 53% of 953 online evaluations; according to the *facial iDScore* model, RCM was suggested in 53% and biopsy in 47% of evaluations (only one dermoscopically featureless LM scored $S=1$ in the testing phase (Table 4) and was evaluated as to be followed-up and to be assigned to RCM by 2 participants, Figure 4). In the benign aPFLs group ($n=698$), dermatologists prescribed follow-up in 53%, RCM in 25% and skin biopsy in 23% of 1492 evaluations; conversely, the *facial iDScore* model suggested follow-up in 9%, RCM in 82% and biopsy in 9% of evaluations.

DISCUSSION

Dermoscopic differential diagnosis of malignant and benign pigmented lesions of the face is still a clinical challenge.^{1,9,13,28–30} Indeed, a high ‘number needed to biopsy’ ratio, ranging from 7.5 to 40.5, is currently reported. This has a negative impact on healthcare costs and aesthetic outcomes.^{31,35} Histology remains the gold standard for diagnostic confirmation, though in some cases it may be challenging for the pathologist to differentiate between early LM and ultraviolet-induced melanocytic hyperplasia in chronically sun-damaged skin.^{1,32,36}

The present scoring classifier-based model is innovative in many respects. Firstly, it was specifically designed to differentiate LM/LMM from five simulators (PAK/SL/BLK/AN/

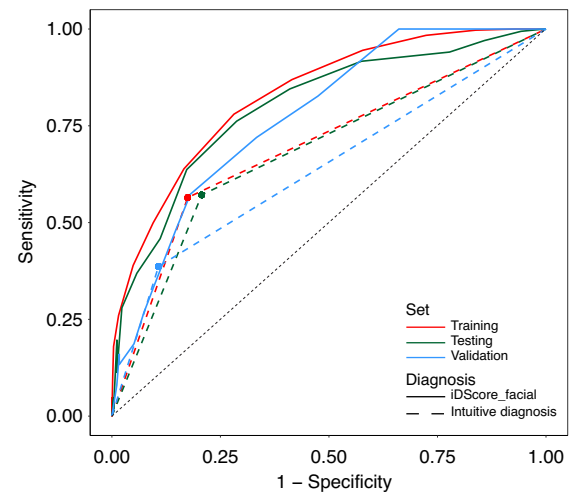


FIGURE 3 Comparative analysis of performance of intuitive diagnosis and *facial iDScore*-aided diagnosis by 154 dermatologists on 1197 atypical pigmented facial lesions, expressed as average AUC (area under the ROC curve) in training/testing/validation phases. The *facial iDScore* showed an AUC of 0.83 [IC 95%: 0.811–0.849] on the training set (red line), 0.79 [IC 95%: 0.757–0.843] on the testing dataset (green line) and 0.774 [IC 95%: 0.716–0.832] on validation set (blue line). Estimated AUC for intuitive clinical diagnosis was 0.69 [IC 95%: 0.673–0.717] on the training set (red dashed line), 0.68 [IC 95%: 0.637–0.727] on the testing set (green dashed line) and 0.63 [IC 95%: 0.579–0.699] (blue dashed line).

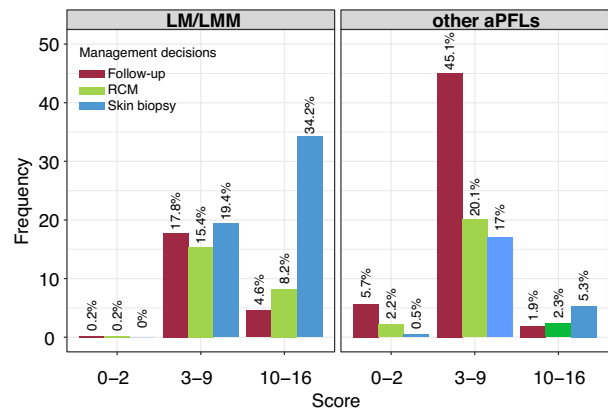


FIGURE 4 Management study: the responses (%) concerning management decisions assessed by 150 dermatologists/residents through 2445 online evaluations (ordinate) are compared with corresponding *facial iDScore* values (abscissa).

SK) instead of being limited to a univocal differential diagnosis.³⁷ Secondly, it is the first model trained over a dataset including a percentage of SK and AN cases with equivocal appearance in the group of benign simulators. These types are not uncommon in clinical practice, especially on photodamaged facial skin.^{18–24} Thirdly, while other existing checklists were based on pattern analysis by very few selected experts, the present model relies on a pool of 34,244 dermoscopic data items obtained by 147 dermoscopists. These data were further processed to obtain a statistically

significant dermoscopic signature for each lesion, a method that also helps avoid evaluator bias.^{37–40} Fourthly, the model maintained satisfactory accuracy when tested over a new heterogeneous set of 86 difficult lesions with higher variability (i.e. ‘validation set’) confirming the robustness of the statistical method.⁴¹

Based on the data collected through teledermoscopic testing, the dermoscopic differential diagnosis of seven aPFLs turned out to be challenging for less experienced and expert dermatologists alike (accuracies of 42% and 44%, respectively) and the addition of the clinical picture did not help significantly (3% improvement in accuracy). In particular, many SL were misdiagnosed as LM and PAK, while AN were interpreted as LM or SK. The differentiation between LM and LMM was difficult for all participants, 41% of LMM cases being misdiagnosed as LM and 12% of LM cases as LMM.²⁵

The proposed *facial iDScore* model allows rapid and easy calculation of the lesion partial score during a visit. It ranges from 0 to 16, without negative values or decimals, and is based on three items of objective data, four ‘positive’ dermoscopic features and two ‘negative’ dermoscopic features. This is also in line with the dermoscopic inverse approach recently proposed for managing flat pigmented lesions of the face.⁴² Based on the diagnostic and management tests described here, we conclude that the *facial iDScore* model offers multiple advantages in terms of diagnosis and management, namely (i) an increase (+40%) in the overall number of correct diagnoses; (ii) a significant increase (+59%) in correct LM/LMM diagnoses; (iii) a significant reduction (–41.5%) in the number of excisions of benign lesions; (iv) a relevant increase (+65.8%) in the number of LM/LMM cases sent for biopsy and RCM, cases which would otherwise merely have been monitored.

Two limitations of the study are its retrospective design which determined the final composition of the *facial iDScore* dataset of 41% of LM/LMM and 59% of aPFLs, thus introducing possible selection bias. Second, although the clinical picture was available for only 60% of aPFLs, the final diagnostic accuracy did not appear to be affected.

It is currently debated whether computer deep-learning-based algorithms, such as appropriately trained convolutional neural networks, may surpass dermatologists in the non-invasive diagnosis of challenging equivocal pigmented skin lesions.^{43,44} These tools are still mainly limited to research settings. Most dermatologists find it hard to trust a numerical output or have trouble translating the number into a practical management decision.^{45,46} In this scenario, a simple Bayesian model based on scoring classifiers, such as the *facial iDScore* model introduced here, can be proposed as a rapid and easy tool for variously experienced dermatologists following the clinical dermoscopic examination of aPFLs.

AFFILIATIONS

¹Dermatology Unit, Department of Medical, Surgical and Neurosciences, University of Siena, Siena, Italy

²Department of Medical Biotechnologies, University of Siena, Siena, Italy

³Department of Dermatology, Institute of Medical Sciences, Medical College of Rzeszow University, Rzeszów, Poland

⁴Soc Dermatologia Pistoia-Prato, USL Toscana Centro, Pistoia, Italy

⁵Dermatology Clinic, Ospedale di Trieste, Trieste, Italy

⁶Department of Medical Oncology, Centro di Riferimento Oncologico di Aviano (CRO), IRCCS, Aviano, Italy

⁷Dermatology Unit, University of Campania Luigi Vanvitelli, Naples, Italy

⁸Centro Oncologico ad Alta Tecnologia Diagnostica, Azienda Unità Sanitaria Locale, IRCCS di Reggio Emilia, Reggio Emilia, Italy

⁹Department of Dermatology, University of Modena and Reggio Emilia, Modena, Italy

¹⁰Vita-Salute San Raffaele University, Milan, Italy

¹¹Dermatology Clinic, IRCCS San Raffaele Scientific Institute, Milan, Italy

¹²Department of Dermatology and Venereology, Institute of Clinical Sciences, Sahlgrenska Academy, Sahlgrenska University Hospital, University of Gothenburg, Gothenburg, Sweden

¹³Department of Dermatology and Venereology, Region Västra Götaland, Sahlgrenska University Hospital, Gothenburg, Sweden

¹⁴First Department of Dermatology, Aristotle University, Thessaloniki, Greece

¹⁵Dermatology Clinic, Medical Faculty, University of Nis, Niš, Serbia

¹⁶Skin Cancer Unit, Scientific Institute of Romagna for the Study of Cancer, IRCCS, IRST, Meldola, Italy

¹⁷Department of Dermatology, University of Parma, Parma, Italy

¹⁸Dermatology Unit, Department of Experimental, Diagnostic and Specialty Medicine (DIMES), University of Bologna, Bologna, Italy

¹⁹Dermatology, IRCCS Azienda Ospedaliero Universitaria di Bologna, Bologna, Italy

²⁰Department of Dermatology, Hôpital Erasme, Université Libre de Bruxelles, Brussels, Belgium

²¹Groupe d’Imagerie Cutanée Non-Invasive, Société Française de Dermatologie, Paris, France

²²Department of Dermatology, Institut Jules Bordet, Brussels, Belgium

²³Department of Dermatology, Policlinico Umberto I, University of Rome La Sapienza, Rome, Italy

²⁴Dermatology Unit, University Hospital of St-Etienne, Saint Etienne, France

²⁵Department of Ophthalmology, University of Catania, Catania, Italy

²⁶Bioengineering and Biomedical Data Science Lab, Department of Medical Biotechnologies, University of Siena, Siena, Italy

ACKNOWLEDGEMENTS

EADV European Teledermatology task force.

CONFLICT OF INTEREST STATEMENT

None.

FUNDING INFORMATION

None.

DATA AVAILABILITY STATEMENT

The authors confirm that the data supporting the findings of this study are available within the article [and/or] its supplementary materials.

ETHICS STATEMENT


The patients in this manuscript have given written informed consent to the publication of their case details.

ORCID


Linda Tognetti  <https://orcid.org/0000-0002-6691-4310>

Alessandra Cartocci  <https://orcid.org/0000-0002-1818-6275>

Magdalena Żychowska  <https://orcid.org/0000-0001-8268-0529>

Maria Antonietta Pizzichetta  <https://orcid.org/0000-0002-4201-8490>

Elvira Moscarella  <https://orcid.org/0000-0001-5160-8997>

Francesca Farnetani  <https://orcid.org/0000-0001-7088-9077>

Stefania Guida  <https://orcid.org/0000-0002-8221-6694>

John Paoli  <https://orcid.org/0000-0003-1326-8535>

Aimilios Lallas  <https://orcid.org/0000-0002-7193-0964>

Emi Dika  <https://orcid.org/0000-0003-3186-2861>

Mariano Suppa  <https://orcid.org/0000-0002-9266-0342>

Giuseppe Argenziano  <https://orcid.org/0000-0003-1413-8214>

[org/0000-0003-1413-8214](https://orcid.org/0000-0003-1413-8214)

Giovanni Pellacani  <https://orcid.org/0000-0002-7222-2951>

[org/0000-0002-7222-2951](https://orcid.org/0000-0002-7222-2951)

REFERENCES

- Iznardo H, Garcia-Melendo C, Yélamos O. Lentigo maligna: clinical presentation and appropriate management. *Clin Cosmet Investig Dermatol*. 2020;13:837–55.
- Naik PP. Diagnosis and management of lentigo maligna: clinical presentation and comprehensive review. *J Skin Cancer*. 2021;2021:7178305.
- Moreno A, Manrique-Silva E, Virós A, Requena C, Sanmartín O, Traves V, et al. Histologic features associated with an invasive component in lentigo Maligna lesions. *JAMA Dermatol*. 2019;155(7):782–8. <https://doi.org/10.1001/jamadermatol.2019.0467>
- Gérard E, Cogrel O, Goehrs C, Guillot P, Ricard A, Pham-Ledard A, et al. Clinical features associated with the invasive component in lentigo maligna of the head and neck: a retrospective study of 175 cases. *Ann Dermatol Venereol*. 2022;149(4):258–63.
- Dika E, Lambertini M, Patrizi A, Misciali C, Scarfi F, Pellacani G, et al. Folliculotropism in head and neck lentigo maligna and lentigo maligna melanoma. *J Dtsch Dermatol Ges*. 2020;19:223–9.
- Tiodorovic-Zivkovic D, Argenziano G, Lallas A, Thomas L, Ignjatovic A, Rabinovitz H, et al. Age, gender, and topography influence the clinical and dermoscopic appearance of lentigo maligna. *J Am Acad Dermatol*. 2015;72(5):801–8.
- Ferrara G, Ligrone L, Zalaudek I, Mordente I, Argenziano G. Lentigo maligna in a young adult. *Dermatology*. 2008;217(1):66–8.
- Duarte AF, Sousa-Pinto B, Barros AM, Haneke E, Correia O. Lentigo Maligna – not always a face and neck disease of the elderly. *Dermatology*. 2018;234(1–2):37–42. <https://doi.org/10.1159/000489397>
- Carapeba A, de Oliveira LM, Alves Pineze M, Alborghetti NG. Is dermoscopy a good tool for the diagnosis of lentigo maligna and lentigo maligna melanoma? A meta-analysis. *Clin Cosmet Investig Dermatol*. 2019;12:403–14.
- Schiffner RB, Schiffner-Rohe J, Vogt T, Landthaler M, Wlotzke U, Cognetta AB, et al. Improvement of early recognition of lentigo maligna using dermoscopy. *J Am Acad Dermatol*. 2000;42(1 Pt 1):25–32.
- Fensterseifer GS, Lodi AP, Dantas ML, Boff AL, Lovatto L. Lentigo Maligna of the face: the importance of clinical, dermoscopic, and histological correlation. *Dermatol Pract Concept*. 2019;9(4):292–4.
- Stolz W, Schiffner R, Burgdorf WH. Dermatoscopy for facial pigmented skin lesions. *Clin Dermatol*. 2002;20(3):276–8.
- Lallas A, Argenziano G, Moscarella E, Longo C, Simonetti V, Zalaudek I. Diagnosis and management of facial pigmented macules. *Clin Dermatol*. 2014;32(1):94–100.
- Costa-Silva M, Calistru A, Barros AM, Lopes S, Esteves M, Azevedo F. Dermatoscopy of flat pigmented facial lesions—evolution of lentigo maligna diagnostic criteria. *Dermatol Pract Concept*. 2018;8(3):198–203.
- Pralong P, Bathelier E, Dalle S, Poulalhon N, Debarbieux S, Thomas L, et al. Dermatoscopy of lentigo maligna melanoma: report of 125 cases. *Br J Dermatol*. 2012;167(2):280–7.
- Bollea-Garlatti LA, Galimberti GN, Galimberti RL. Lentigo maligna: keys to dermoscopic diagnosis. *Actas Dermosifiliogr*. 2016;107(6):489–97.
- Witta S, Bershaw A, Farah RS, Berg B, Goldfarb N. Dermatoscopy findings of a one mm lentigo maligna. *Dermatol Online J*. 2018;24(7):13030/qt5xp740wn.
- Şahin MT, Öztürkcan S, Ermertcan AT, Güneş AT. A comparison of dermoscopic features among lentigo senilis/initial seborrheic keratosis, seborrheic keratosis, lentigo maligna and lentigo maligna melanoma on the face. *J Dermatol*. 2004;31(11):884–9.
- Akay BN, Kocyigit P, Heper AO, Erdem C. Dermatoscopy of flat pigmented facial lesions: diagnostic challenge between pigmented actinic keratosis and lentigo maligna. *Br J Dermatol*. 2010;163(6):1212–7.
- Tanaka M, Sawada M, Kobayashi K. Key points in dermoscopic differentiation between lentigo maligna and solar lentigo. *J Dermatol*. 2011;38(1):53–8.
- Lallas A, Tschandl P, Kyrgidis A, Stolz W, Rabinovitz H, Cameron A, et al. Dermoscopic clues to differentiate facial lentigo maligna from pigmented actinic keratosis. *Br J Dermatol*. 2016;174(5):1079–85.
- Ozbacivan O, Akarsu S, Ikiz N, Semiz F, Fetil E. Dermoscopic differentiation of facial lentigo Maligna from pigmented actinic keratosis and solar lentiginos. *Acta Dermatovenereol Croat*. 2019;27(3):146–52.
- Mazzei ME. Is it solar lentigo or lentigo Maligna? (it is not a nevus). *Actas Dermosifiliogr*. 2016;107(6):451–3.
- Zalaudek I, Cota C, Ferrara G, Moscarella E, Guitera P, Longo C, et al. Flat pigmented macules on sun-damaged skin of the head/neck: junctional nevus, atypical lentiginous nevus, or melanoma in situ? *Clin Dermatol*. 2014;32(1):88–93.
- Zoutendijk J, Koljenovic S, Wakkee M, Mooyaart AL, Nijsten T, van den Bos RR. Clinical findings are not helpful in detecting lentigo maligna melanoma in patients with biopsy-proven lentigo maligna. *J Eur Acad Dermatol Venereol*. 2022;36(12):2325–30.
- DeWane ME, Kelsey A, Oliviero M, Rabinovitz H, Grant-Kels JM. Melanoma on chronically sun-damaged skin: lentigo maligna and desmoplastic melanoma. *J Am Acad Dermatol*. 2019;81(3):823–33.
- Tognetti L, Cinotti E, Farnetani F, Lallas A, Paoli J, Longo C, et al. Development and implementation of a web-based international registry dedicated to atypical pigmented skin lesions of the face: teledermatologic investigation on epidemiology and risk factors. *Telederm J E Health*. 2023. <https://doi.org/10.1089/tmj.2022.0456>
- Pellacani G, Farnetani F, Ciardo S, Chester J, Kaleci S, Mazzoni L, et al. Effect of reflectance confocal microscopy for suspect lesions on diagnostic accuracy in melanoma: a randomized clinical trial. *JAMA Dermatol*. 2022;158(7):754–61.
- Tognetti L, Cartocci A, Balistreri A, Cataldo G, Cinotti E, Moscarella E, et al. The comparative use of multiple electronic devices in the Teledermoscopic diagnosis of early melanoma. *Telederm J E Health*. 2021;27(5):495–502.
- Xiong M, Charifa A, Chen CSJ. Lentigo maligna melanoma. *StatPearls* [internet]. Treasure Island, FL: StatPearls Publishing; 2022 Available from: <https://www.ncbi.nlm.nih.gov/books/NBK482163/> [Updated 2022 Oct 31]
- Nelson KC, Swetter SM, Saboda K, Chen SC, Curiel-Lewandrowski C. Evaluation of the number-needed-to-biopsy metric for the diagnosis of cutaneous melanoma: a systematic review and meta-analysis. *JAMA Dermatol*. 2019;155(10):1167–74.
- Star P, Guitera P. Lentigo maligna, macules of the face, and lesions on sun-damaged skin: confocal makes the difference. *Dermatol Clin*. 2016;34(4):421–9. <https://doi.org/10.1016/j.det.2016.05.005>
- Mataca E, Migaldi M, Cesinaro AM. Impact of dermoscopy and reflectance confocal microscopy on the histopathologic diagnosis of lentigo maligna/lentigo maligna melanoma. *Am J Dermatopathol*. 2018;40(12):884–9. <https://doi.org/10.1097/DAD.0000000000001212>
- Cinotti E, Fiorani D, Labeille B, Gonzalez S, Debarbieux S, Agozzino M, et al. The integration of dermoscopy and reflectance confocal microscopy improves the diagnosis of lentigo maligna. *J Eur Acad Dermatol Venereol*. 2019;33(10):e372–4.
- Marchetti MA, Yu A, Nanda J, Tschandl P, Kittler H, Marghoob AA, et al. Number needed to biopsy ratio and diagnostic accuracy for melanoma detection. *J Am Acad Dermatol*. 2020;83(3):780–7.
- Tognetti L, Cartocci A, Cinotti E, Moscarella E, Farnetani F, Carrera C, et al. Dermatoscopy of early melanomas: variation according to the anatomic site. *Arch Dermatol Res*. 2022;314(2):183–90.

37. Micantonio T, Neri L, Longo C, Grassi S, di Stefani A, Antonini A, et al. A new dermoscopic algorithm for the differential diagnosis of facial lentigo maligna and pigmented actinic keratosis. *Eur J Dermatol.* 2018;28(2):162–8.
38. Tognetti L, Cevenini G, Moscarella E, Cinotti E, Farnetani F, Mahlvey J, et al. An integrated clinical-dermoscopic risk scoring system for the differentiation between early melanoma and atypical nevi: the iD-Score. *J Eur Acad Dermatol Venereol.* 2018;32(12):2162–70.
39. Rubegni P, Tognetti L, Argenziano G, Nami N, Brancaccio G, Cinotti E, et al. A risk scoring system for the differentiation between melanoma with regression and regressing nevi. *J Dermatol Sci.* 2016;83(2):138–44.
40. Tognetti L, Cartocci A, Bertello M, Giordani M, Cinotti E, Cevenini G, et al. An updated algorithm integrated with patient data for the differentiation of atypical nevi from early melanomas: the idScore 2021. *Dermatol Pract Concep.* 2022;12:e2022134.
41. Tognetti L, Cevenini G, Moscarella E, Cinotti E, Farnetani F, Lallas A, et al. Validation of an integrated dermoscopic scoring method in an European teledermoscopy web platform: the iDScore project for early detection of melanoma. *J Eur Acad Dermatol Venereol.* 2020;34(3):640–7.
42. Lallas A, Lallas K, Tschandl P, Kittler H, Apalla Z, Longo C, et al. The dermoscopic inverse approach significantly improves the accuracy of human readers for lentigo maligna diagnosis. *J Am Acad Dermatol.* 2021;84(2):381–9.
43. Tschandl P, Rinner C, Apalla Z, Argenziano G, Codella N, Halpern A, et al. Human–computer collaboration for skin cancer recognition. *Nat Med.* 2020;26:1229–34.
44. Stiff KM, Franklin MJ, Zhou Y, Madabhushi A, Knackstedt TJ. Artificial intelligence and melanoma: a comprehensive review of clinical, dermoscopic, and histologic applications. *Pigment Cell Melanoma Res.* 2022;35(2):203–11.
45. Tognetti L, Bonechi S, Andreini P, Bianchini M, Scarselli F, Cevenini G, et al. A new deep learning approach integrated with clinical data for the dermoscopic differentiation of early melanomas from atypical nevi. *J Dermatol Sci.* 2021;101(2):115–22.
46. Tognetti L, Cartocci A, Cinotti E, Moscarella E, Farnetani F, Lallas A, et al. The impact of anatomical location and sun exposure on the dermoscopic recognition of atypical nevi and early melanomas: usefulness of an integrated clinical-dermoscopic method (iDScore). *J Eur Acad Dermatol Venereol.* 2021;35(3):650–7.

SUPPORTING INFORMATION

Additional supporting information can be found online in the Supporting Information section at the end of this article.

How to cite this article: Tognetti L, Cartocci A, Żychowska M, Savarese I, Cinotti E, Pizzichetta MA, et al. A risk-scoring model for the differential diagnosis of lentigo maligna and other atypical pigmented facial lesions of the face: The *facial iDScore*. *J Eur Acad Dermatol Venereol.* 2023;37:2301–2310. <https://doi.org/10.1111/jdv.19360>