

## ORIGINAL ARTICLE: OBSERVATION STUDY

# Penumbra Indigo Percutaneous Aspiration Thrombectomy System in the treatment of Aortic Endograft Iliac Limb Occlusion: Results from an Italian Multicentre Registry <sup>☆</sup>

Paolo Spath <sup>a,b,\*</sup>, Edoardo Pasqui <sup>c</sup>, Domenico Angiletta <sup>d</sup>, Angelo Spinazzola <sup>e</sup>, Fabrizio Chegai <sup>f</sup>, Giacomo Isernia <sup>g</sup>, Sandro Lepidi <sup>h</sup>, Roberto Silingardi <sup>i</sup>, Gianmarco de Donato <sup>c</sup>, Mauro Gargiulo <sup>a,j</sup>, on behalf of the Italian Multicentre Thrombo-Aspiration in ILO Study Group <sup>†</sup>

<sup>a</sup> Vascular Surgery, University of Bologna, DIMEC, Bologna, Italy

<sup>b</sup> Department of Vascular Surgery, Hospital "Infermi" Rimini, AUSL Romagna, Rimini, Italy

<sup>c</sup> Vascular Surgery, University of Siena, DSMCN, Siena, Italy

<sup>d</sup> Department of Vascular Surgery, University of Bari, Bari, Italy

<sup>e</sup> Interventional Radiology, Unit of Radiology, ASST-Crema, Crema, Italy

<sup>f</sup> Vascular and Interventional Radiology, Unit of Radiology, Hospital Viterbo, Viterbo, Italy

<sup>g</sup> Department of Vascular and Endovascular Surgery, University of Perugia, Perugia, Italy

<sup>h</sup> Department of Vascular Surgery, University Hospital of Trieste, Trieste, Italy

<sup>i</sup> Department Vascular Surgery of Modena, University of Modena and Reggio Emilia, Modena, Italy

<sup>j</sup> Bologna Metropolitan Vascular Surgery Unit, IRCCS Azienda Ospedaliero-Universitaria S. Orsola, Bologna, Italy

## WHAT THIS PAPER ADDS

This paper reports for the first time the safety and effectiveness of the Indigo (Penumbra Inc., Alameda, CA, USA) percutaneous aspiration thrombectomy system for the clinical presentation of iliac limb occlusion (ILO) after endovascular aortic repair, and analyses the results from an Italian multicentre registry. These results report a promising success rate of 94% after use of the Indigo system with or without adjunctive procedures, and freedom from recurrence of limb occlusion at one year. These results may lead to a change in treatment option for the treatment of complex ILO, giving a valid alternative to traditional or more invasive procedures.

**Objective:** This study aimed to evaluate the safety and effectiveness of the Penumbra Indigo percutaneous aspiration thrombectomy (PAT) system in the clinical presentation of iliac limb occlusion (ILO) after endovascular aortic repair (EVAR).

**Methods:** A retrospective, observational, multicentre study conducted in eight Italian vascular centres. Consecutive patients presenting with ILO after EVAR were eligible. To assess vessel revascularisation, Thrombo-aspiration In Peripheral Ischaemia (TIPI) classification (score 0–3) was used at presentation (t1), after PAT (t2), and after adjunctive procedures (t3). Successful revascularisation was considered TIPI 2–3 (near complete or complete). Primary intra-operative outcomes were technical success (TS) of Indigo PAT and combined TS of PAT associated with adjunctive procedures when needed. Primary follow up outcomes were safety and effectiveness at one, six, and 12 months.

**Results:** From September 2019 to December 2021, there were 48 ILO and 17 patients (35%) [median age 75 years, IQR 71, 83 years; male, 14 (82%); urgent, 8 (47%)] were treated and enrolled. The median time after primary EVAR was 24 months (IQR 0, 42 months). The median clot age from ILO diagnosis to PAT was three days (IQR 1, 12 days). Ten patients (59%) presented with limb threatening ischaemia. At t1, TIPI 0 and 1 was present in 13 (76%) and four (24%) cases, respectively. At t2, primary TS (TIPI 2–3) was achieved in 14 cases (82%) after Indigo PAT ( $p < .001$ ). Fifteen patients (88%) required adjunctive procedures (14 re-linings, one surgical patch angioplasty). At t3, combined TS was achieved in 16 cases (94%). Intra-operative complication included one (6%) distal embolisation, treated successfully. The 30 day mortality was one case (6%) due to pneumonia. At one, six, and 12 months, clinical success was 100% without ILO recurrence. The median follow up was 23 months (IQR 11, 41 months): at 18 months, survival and freedom from re-intervention were  $91 \pm 8\%$  and  $90 \pm 9\%$ , respectively.

**Conclusion:** This study reports for the first time the efficacy and safety of Penumbra Indigo PAT for ILO after EVAR, with promising technical and clinical success up to one year.

<sup>†</sup> A list of the authors in the collaborative study group is included in [Appendix A](#).

<sup>☆</sup> The preliminary results of this study were presented as an abstract at the European Society of Vascular Surgery 36th Annual Meeting, 20–23 September 2022, Rome, Italy.

\* Corresponding author. Vascular Surgery, University of Bologna, Policlinico S. Orsola-Malpighi, via Massarenti 9, 40138 Bologna, Italy. Tel.: +39 051 214 3288, +39 051 214 4244; fax: +39 051 214 4305.

E-mail address: [paolo.spath@gmail.com](mailto:paolo.spath@gmail.com); [paolo.spath@auslromagna.it](mailto:paolo.spath@auslromagna.it); [paolo.spath2@unibo.it](mailto:paolo.spath2@unibo.it) (Paolo Spath).

1078-5884/© 2023 The Authors. Published by Elsevier B.V. on behalf of European Society for Vascular Surgery. This is an open access article under the CC BY-NC-ND license (<http://creativecommons.org/licenses/by-nc-nd/4.0/>).

<https://doi.org/10.1016/j.ejvs.2023.04.008>

**Keywords:** Complex endovascular repair, Endovascular aortic repair, Endovascular treatment, Iliac limb occlusion, Limb ischaemia, Mechanical thrombo-aspiration, Percutaneous aspiration thrombectomy

Article history: Received 3 October 2022, Accepted 12 April 2023, Available online 20 April 2023

© 2023 The Authors. Published by Elsevier B.V. on behalf of European Society for Vascular Surgery. This is an open access article under the CC BY-NC-ND license (<http://creativecommons.org/licenses/by-nc-nd/4.0/>).

## INTRODUCTION

Iliac limb occlusion (ILO) is an endovascular aortic repair (EVAR) for abdominal aortic aneurysm complication occurring with an incidence ranging from 0.8–5.9%.<sup>1–5</sup> ILO presents with different clinical patterns, from asymptomatic to claudication, rest pain, and acute limb ischaemia<sup>3</sup>, and may require re-intervention. Many factors may favour ILO, such as excessive oversizing, landing zone into the external iliac artery, presence of kinking, and specific graft selection.<sup>2,4,6,7</sup> Currently, a variety of procedures can be performed to resolve ILO as mentioned in the latest European guidelines on the management of abdominal aorto-iliac artery aneurysms.<sup>8</sup> Extra-anatomical bypass is currently the traditional and most frequently used procedure ranging from 37%<sup>3</sup> to 52%.<sup>6</sup>

Percutaneous aspiration thrombectomy (PAT) is an effective procedure in the cerebral and peripheral system<sup>9–11</sup> and is mentioned in recent guidelines for acute limb ischaemia (Recommendation 33)<sup>12</sup>, but no large series have yet described the application of this device in ILO.

The aim of this study was to describe the outcomes of the Penumbra Indigo PAT system for ILO and to analyse the results from an Italian multicentre registry.

## MATERIALS AND METHODS

### Patient selection

This was a retrospective, observational, multicentre study conducted in eight Italian centres. Patients treated with the Penumbra Indigo PAT system (Penumbra Inc., Alameda, CA, USA) for ILO after EVAR or fenestrated and branched EVAR procedures were enrolled. The enrolled patients were symptomatic patients presenting with claudication, rest pain or acute limb ischaemia due to ILO after EVAR (Figure 1). The length of time from occlusion to treatment with PAT was not considered an inclusion or exclusion criterion. All patients were classified according to the Rutherford classification of acute limb ischaemia<sup>8</sup>, ranging from 1 (viable) to 2b (immediately threatened). Patients with Rutherford III (irreversible) presentation, with infected endograft, life expectancy <1 year, or needing open surgical conversion were excluded.

### Description of the procedure

The devices under investigation were the Indigo systems as investigated in previous registries<sup>10,13</sup>, Indigo catheters from 3 - 8 Fr, and Indigo separators, with European Conformity (CE) mark, for peripheral arterial and venous system. The Indigo PAT generates aspiration from an

external vacuum generator, operating on an over the wire platform. During a standard procedure (Figure 1), after surgical exposure or percutaneous puncture of the arterial access, the catheter is placed proximally to the thrombotic occlusion. Angiography is performed to assess pre-operative patency [time 1 (t1)]. Suction is started while a large bore catheter is advanced into the thrombus with or without Indigo separator assistance to facilitate thrombus aspiration. Angiography is performed at the end of the PAT procedure [time 2 (t2)]. After PAT, adjunctive procedures are performed if considered necessary on a case by case basis and are performed according to the surgeon's preference and experience. Completion angiography is performed to define post-operative patency [time 3 (t3)]. A final lower limb angiogram or duplex ultrasound of peripheral vessels was performed in all cases. Given the pragmatic nature of this study, all centres applied their local standardised protocols for peri-operative management and follow up examinations and or imaging.

### Definition of primary outcomes

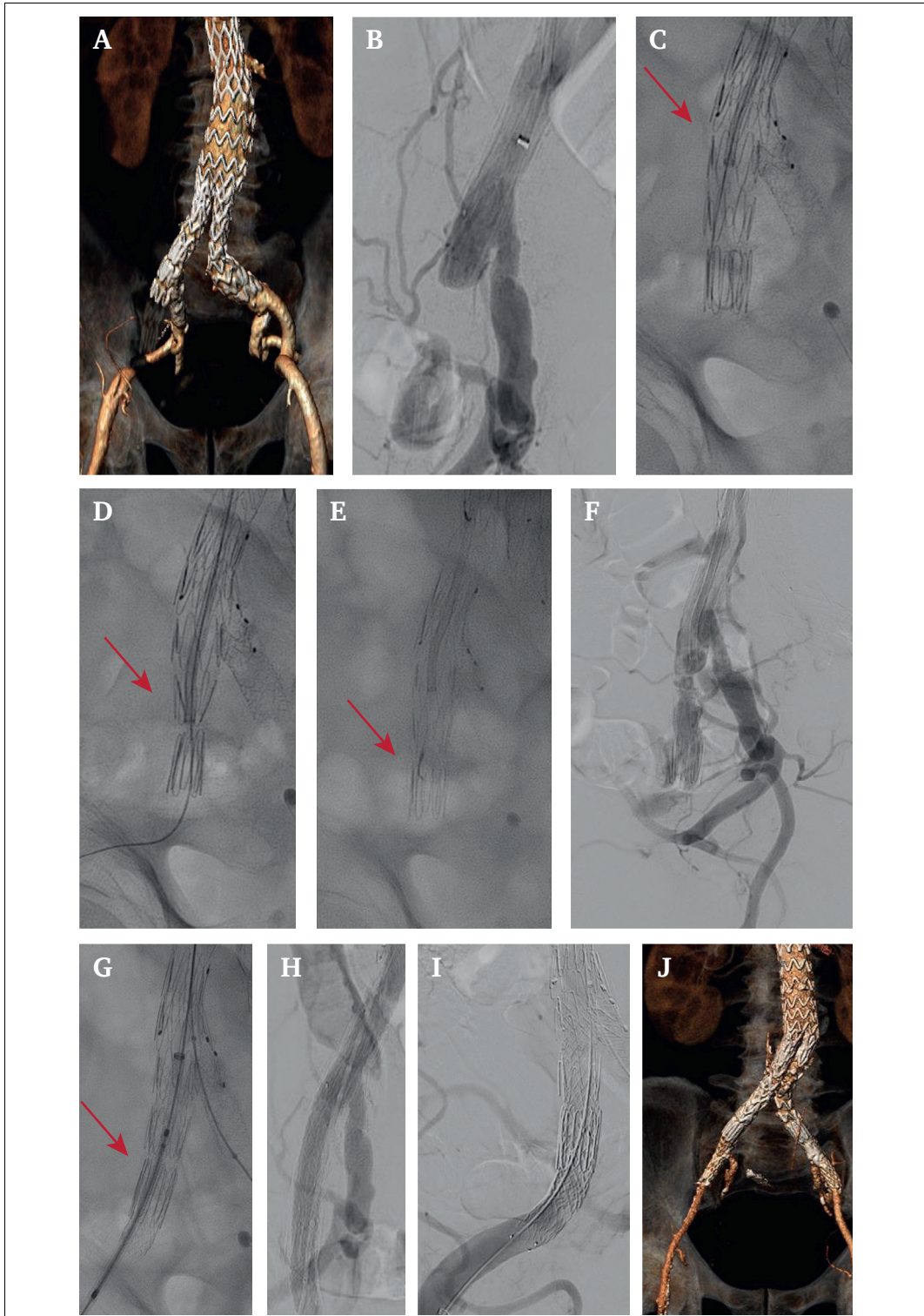
The primary intra-operative outcomes of the study were technical success (TS) of the Indigo PAT system, defined as the presence of successful recanalisation compared with pre-recanalisation assessment, and the combined TS of the revascularisation of PAT in association with adjunctive procedures when considered necessary. Patency was assessed by analysing the recorded angiograms at t1 (before PAT procedure), t2 (after PAT procedure), and t3 (after the adjunctive procedure if necessary) and was categorised according to the Thrombo-aspiration In Peripheral Ischaemia (TIPI) classification, a modification of the Thrombolysis in Myocardial Infarction (TIMI) classification, developed by the authors who participated in the INDIAN trial of Indigo PAT for acute limb ischaemia, reported recently.<sup>10</sup> The TIPI score ranged from 0 to 3 (Table 1).

Presence of a TIPI 2–3 flow (near complete or complete revascularisation of the target limb side of ILO) was considered successful revascularisation.

Primary follow up outcomes of the study were clinical success (TS + asymptomatic status) and clinical safety (clinical success without death, re-interventions related to the PAT procedure, recurrence of ILO, or major limb amputation) at one, six, and 12 months.

### Definitions of secondary outcomes

The intra-operative procedure related outcomes were time of fluoroscopy and procedure, contrast volume used,



**Figure 1.** (A) Computed tomography angiography (CTA) with 3D reconstruction showing limb occlusion after endovascular aortic repair and iliac branch device procedure, with thrombosis of the external component of the iliac branch device and external iliac artery. (B) Angiographic assessment at t1 of the occlusion showing a Thrombo-aspiration In Peripheral Ischaemia (TIPI) score 0. (C) CAT8 Indigo catheter advancing from the left brachial access (arrow). (D) Detail of the aspiration at maximum negative pressure (arrow). (E) Detail of the recanalisation using a separator (arrow). (F) Angiographic assessment at t2 of the recanalisation showing a TIPI score 2. (G) Adjunctive procedure with relining through bare metal stent (arrow) of the external iliac artery. (H,I) Angiographic details at t3 of the revascularisation after stent relining showing TIPI score 3. (J) CTA 3D reconstruction showing patency of the limb and satisfactory deployment of the endovascular materials.

**Table 1. Description of the Thrombo-aspiration In Peripheral Ischaemia (TIPI) score and the definition of successful revascularisation**

TIPI score	Description	Successful revascularisation
0	No recanalisation of thrombotic occlusion	No
1	Incomplete or partial recanalisation of thrombotic occlusion with no distal flow	No
2	Incomplete or partial recanalisation of the thrombotic occlusion	Yes
3	Complete recanalisation of the thrombotic occlusion with normal distal flow	Yes

The innovative classification for Thrombo-aspiration In Peripheral Ischaemia (TIPI), modified from Thrombolysis in Myocardial Infarction (TIMI) classification, described by de Donato G *et al.*<sup>10</sup>

bleeding, peripheral embolisation, blood loss, need for blood transfusion, type of adjunctive procedures, and intra-operative death.

Peri-operative and follow up secondary outcomes were length of hospital stay, death, major adverse events, re-interventions, and recurrence of limb occlusion.

Outcomes and post-operative events are reported according to current reporting standards for EVAR of the abdominal aorta and iliac arteries.<sup>8,12,14,15</sup>

### Regulatory approvals and data collection

Due to the multicentre, retrospective and observational nature of this study, ethical approval was received at each institution according to local protocols. The study complied with the Declaration of Helsinki. A leading collaborator was identified at each institution and was responsible for data collection, database completion, data exchange, and local regulatory approvals. Results were reported as retrospective analysis of a prospectively maintained aortic database from each institution. A uniform electronic data reporting form was jointly discussed and defined and maintained across all institutions.

### Statistical analysis

Continuous data were expressed as the median with interquartile range (IQR), where necessary. Categorical data were expressed as absolute values and percentages. The Pearson  $\chi^2$  test or the Relates-Samples McNemar Change Test were used to compare TS at t1, t2, and t3, based on the nature of the data and variables. Kaplan–Meier survival analysis was used for follow up outcomes performed using IBM SPSS Statistics version 28.0 (IBM Corp, Armonk, NY, USA). Statistical significance was set at a  $p$  value of  $<.050$ .

## RESULTS

### Patient selection and clinical data

From September 2019 to December 2021, among the eight recruiting centres, 1 346 EVAR procedures were evaluated and 48 (3.6%) ILOs were recorded, ranging from 2–6% in each centre. Indigo PAT was used in 17 ILO cases (35%), which matched the inclusion criteria for the study. In four cases (8%) the treatment was conservative due to absence of symptoms. The other types of procedures and conservative treatments are summarised in Table 2. One case was excluded due to contemporary type Ia endoleak requiring open surgical conversion.

Of the 17 included patients, none were bilateral and 10 (59%) were right sided. Eight patients (47%) were treated urgently. Median freedom from ILO from primary EVAR was 24 months (IQR 0, 42 months), and two cases (12%) were treated for ILO detected immediately after the EVAR procedure. The reason for ILO was kinking of graft component ( $n = 4$ ; 24%), poor run off flow ( $n = 3$ ; 18%), iliac vessel tortuosity ( $n = 2$ ; 12%), and coagulopathy ( $n = 1$ ; 6%). In the remaining cases the reason was unknown.

Ten patients (59%) presented with symptoms of limb threatening ischaemia: any form of sensory loss with motor deficit in seven cases (41%) and rest pain in three cases (18%). Median clot longevity from diagnosis of ILO to PAT was three days (IQR 1, 12 days), and three cases (18%) were treated after 14 days (15, 30, and 120 days, respectively). All details of the pre-operative risk factors, type of primary procedures, and patient presentation are listed in Table 3.

### Procedural details and intra-operative outcomes results

Overall procedural details were calculated for the 17 procedures and are shown in Table 4. Nine cases were treated from surgical femoral arterial access. Intra-operative complications triggered by Indigo PAT system included one (6%) intra-operative distal embolisation treated successfully in the same procedure with thrombo-aspiration. After completion of the PAT procedure, 15 cases (88%) required an adjunctive procedure, 14 (82%) endovascular and one (6%) surgical (Table 4).

Table 5 and Figure 2 report the primary intra-operative outcomes regarding TIPI assessment at first angiogram (t1), after the PAT procedure (t2), and after combination with an adjunctive procedure (t3). At t1 successful revascularisation (TIPI 2–3) was not present in any cases, whereas at t2 successful revascularisation was present in 14 cases (82%) with a significant ( $p < .001$ ) TS of the Indigo PAT system procedure. At t3 successful revascularisation was present in 16 cases (94%) of combined TS after an adjunctive procedure, not significantly improved compared with t2 ( $p = .99$ ).

### Post-operative and follow up outcomes

The median length of hospital stay was six days (IQR 3, 14 days). Clinical success was seen in 16 patients (94%) at discharge. No cardiovascular adverse events or need for

**Table 2. Number of endovascular aortic repair procedures, rate of iliac limb occlusion (ILO), and different treatments**

Centre number	Total evaluated procedures	Total ILO	ILO treatment n (% treatment/overall ILO)					
			Penumbra Indigo	Surgical bypass	Surgical embolectomy	Other endovascular devices	Thrombolysis	Conservative
1	230	4 (2)	4	0	0	0	0	0
2	135	8 (6)	5	1	0	0	1	1
3	233	10 (4)	2	5	2	0	0	1
4	280	17 (6)	2	2	6	7	0	0
5	132	2 (2)	1	0	1	0	0	0
6	88	2 (2)	1	0	0	0	0	1
7	110	2 (2)	1	0	1	0	0	0
8	138	3 (2)	1	0	0	0	1	1
Overall	1 346	48 (3.5)	17 (35)	8 (17)	10 (21)	7 (15)	2 (4)	4 (8)

Data are presented as n (%).

post-operative dialysis were noted. Re-interventions were unrelated to PAT, including one case of surgical site access infection (discharged home after 30 days) and one case of surgical conversion of femoral percutaneous access for pseudoaneurysm without further sequelae. One female

patient with multiple comorbidities and permanent dialysis was treated urgently at presentation for acute limb ischaemia after EVAR, but the occlusion was impossible to recanalise and represented the single (6%) technical failure. The endovascular procedure needed to be shortened due to respiratory instability of the patient. However, after the procedure she remained without rest pain. After three days she developed respiratory distress due to nosocomial pneumonia and died of respiratory insufficiency after 19 days (30 day mortality rate 6%).

At discharge 12/16 patients (75%) were on dual antiplatelet therapy (from 30–90 days), while three patients with concomitant atrial fibrillation were discharged with single antiplatelet and anticoagulant. One patient was treated with apixaban 2.5 mg twice daily.

All of the first follow up outcomes were considered for 16 patients, excluding the one reported in hospital death. After discharge, patients were observed for clinical and diagnostic follow up at one, six, and 12 months, and none of the 16 patients experienced any complication, with 100% clinical success (Table 6).

The median follow up was 23 months (IQR 11, 41 months), and survival and freedom from ILO recurrence at 18 months were  $91 \pm 8\%$  and  $90 \pm 9\%$ , respectively (Supplementary Fig. S1). No aorta related deaths were registered, and the single death after 15 months was due to myocardial infarction. Two patients (12%) developed a new ILO on the same side as the initial case: the first patient after 18 months was treated with a femorofemoral cross-over bypass; and the second patient after 22 months was treated with femoral artery endarterectomy and patch angioplasty, embolectomy, and relining of the occluded limb.

## DISCUSSION

This study reports, for the first time, the efficacy and safety of the Penumbra Indigo PAT system for ILO after abdominal endovascular repair, with high technical and clinical success both in the early post-operative period and up to one year follow up.

The occurrence of endovascular occlusion of the iliac limb after EVAR revascularisation is a rare but substantial

**Table 3. Baseline characteristics and clinical presentation of the 17 included patients**

Variable	Patients (n = 17)
<i>Pre-operative characteristics</i>	
Median age (IQR) – y	75 (71, 83)
Male sex	14 (82)
Coronary artery disease	5 (29)
Peripheral arterial disease	2 (12)
Chronic obstructive pulmonary disease	6 (35)
Chronic kidney disease	3 (18)
Hypertension	14 (82)
Diabetes mellitus	14 (82)
Smoking	10 (59)
ASA score III–IV	15 (88)
<i>Clinical classification*</i>	
Category I	4 (24)
Category Iia	6 (35)
Category Iib	7 (41)
<i>Clinical presentation</i>	
Buttock claudication	1 (6)
Limb claudication	6 (35)
Rest pain	3 (18)
Sensory loss with motor deficit	7 (41)
<i>Primary endovascular procedure</i>	
EVAR	10 (59)
EVAR + IBD	4 (24)
F/BEVAR	2 (12)
Isolated IBD	1 (6)
<i>Type of primary stent graft implanted</i>	
Cook Alpha	7 (41)
Medtronic Endurant	4 (23)
Endologix AFX	3 (18)
Terumo Anaconda	2 (12)
Terumo Treo	1 (6)

Data are provided as n (%) unless stated otherwise. IQR = interquartile range; ASA = American Society of Anesthesiologists; EVAR = endovascular aortic repair; IBD = iliac branch device; F/BEVAR = fenestrated/branched EVAR.

\* Rutherford classification of acute limb ischaemia.

**Table 4. Procedural details in 17 cases of iliac limb occlusion (ILO)**

Variable	Patients (n = 17)
<i>General procedural details</i>	
General anaesthesia	8 (47)
Percutaneous femoral access	7 (41)
Brachial access	1 (6)
Median procedure time (IQR) – min	130 (70, 170)
Iodinated contrast (IQR) – mL	60 (35–100)
Median decrease in haemoglobin (IQR) – g/dL	2.0 (1.1, 2.6)
Need for blood transfusion	4 (24)
<i>Penumbra Indigo intra-operative details</i>	
CAT8	16 (94)
CATD	1 (6)
Median time of aspiration (IQR) – sec	46 (30, 80)
Use of separator	12 (71)
Median blood loss in canister (IQR) – mL	300 (200, 425)
<i>Adjunctive procedures after thrombo-aspiration</i>	
Relining with iliac limb graft	6 (35)
Relining with bare metal stent	4 (24)
Relining with covered stent	4 (24)
Femoral patch angioplasty	1 (6)
<i>Intra-operative complication</i>	
Peripheral embolisation	1 (6)

Data are provided as n (%) unless stated otherwise.

IQR = interquartile range; CAT8, CATD; names of catheters.

complication.<sup>1,3,4,6</sup> The largest systematic review of a total of 5 454 patients published by Hammond *et al.*<sup>3</sup> reported a non-negligible risk of both death and limb loss of 3% associated with ILO.

In this small series, 48 ILO cases were registered for an incidence of 3.6% (48/1 346). The main reason was attributable to the presence of kinking of the iliac limb graft component. Prevention protocols, adjunctive manoeuvres, and progression in technologies and materials with later generation stent grafts available on the market have contributed to a decreasing ILO occurrence.<sup>3,5,6,16</sup> For ILO, surgical and hybrid procedures, such as graft thrombectomy (with subsequent risk of endovascular module dislodgement), and or endovascular thrombolytic treatment

(absolute and relative bleeding contraindications) with or without adjunctive procedures may be proposed.<sup>3,6,8,17</sup>

In case of an unmanageable endovascular solution, a surgical treatment consisting of extra-anatomical bypass might be a viable repair with higher surgical risks in often fragile patients with the risk of surgical site infection and graft occlusion.<sup>18–20</sup> To date, there is no evidence in the literature regarding the superiority of one treatment over the other.<sup>8</sup>

Recently, a single centre study by Han *et al.*<sup>21</sup> reported the use of AngioJet (Boston Scientific, Marlborough, MA, USA) percutaneous mechanical thrombectomy for ILO after EVAR in 12 patients, with comparable results in terms of number of patients and outcomes.

Penumbra's Indigo system has been available in Europe and the USA since 2005 for the treatment of ischaemic stroke.<sup>11</sup> From 2014, Penumbra started its experience for below knee acute limb ischaemia.<sup>9</sup> Indigo PAT is providing satisfactory evidence with 100% TS for acute renovisceral occlusive events<sup>22</sup>, and in the largest available national registry<sup>10</sup> with satisfactory results of 88.7% primary TS and 95.3% assisted patency for acute lower limb ischaemia.

Unlike the study by de Donato *et al.*<sup>10</sup> where the inclusion criteria were a clot longevity <14 days, this study did not set any time limit and three cases were treated with a time from thrombosis of >14 days, with good final results.

In this series, the average blood loss during the procedure was 300 mL. This result is slightly greater than that reported by Han *et al.*<sup>21</sup> (245 mL), but in both studies the decrease of haemoglobin was similar (2.0 g/dL vs. 1.9 g/dL). Interestingly, Indigo PAT was capable of performing a quicker procedure (46 s vs. 135 s).

In this series, the PAT procedure was shown to be safe, even considering the clinical presentation and technical complexity. Intra-operative complications directly related to the procedure included one case of intra-operative distal embolisation, effectively treated with thrombo-aspiration in the same session. Similar drawbacks are known and described by de Donato *et al.*<sup>10</sup> and Saxon *et al.*<sup>9</sup>, and in the PEARL registry<sup>23</sup> no patient had early recurrence of ILO or need for major amputation after the procedure. The reasons for this complication may be because of the greater volume

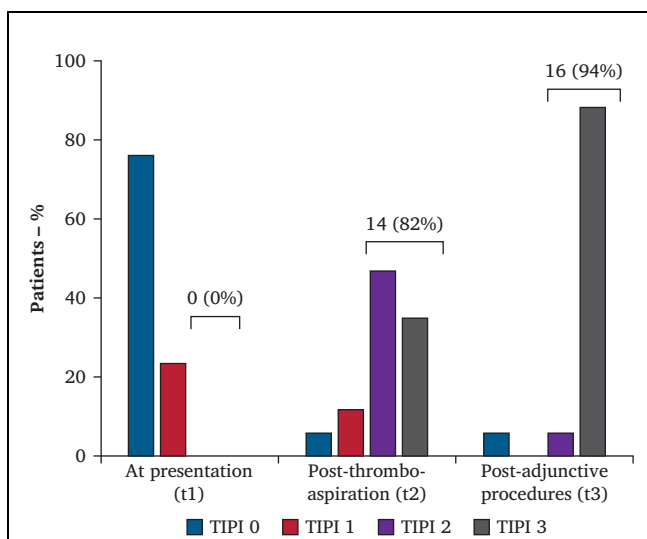
**Table 5. Primary intra-operative outcomes of 17 cases of iliac limb occlusion.**

TIPI score	t1	t2	p value, t1 vs. t2 *	t3	p value, t2 vs. t3 *
0	13 (76)	1 (6)		1 (6)	
1	4 (24)	2 (12)		0	
2	0 (0)	8 (47)		1 (6)	
3	0 (0)	6 (35)		15 (88)	
TIPI 2–3 †	0 (0)	14 (82)	<.001	16 (94)	.99
Overall cases	17 (100)	17 (100)		17 (100)	

Data are provided as n (%). TIPI = Thrombo-aspiration In Peripheral Ischaemia classification.

\* p value based on non-parametric Related-Samples McNemar Change Test.

† TIPI 2–3 = successful classification.



**Figure 2.** Revascularisation outcomes based on Thrombo-aspiration In Peripheral Ischaemia (TIPI) classification<sup>10</sup> assessed angiographically at patient presentation (t1), after Penumbra Indigo percutaneous aspiration thrombectomy (t2), and after adjunctive endovascular or surgical procedures (t3). Successful revascularisation based on TIPI classification was defined as score 2–3 and is 0%, 82%, and 94% at t1, t2, and t3, respectively. t1 vs. t2  $p < .001$ , t2 vs. t3  $p = .99$ ;  $p$  value based on non-parametric Related-Samples McNemar Change Test.

of thrombus in the iliac limbs, not yet having the possibility of a 1:1 ratio between catheter and vessel, and the need for multiple passages inside the thrombus to achieve complete removal. From a technical point of view, surgical access to the femoral artery bifurcation and pre-clamping the arteries is suggested. Other endovascular techniques may be used, such as a filter or larger percutaneous sheaths in order to occlude the external iliac artery and allowing flushing. Future perspectives coming on the market are the next generation Penumbra Indigo Lightning available both in 7 Fr and 12 Fr catheters (still not available during this study’s recruiting period) which may solve the main current drawbacks of blood loss and distal embolisation.

No graft related problem or fabric tears of the previously implanted grafts were detected, and even the use of a separator was not an issue, confirming the safety of the device. The single post-operative death (6%) was not related to the procedure and represented a unique case of technical failure, because the procedure needed to be shortened due to instability of the patient.

This study demonstrates that the procedure with the Penumbra Indigo PAT system is effective in restoring successful revascularisation in up to 82% of cases, and by the use of 15 adjuvant procedures was able to stabilise the recanalisation and resolve the underlying reason for thrombosis, reaching a satisfactory 94% combined TS. The increase in successful revascularisation from t2 and t3 was not significant, pointing to the fact that the thrombo-aspiration procedure played the main role in restoring blood flow. At the same though, the adjunctive procedures

**Table 6.** Primary outcomes at one, six, and 12 months follow up

Variable	1 month	6 months	12 months
Patients at risk	16 (100)	14 (100)	12 (100)
Asymptomatic	16 (100)	14 (100)	12 (100)
Symptomatic	0 (0)	0 (0)	0 (0)
Death	0 (0)	0 (0)	0 (0)
Major limb amputation	0 (0)	0 (0)	0 (0)
Re-intervention	0 (0)	0 (0)	0 (0)
Clinical success	16 (100)	14 (100)	12 (100)

Data are provided as  $n$  (%).

are need to resolve the aetiology of the ILO and stabilise the results over time.

These results are in line with other experiences in the peripheral system: Saxon *et al.*<sup>9</sup> showed a TS after PAT and after adjunctive procedures of 87% and 96%, respectively; similarly, de Donato *et al.*<sup>10</sup> demonstrated a TS after PAT and after adjunctive procedures 88% and 95%, respectively. Different results are reported by Lopez *et al.*<sup>24</sup> with a TS reported in 50% of cases.

Patency and durability during follow up are paramount, and herein 100% clinical success of the procedure during the first year of follow up is reported, with resolution of symptoms, no need for further re-intervention, and no recurrence of thrombosis, similar to the results presented by Han *et al.*<sup>21</sup>. During the median follow up of 23 months, the 18 month freedom from ILO was  $> 90\%$  with no limb loss, while Hammond *et al.*<sup>3</sup> reported 4.5% major limb amputation. These results appear to be reassuring compared with other techniques to resolve ILO even if the follow up outcomes are seldom presented in the literature: extra-anatomic crossover bypass appears to show a range of freedom from occlusion from 40%<sup>18</sup> to  $> 90\%$ <sup>16,20</sup>; endovascular recanalisation of 11 patients presented by Spiliopoulos *et al.*<sup>17</sup> showed an early TS of 90%, a median follow up of 37 months, and a freedom from re-intervention at five years of 83%.

**Limitations**

This study presents some limitations directly related to its retrospective nature and the small numbers of patients. First, this was a single arm design with selection bias in selecting patients considered suitable for the PAT procedure. Furthermore, the procedures were carried out in vascular centres that had already exceeded learning curve with the study device, and the primary endovascular procedures were not always similar and comparable. Use of both endovascular and surgical adjunctive procedures may have influenced the final results of primary and combined TS: given the multicentre, retrospective nature of this study these procedures were carried out at the surgeon’s preference and experience and tailored to specific patient needs. Finally, the cost of devices could be an issue. The company reports a median cost of €2 300 overall together

with main catheter and the use (discretionary) of a separator. In this study, given the small number of patients and the heterogeneity of centres, we were not able to determine any cost effectiveness data, but future and larger studies may focus on this aspect.

### Conclusion

The results of this study demonstrate the application of the Penumbra Indigo PAT system in the treatment of ILO after EVAR and may contribute to prevention of this condition and the role of a total endovascular procedure for its solution, providing high technical and clinical success, absence of damage to previous stent graft, and satisfactory patency during the first year of follow up.

### FUNDING

No funding was received for this study.

### DISCLOSURE

Mauro Gargiulo, Gianluca Faggioli, and Enrico Gallitto are consultants for Cook Medical for fenestrated/branched endovascular aneurysm repair. Gianmarco de Donato received travel grants from Penumbra. All other authors declare that they have no competing interests.

### ACKNOWLEDGEMENTS

Antonio Cappiello (Bologna) and Antonino Di Leo (Bologna).

### APPENDIX A. SUPPLEMENTARY DATA

Supplementary data to this article can be found online at <https://doi.org/10.1016/j.ejvs.2023.04.008>

### REFERENCES

- 1 Faure EM, Becquemin J-P, Cochenne F, ENGAGE Collaborators. Predictive factors for limb occlusions after endovascular aneurysm repair. *J Vasc Surg* 2015;**61**:1138–45.
- 2 Mantas GK, Antonopoulos CN, Sfyroeras GS, Moulakakis KG, Kakisis JD, Mylonas SN, et al. Factors predisposing to endograft limb occlusion after endovascular aortic repair. *Eur J Vasc Endovasc Surg* 2015;**49**:39–44.
- 3 Hammond A, Hansrani V, Lowe C, Asghar I, Antoniou SA, Antoniou GA. Meta-analysis and meta-regression analysis of iliac limb occlusion after endovascular aneurysm repair. *J Vasc Surg* 2018;**68**:1916–24.
- 4 Bogdanovic M, Stackelberg O, Lindström D, Ersryd S, Andersson M, Roos H, et al. Limb graft occlusion following endovascular aneurysm repair for infrarenal abdominal aortic aneurysm with the Zenith Alpha, Excluder, and Endurant devices: a multicentre cohort study. *Eur J Vasc Endovasc Surg* 2021;**62**:532–9.
- 5 Vacirca A, Faggioli G, Pini R, Spath P, Gallitto E, Mascoli C, et al. The efficacy of a protocol of iliac artery and limb treatment during EVAR in minimising early and late iliac occlusion. *Eur J Vasc Endovasc Surg* 2020;**60**:663–70.
- 6 Coelho A, Nogueira C, Lobo M, Gouveia R, Campos J, Augusto R, et al. Impact of post-EVAR graft limb kinking in EVAR limb occlusion: aetiology, early diagnosis, and management. *Eur J Vasc Endovasc Surg* 2019;**58**:681–9.
- 7 Fenelli C, Gargiulo M, Prendes CF, Faggioli G, Stavroulakis K, Gallitto E, et al. Effect of iliac tortuosity on outcomes after iliac branch procedures. *J Vasc Surg* 2022;**76**:714–23.
- 8 Wanhainen A, Verzini F, Van Herzele I, Allaire E, Bown M, Cohnert T, et al. Editor's Choice – European Society for Vascular Surgery (ESVS) 2019 clinical practice guidelines on the management of abdominal aorto-iliac artery aneurysms. *Eur J Vasc Endovasc Surg* 2019;**57**:8–93.
- 9 Saxon RR, Benenati JF, Teigen C, Adams GL, Sewall LE. Utility of a power aspiration-based extraction technique as an initial and secondary approach in the treatment of peripheral arterial thromboembolism: results of the multicenter PRISM trial. *J Vasc Interv Radiol* 2018;**29**:92–100.
- 10 de Donato G, Pasqui E, Sponza M, Intrieri F, Spinazzola A, Silingardi R, et al. Safety and efficacy of vacuum assisted thrombo-aspiration in patients with acute lower limb ischaemia: the INDIAN trial. *Eur J Vasc Endovasc Surg* 2021;**61**:820–8.
- 11 The Penumbra Pivotal Stroke Trial Investigators. The Penumbra Pivotal Stroke Trial: safety and effectiveness of a new generation of mechanical devices for clot removal in intracranial large vessel occlusive disease. *Stroke* 2009;**40**:2761–8.
- 12 Björck M, Earnshaw JJ, Acosta S, Bastos Gonçalves F, Cochenne F, Debus ES, et al. Editor's Choice – European Society for Vascular Surgery (ESVS) 2020 clinical practice guidelines on the management of acute limb ischaemia. *Eur J Vasc Endovasc Surg* 2020;**59**:173–218.
- 13 de Donato G, Pasqui E, Giannace G, Setacci F, Benevento D, Palasciano G, et al. The Indigo system in acute lower-limb malperfusion (INDIAN) registry: protocol. *JMIR Res Protoc* 2019;**8**:e9972.
- 14 Oderich GS, Forbes TL, Chaer R, Davies MG, Lindsay TF, Mastracci T, et al. Reporting standards for endovascular aortic repair of aneurysms involving the renal-mesenteric arteries. *J Vasc Surg* 2021;**73**(1S):4S–52S.
- 15 Conte MS, Bradbury AW, Kolh P, White JV, Dick F, Fitridge R, et al. Global vascular guidelines on the management of chronic limb-threatening ischemia. *Eur J Vasc Endovasc Surg* 2019;**58**(1S):S1–109.
- 16 Maleux G, Koolen M, Heye S, Nevelsteen A. Limb occlusion after endovascular repair of abdominal aortic aneurysms with supported endografts. *J Vasc Interv Radiol* 2008;**19**:1409–12.
- 17 Spiliopoulos S, Moulakakis K, Palialexis K, Konstantos C, Reppas L, Kakisis I, et al. Long-term outcomes of percutaneous stenting of aortic endograft limb occlusion. *Ann Vasc Surg* 2019;**54**:226–32.
- 18 Ronsivalle S, Faresin F, Franz F, Pedon L, Rettore C, Zonta L, et al. A new management for limb graft occlusion after endovascular aneurysm repair adding a vollmar ring stripper: the unclogging technique. *Ann Vasc Surg* 2013;**27**:1216–22.
- 19 Maldonado TS, Rockman CB, Riles E, Douglas D, Adelman MA, Jacobowitz GR, et al. Ischemic complications after endovascular abdominal aortic aneurysm repair. *J Vasc Surg* 2004;**40**:703–9; discussion 709–10.
- 20 Cochenne F, Becquemin JP, Desgranges P, Allaire E, Kobeiter H, Roudot-Thoraval F. Limb graft occlusion following EVAR: clinical pattern, outcomes and predictive factors of occurrence. *Eur J Vasc Endovasc Surg* 2007;**34**:59–65.
- 21 Han X, Liu G, Li T, Guo X. Application of the AngioJet Ultra thrombectomy device for the percutaneous mechanical treatment (PMT) of iliac limb occlusion after endovascular aneurysm repair (EVAR). *Ann Vasc Surg* 2022;**78**:161–9.
- 22 Bisdas T, Stavroulakis K, Beropoulos E, Schwindt A, Stachmann A, Austermann M, et al. Initial experience with the 6-F and 8-F Indigo thrombectomy system for acute renovisceral occlusive events. *J Endovasc Ther* 2017;**24**:604–10.
- 23 Leung DA, Blitz LR, Nelson T, Amin A, Soukas PA, Nanjundappa A, et al. Rheolytic pharmacomechanical thrombectomy for the management of acute limb ischemia: results from the PEARL registry. *J Endovasc Ther* 2015;**22**:546–57.
- 24 Lopez R, Yamashita TS, Neisen M, Fleming M, Colglazier J, Oderich G, et al. Single-center experience with Indigo aspiration thrombectomy for acute lower limb ischemia. *J Vasc Surg* 2020;**72**:226–32.