



Expert-Based Narrative Review on Contemporary Use of an Off-The-Shelf Multibranchend Endograft for Endovascular Treatment of Thoracoabdominal Aortic Aneurysms: Device Design, Anatomical Suitability, Technical Tips, Perioperative Care, Clinical Applications, and Real-World Experience

Yonghui Chen,¹ Mohamad Bashir,² Jiayin Guo,¹ Gabriele Piffaretti,³ Matti Jubouri,² and Mario D'Oria,⁴ Tianjin, China; Cardiff, Wales, UK, and Varese and Trieste, Italy

Advanced endovascular techniques, such as fenestrated stent grafts, are nowadays available that permit minimally invasive treatment of complex abdominal aortic aneurysms. However, thoracoabdominal aortic aneurysm patients have anatomic limitations to fenestrated stent-grafts given a large lumen, that is, the gap between the endograft and the inner aortic wall. This has led to the development of branched endovascular aneurysm repair as the ideal option for such patients. The Zenith t-Branch multibranchend endograft (Cook Medical, Bloomington, IN), which has been commercially available in Europe to treat thoracoabdominal aortic aneurysm since June 2012, represents a feasible off-the-shelf alternative for treatment of such pathologies, especially in the urgent setting, for patients who cannot wait the time required for manufacturing and delivery of custom-made endografts. The device's anatomical suitability should be considered, especially for female patients with smaller iliofemoral vessels. Several tips may help deal with particularly complex scenarios (such as, for instance, in case of narrow inner aortic lumens or when treating patients with failure of prior endovascular aneurysm repair), and a broad array of techniques and devices must be available to ensure technical and clinical success. Despite promising early outcomes, concerns remain particularly regarding the risk for spinal cord ischemia and further assessment of long-term durability is needed, including the rate of target vessel instability and need for secondary interventions. As the published evidence mainly comes from retrospective registries, it is likely that reported outcomes may suffer from an intrinsic bias as most procedures reported to date have been carried out at high-volume aortic

¹Department of Vascular Surgery, Tianjin Medical University General Hospital, Tianjin, China.

²Vascular & Endovascular Surgery, Velindre University NHS Trust, Health & Education Improvement Wales (HEIW), Cardiff, Wales, UK.

³Vascular Surgery Department of Medicine and Surgery, University of Insubria School of Medicine, Varese, Italy.

⁴Department of Vascular and Endovascular Surgery, Cardio-Thoraco-Vascular Department, University Hospital of Trieste ASUGI, Trieste, Italy.

Correspondence to: Mario D'Oria, MD, Division of Vascular and Endovascular Surgery, Department of Medical Surgical and Health Sciences, University of Trieste, Strada di Fiume 447, 34149, Trieste (TS), Italy; E-mail: mario.doria88@outlook.com

Ann Vasc Surg 2024; 108: 98–111

<https://doi.org/10.1016/j.avsg.2024.05.006>

© 2024 The Author(s). Published by Elsevier Inc. This is an open access article under the CC BY license (<http://creativecommons.org/licenses/by/4.0/>).

Manuscript received: November 29, 2023; manuscript accepted: May 15, 2024; published online: 26 June 2024

centers. Nonetheless, with the never-ceasing adoption of new and refined techniques, outcomes are expected to ameliorate.

INTRODUCTION

Endovascular aneurysm repair (EVAR) currently predominates as the primary intervention for patients with suitable anatomy and appropriate risk factors who have abdominal aortic aneurysms (AAAs) given its lower early morbidity and mortality.^{1,2} In patients presenting with complex AAA (e.g., short-necked infrarenal, juxtarenal, and pararenal, etc.), who demonstrate anatomic features that are not in accordance with the instructions-for-use (IFU) of available standard commercial devices (which are usually designed for implantation below the renal arteries), advanced endovascular techniques are nowadays available that permit minimally invasive treatment of such extensive pathologies.

Fenestrated stent-grafts and parallel-graft techniques have increased rapidly in use, with high technical success and low mortality and morbidity at centers of excellence, in contrast to historical open surgical reports.^{3–6} The former, in particular, currently represents the first-line option for management of complex AAA in the elective setting, although they may require a significant amount of time for customization and delivery which may open the door to aortic rupture during the waiting time.^{7,8} Therefore, the availability of endografts that could fit most aortic anomalies may potentially enable endovascular treatment of patients who cannot wait the time required for availability of custom-made devices such as those with large or symptomatic aneurysms, and those presenting with frank or impending rupture. Parallel grafts do not require customization time, but the high-risk type I endoleak limits the use of parallel grafts in management of complex AAA or thoracoabdominal aortic aneurysms (TAAAs). Furthermore, TAAA patients usually have anatomic limitations (such as type II–V TAAA) to fenestrated stent-grafts given the presence of a large gap between the endograft and the inner aortic wall. This has led to the development of branched EVAR (BEVAR) as the technical option of choice for such patients.

In 2009, the first results assessing the eligibility of TAAA patients for the use of standardized off-the-shelf (OTS) multibranch endografts were reported.⁹ The Zenith t-Branch (Cook Medical, Bloomington, IN) has been commercially available in Europe since June 2012 for the treatment of

TAAA. The device employs 4 directional branches to facilitate overlapping between the bridging stent and sealing site, thereby reducing the likelihood of disconnections and type III endoleaks. In this narrative review, we provide an expert-based contemporary overview of the t-Branch multibranch endograft regarding its design and anatomical suitability, technical tips, perioperative care, clinical applications, and real-world experience.

Study Methodology

For this review, the Scale for the Assessment of Narrative Review Articles, a 6-item scale developed for the quality assessment of narrative reviews, was adopted as an optimal presentation of selected studies. Although Scale for the Assessment of Narrative Review Articles is usually implemented during the peer-review process, the authors tried to obtain the maximum score possible (i.e., 12 points) whenever feasible, to improve the study quality.

The literature search was conducted on Scopus, Web of Science, and Medline/Embase from May 3, 2012 to September 1, 2023 as time limits. There were no limitations on study type and format, but the search was restricted to articles fully published in English language as of time of last query. Previous reviews were also consulted to retrieve additional works if missed from the search process. The following keywords were used: “t-branch,” “off-the-shelf,” “multibranch,” “stent-graft,” “endograft,” and “aneurysm.” All titles and abstracts of potentially relevant articles were screened by 2 authors to decide on their inclusion, and data were extracted accordingly to match the review’s main themes as outlined above.

Device Design

The t-Branch design has been described in detail before.^{9–11} In brief, the main stent-graft is designed with a tapered structure that encompasses an exoskeleton of stainless steel Z-stents, wherein the proximal graft diameter measures 34 mm, while the distal graft diameter measures 18 mm, with a length of 202 mm (Fig. 1). The mid-portion of t-branch is designed with 4 short cylindrical branches (i.e., cuffs), each of which serves as the attachment points for an additional covered stent. The proximal end of each branch opens to the inside of the main

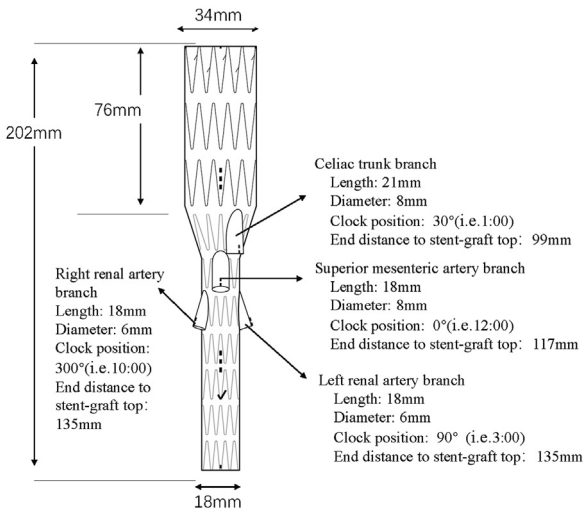


Fig. 1. The design of t-branch device.

stent-graft and the distal end to the outside, so all 4 branches are downward directed, and access is alternative (either from the upper extremity or from steerable sheaths), but it is always necessary to bridge branches. The celiac artery is 21 mm in length away from the surface; the superior mesenteric artery (SMA) and renal branches are slightly shorter, at 18 mm each. The diameter of the branches is 8 mm for celiac artery and SMA, and 6 mm for renal arteries. The branches are positioned at sequential stent levels, where the celiac artery branch is situated 1 stent length above the SMA branch, and the SMA branch is likewise situated 1 stent length above the branches for the renal arteries. The celiac artery and SMA branches are axially located in the 1 and 12 o'clock positions, respectively, so the celiac artery cuff is angled at a 30° inclination to the left of the SMA branch. The right and left renal artery cuffs are in the 10 and 3 o'clock positions, respectively. The right renal artery branch is aligned at a 60° inclination to the right of the SMA branch, and the left renal artery branch is located perpendicularly 90° to the left of the SMA branch.

The Zenith t-Branch is designed to be used in combination with other universal Zenith thoracic endovascular grafts, distal unibody grafts, and iliac leg grafts. At present, the available distal unibody devices include 4 sizes: unibody 22–81 (i.e., 22 mm of proximal diameter, 81 mm of length), unibody 22–98, unibody 22–115, and unibody 22–132. The introduction system of the 4 distal unibody devices is delivered through a 20 Fr (6.7 mm inner diameter, 7.7 mm outer diameter) introducer sheath, while the t-branch needs a 22 Fr (7.3 mm inner diameter, 8.5 mm outer diameter) introducer sheath.

Anatomical Suitability

The design of the t-branch is expected to accurately reflect the position of the target arteries. But in practice, there exist inevitable anatomical variations among diverse patients while the design of the t-branch bears a striking similarity. Especially, the orientation and diameter of each branch may not always match the actual position of the target vessels. The overall feasibility of the t-branch device varied from 39 to 88%^{9,12–15} (Table I).

Sweet et al.⁹ reported a widest anatomic applicability of the t-branch up to 88% in 2009.⁹ Following its approval as a commercial device in 2012, Gasper et al.¹³ identified 201 potential candidates for further evaluation, of which 58% were considered anatomically suitable for t-branch in accordance with the IFU, an additional 29% could have been made suitable with some adjunctive procedure, such as visceral or renal artery stenting, carotid-subclavian bypass, or iliac bypass for device insertion, or to preserve internal iliac artery flow. Gasper et al. also found patients with chronic type B dissections had a lower anatomic applicability. There are 3 primary aspects that contribute to the limitations of a t-branch: the aorta, the visceral artery, and the access artery. As reported by Sweet et al.,⁹ renal artery anatomy proved to be the most limiting factor in the majority of cases (41.2%), including diameter (too wide or too narrow), distance from visceral branches, and orientation out of instrument for use. Multiple renal arteries also been reported.¹³ Two recent studies found similar conclusions that inadequate numbers or diameters of target vessels were the main limitation of t-branch.^{12,15} However, Grandi et al.¹² reported the feasibility of access arteries, target vessels, and the aorta that were estimated to be 82%, 74%, and 65%, respectively.

Interestingly, it was observed that women were less likely to have anatomy suitable or need an adjunct procedure.¹³ And Grandi et al.¹² found only 22% of women could be treated with t-branch by IFU, a smaller access vessel diameter in the women group was the most limiting factor for overall feasibility. The low-profile endografts from Cook (although these can only be requested as custom-made) could overcome the access limitation and expand eligibility for t-branch use.^{13,16,17} The low-profile devices are based on nitinol instead of a stainless steel and have thinner polyester fabric, enabling delivery of all the multibranched components through an 18 Fr delivery system up to 34 mm of proximal diameter. Ramanan et al.¹⁷ found that the combined outcome of conduit use or access artery

Table I. Literature review of anatomic feasibility studies for t-branch device

Studies	Patients, <i>n</i>	Age, years	Male, %	Maximum aneurysm size, mm	TAAAs, %	Dissection, %	Prior aortic operation, %	Accessory renal artery, %	Feasibility, %	Feasibility with additional maneuvers, %	Additional maneuvers, %	Reasons for unsuitability
Sweet 2009 ⁹	66	74 (57–87)	68	–	I: 6 II: 31 III: 14 IV/pararenal: 49	–	33	17	88	–	–	Visceral vessels: 12%
Bisdas 2013 ¹⁴	43	72 (70–73)	77	63 ± 12	I: 2 II: 37 III: 42 IV: 19	9	–	16	49	63	Iliofemoral bypass: 9% TEVAR with(out) left carotid–subclavian bypass: 14%	Visceral vessels: 30% Aorta: 16%
Gasper 2013 ¹³	201	–	74	68 ± 11	I/V: 9 II: 28 III: 20 IV/paravisceral: 43	8	–	–	58	87	Visceral artery stenting: 11% Carotid-subclavian bypass: 2% Iliac bypass: 17%	Visceral vessels: 53% Aorta: 21% Vascular access: 26%
Grandi 2021 ¹²	268	68 (63, 73)	74	–	I: 5 II: 37 III: 24 IV: 34	0	24	21	39	54	Low-profile t-branch: 8% Iliac conduits, infrarenal landing, new-generation covered stents: 7%	Visceral vessels: 26% Aorta: 35% Vascular access: 18%
Mazzaccaro 2022 ¹⁵	45	71 ± 9.5	–	–	II: 28 III: 61 IV: 11	0	0	–	67% for visceral vessels	–	–	Common origin of the SMA/cealic trunk: 11.1% Target artery diameters: 25%

TAAA, thoracoabdominal aortic aneurysm; SMA, superior mesenteric artery.

injury was lower in the low-profile endografts group (18 Fr) than in the standard-profile endografts group (22 Fr–24 Fr). If such devices could be made available OTS, then females would probably become more eligible to treatment with the t-branch.

In addition to the t-branch, there are presently 2 other OTS stent-grafts available: the Gore Excluder Thoracoabdominal Branch Endoprosthesis (TAMBE; W.L. Gore & Associates, Flagstaff, AZ, USA) and the E-nside Multibranch stent-graft system (Artivion, Kennesaw, GA, USA). Bertoglio et al.¹⁸ have compared the theoretical anatomic feasibility of the 3 OTS multibranch devices, reporting that the rate was not significantly different among them (t-Branch, 39%; E-nside, 43%; TAMBE, 33%). In a recent systematic review, the overall feasibility of the t-branch device varied from 39 to 88%, the E-nside from 43 to 75%, and the TAMBE stent-graft from 33 to 94%.¹⁹ While the E-nside device is already available for clinical use on the European market and preliminary experiences have been reported, TAMBE has recently obtained Food and Drug Administration approval.

Technical Tips

Percutaneous femoral access and hostile iliac access.

With lower wound-related complications, shorter operative time, and less blood loss, percutaneous vascular closure devices have gained increasing popularity for AAA and/or TAAA in patients with adequate femoral artery anatomy. Some authors recommended that percutaneous vascular closure devices should be the first-line option for femoral artery access in patients with suitable arterial anatomy.²⁰ In addition to IFU of t-branch which requires an adequate iliac/femoral access, a hostile iliac access such as iliac angle $> 90^\circ$, iliac circumferential calcification $> 50\%$, hemodynamic iliac stenosis or obstruction, or previous aortoiliac/femoral surgical or endovascular graft, also should be paid attention, because hostile iliac access may lead to a more technically demanding procedure, even increased late mortality.²¹ The use of short polyester iliofemoral bypass is reported a feasible option in patients with small iliac vessels.²² However, it should be used electively and implanted 3 to 4 weeks prior to the endovascular procedure to prevent severe surgical bleeding caused by advanced heparinization.²² A low-profile endograft or iliac conduit might be a better choice in case of narrow or calcific access.

Narrow lumens and staged opening. In patients with narrow aortic lumens, Sequential

Catheterization Amid Progressive Endograft Deployment is a useful method for the deployment of the t-branch. This technique uses a gradual, partial unfolding of the endograft to expose each branch individually and sequentially in a tightly controlled manner.²³ Malekpour et al.²⁴ described this technique in deployment of the t-branch, narrow aortic lumen < 25 mm was present in 44% of cases, and the technical success was 100%. Grandi et al.¹² found sealing in the infrarenal aorta (minimum length ≥ 25 mm) with a cuff (minimum required aortic diameter 18 mm) could increase the anatomical applicability in smaller infrarenal aortic diameters. However, the configuration of inner branches configuration may be better suited for narrow aortic lumens.

Transfemoral cannulation of target vessels, selection of bridging stents, and intentional occlusion of branches.

Introducing bridging stents from an upper extremity access seems to be a better approach,¹⁸ due to the design of the t-branch features 4 branches directed downward. However, the steerable sheaths have enabled total transfemoral retrograde BEVAR as an alternative method.^{25,26} The Total Transfemoral Branched Endovascular Thoracoabdominal Aortic Repair study found that using a transfemoral approach for retrograde cannulation of reno-visceral branches is a safe and feasible option with technical success up to 97%, decreasing the risk of stroke owing to reduced manipulation within the aortic arch.²⁷

For the selection of bridging stents, self-expanding stents are characterized by greater flexibility and elasticity, which enables them to remain positioned in tortuous vessels. Additionally, they can be incorporated into various stents with varying diameters and directions, providing versatility. Thus, self-expanding stents were used in cases of target arteries with severe angulation or tortuosity and upward orientation or in cases of long distances between the visceral branch and the target vessel ostium.²⁸ However, self-expanding stents do not provide a strong hoop support as much as balloon-expanded stents and may result in more prominent residual stenosis for hard plaques. Conversely, balloon-expanding stents offer greater radial support, allowing for precise positioning, particularly in vessels with severe calcification. However, balloon-expanding stents may be more susceptible to bending when compressed or flexed. Ultimately, the choice of bridging stents should be carefully individualized, considering a range of factors such as the diameter, angle, and calcification of target vessels. In some cases, it may be necessary for

clinicians to use different bridging stents to optimize the treatment outcome.²⁹

For some special cases with variations in the normal 4-vessel anatomy, permanent dialysis, chronic occlusion, or failure to cannulate a target vessel, intentional occlusion of branches may be required to avoid type III endoleak and continuous perfusion of the aneurysmal sac. Endovascular plugs are an applicable approach to occlude the directional branch. For standard Amplatzer vascular plug, the extension of the branch with balloon or a self-expandable covered stent is recommended prior to the placement of endovascular plugs to ensure an adequate seal.³⁰ Xodo et al.³¹ successfully used a microvascular plug (MVP) to occlude a directional branch vessel. The MVP has the potential to induce immediate and complete occlusion regardless of the patient's hemostatic status. Moreover, the MVP is less expensive than the Amplatzer vascular plug as it does not require additional extension using a bridging stent and larger sheaths.

Cone-beam computed tomography and intravascular ultrasound. Computed tomography angiography (CTA) and digital subtraction angiography (DSA) are 2 of the most popular tools used in radiological assessments. While DSA provides a 2-dimensional view and cannot reliably detect structural problems such as stent compression and intraluminal thrombus. CTA can only be performed postoperatively and requires a secondary procedure if a problem is detected. C-arm cone-beam computed tomography is an advanced imaging capability that uses C-arm flat panel fluoroscopy systems to acquire and display 3-dimensional images. It could be used for preprocedural anatomic assessment and stent-graft sizing, fusion imaging to guide device implantation, and postprocedural assessment of successful aneurysm exclusion.²⁴ And cone-beam computed tomography has been shown in some studies to have higher technical detects than DSA during endovascular procedure, while also reducing the amount of iodine contrast agent and radiation exposure, especially in challenging scenarios or complex EVAR.^{32–34}

Intravascular ultrasound (IVUS) is another method used to locate the origin of target vessels by aligning with bony landmarks, and to select and reposition the branched endograft and main endograft. Comparing with angiography, IVUS could provide real-time, dynamic images, and its 360° axial viewing capability, and reduce the use of contrast media and radiation exposure, minimizing hazards to the patients and the operators. And IVUS could be effectively used with various endografts in diverse target vessels, accurately

identifying intraoperative technical problems such as target vessels instability, and preventing potential complications.^{35,36} During deployment of the t-branch, IVUS guidance could ensure optimal positioning and secured catheterization of the target vessels.²⁴

Perioperative Care

Patient selection and sarcopenia. Given its high demanding and time-consuming nature, t-branch repair may not benefit patients who are elderly and frail, have comorbidities with other serious diseases, and are expected to die from other diseases in the short term. Therefore, adequate assessment and careful selection of patients before making the decision to operate is an important part of the clinical work. Sarcopenia, a health condition characterized by progressive loss of muscle mass and strength, recognized as a significant prognostic factor impacting various conditions, such as survival, complications, and quality of life. CTA, a routine test before aortic aneurysm interventions, can be used to identify sarcopenia. It has been shown that Sarcopenia is common in patients undergoing aortic endovascular procedures and predicts worse outcomes. Despite no optimal method or threshold for determining sarcopenia, it is prudent to consider it a marker of shorter life expectancy and higher risk.³⁷ And based on a comprehensive evaluation of the American Society of Anesthesiologists score, psoas muscle area, and attenuation, those patients with risk of spinal cord ischemia (SCI) after BEVAR may be identified.³⁸ The current tools used by geriatric physicians to assess frailty, such as the Clinical Frailty Scale or Rockwood Frailty Index, have proven to be effective in identifying older individuals at increased risk for adverse perioperative outcomes.

Management of antithrombotic therapy. The management of antithrombotic therapy in BEVAR presents a complex issue due to the extensive aortic coverage and critical involvement of renal and mesenteric vessels, necessitating a careful balance between achieving optimal coagulation cascade inhibition to prevent serious bleeding events. And there are no recommendations from current guidelines. Recently, an international expert-based Delphi consensus creates recommendations on the preoperative, intraoperative, and postoperative management of antithrombotic therapy.³⁹ For preoperative phase, single antiplatelet therapy with aspirin should continue 7 days in all cases before planned fenestrated BEVAR, but single antiplatelet therapy with P2Y12 inhibitors may be discontinued if cerebrospinal fluid drainage (CSFD) is planned or

necessary, and the anticoagulant resumption was proposed 24 hours after removal of CSFD. For patients with complex AAA, usually considered at low risk of postoperative SCI, dual antiplatelet therapy could be performed without discontinuing the P2Y12 inhibitors. But for TAAA patients at high risk of postoperative SCI, elective BEVAR might be postponed up to 3 months until the P2Y12 inhibitors can be discontinued with lower risks. For TAAA patients at high risk of aneurysm rupture or urgent CSFD placement if needed, withdrawing dual antiplatelet therapy 7 days before BEVAR procedure could be performed either withdrawing the P2Y12 inhibitors 7 days before or informing the patient about the potential risks of an urgent CSFD placement, if needed. At the beginning of the procedure, a dose of unfractionated heparin from 70 UI/Kg to 100 UI/Kg is recommended, aiming for an activated clotting time range of 200–250 s.³⁹ For postoperative phase, aspirin should be resumed within 24 hours, while the P2Y12 inhibitor should be resumed 24 hours after removal of CSFD. Aspirin for at least 1–6 months may be considered, but possibly lifelong in patients with small (<6 mm) and highly tortuous vessels or when long or multiple stents.³⁹

Clinical Applications and Real-World Experience

Technical success and urgent/emergent situations. The clinical studies^{22,30,40–53} available of the t-branch stent-graft are summarized in Table II. Most of the studies are from retrospective series of high-volume centers, and the outcomes were largely varied, while there is also a lack of high-quality prospective registries. Based on a total of 1,391 patients using t-branch, mean operation time ranged between 245 min and 471 min with fluoroscopy time ranging between 60.0 min and 156.7 min. It was a well-established fact that the implantation of the t-branch should be a complex and time-consuming process. The technical success was from 64 to 100%, and the 30-day/early mortality ranged between 0 and 27%.^{22,30,40–53}

For urgent/emergent patients who do not fit the time for the manufacturing of a custom-made device, such as symptomatic patients, large aneurysms (>80 mm), and those with ruptures, the availability of an OTS multibranched endograft could broaden the application of TEVAR by eliminating manufacturing delays.¹⁰ The success rate in urgent patients was from 64 to 97.6%,^{43,46,47,50,52,54} and the 30-day mortality ranged from 9 to 27% (Table III).^{43,46,47,50,52,54} Notably, 30-day mortality in

ruptured patients was found to be relatively high, ranging between 19.8% and 26% across various studies.^{43,47,50} It seems reasonable to speculate that unstable patients were less capable of tolerating the time-consuming complex process, but larger studies are needed to confirm these conclusions.

Our latest meta-analysis of outcomes after use of t-branch, which included a total of 1,238 patients from 15 studies,^{22,30,40–49,51–53} revealed a pooled technical success was 97.0% (95% confidence interval [CI] 95.5–98.6, $I^2 = 53.01\%$, 1,185/1,238 cases, 15 studies). Overall, early (30-day) mortality was 7.3% (95% CI 4.4–10.1, $I^2 = 74.48\%$, 124/1,238 cases, 15 studies), early spinal cord ischemia was 13.4% (95% CI 9.6–17.2, $I^2 = 67.24\%$, 160/1,238 cases, 15 studies), and early type I or III endoleak was 6.0% (95% CI 3.4–8.5, $I^2 = 53.71\%$, 68/1,032 cases, 9 studies). Mid-term outcomes showed target vessel occlusion was 4% (95% CI 1.4–6.5, $I^2 = 65.18\%$, 28/528 cases, 10 studies, 5–21.2 months), type I or III endoleak was 4.7% (95% CI 2–7.5, $I^2 = 49.74\%$, 38/512 cases, 10 studies, 5–21.2 months), reintervention was 11.2% (95% CI 8.1–14.3, $I^2 = 31.06\%$, 85/650 cases, 10 studies, 5–21.2 months), and pooled mortality was 13.9% (95% CI 7.2–20.7, $I^2 = 76.32\%$, 84/550 cases, 11 studies, 5–21.2 months).⁵⁵

Previous EVAR or previous open repair. For patients with a failed previous EVAR or previous open aneurysm repair, fenestrated BEVAR has been shown to be a safe and feasible method⁵⁶ and represents an increasingly attractive option. The t-branch, also with acceptable technical success and survival rates,⁴⁴ gradually earned some recognition in this particular scenario. Eleshra et al. evaluated the short-term outcomes of the t-branch in 32 patients previously undergoing infrarenal aortic repair, with 75% of open surgical repair and 25% of standard EVAR. Technical success was 97%, early mortality was 13%, and SCI was 22% with permanent neurologic deficits comprising 12% of the total. The cumulative survival was 82% and 73% at 6 and 12 months, respectively. The cumulative freedom from reintervention was 90% at 6 and 12 months.⁴⁴ Moreover, Rinaldi et al. using a physician-modified t-branch (they removed 2 of the 4 infrarenal stents [~ 34 mm] of the t-branch to create enough room for a distal extension) successfully treated a symptomatic type Ia endoleak with sac expansion to 10.7 cm, and 1-year CTA demonstrated patent visceral and iliac arteries with no evidence of endoleak or stent migration.⁵⁷

Postdissection TAAA and connective tissue disease. There are some other applications of t-branch, such as endograft migration or postdissection

Table II. Literature review of clinical studies available for t-branch device

Studies	Study design	Patients, <i>n</i>	Patients with t-branch	Age, years	Male, %	Crawford classification	Aneurysm diameter, mm	Dissection, %	Urgency, %	Target vessels per patient, <i>n</i>	Operation time, min	Fluoroscopy time, min	Contrast use, mL	Technical success, %
Baba 2017 ⁴⁰	Retrospective, single-center	44	14	74.9 ± 6.8	64	Type I 21.4 Type II 35.7 Type III 14.3 Type V 28.6	60.4 ± 7.8	0	Elective	3.5 ± 0.76	440.4 ± 111.8	156.7 ± 58.7	534.9 ± 162.8	100
Bertoglio 2018 ⁴¹	Retrospective, multicenter	36	18	76 (69–79)	78	Type II 33 Type III 39 Type IV 28	—	—	Elective	—	—	—	—	100
Bisdas 2014 ²²	Retrospective, single-center	46	22	70 ± 8	68	Type II 41 Type III 54 Type IV 5	61 (29–110)	3 (14)	Elective 82 Urgent 18	4	264 ± 37	—	—	100
Bosiers 2021 ⁴²	Prospective, multicenter	80	80	71.0 ± 7.4	70	Type I 6.5 Type II 39 Type III 12.8 Type V 36.4	71.6 ± 18.4	3 (3.8)	Elective 72.7 Urgent 7.8 Rupture 19.5	—	369.3 ± 128.4	81.9 ± 38.9	182.2 ± 70.3	98.8
Eleshra 2022 Elective ⁴³	Retrospective, single-center	100	Elective 30	65 ± 10	73	Type I 10 Type II 17 Type III 10 Type IV 27 Type V 10	62.5 (48–76)	—	Elective 100	3.6 ± 0.4	338 ± 138	81 ± 38	138 ± 40	97
Eleshra 2022 Urgent ⁴³	Retrospective, single-center	—	Urgent 49	72 ± 7	53	Type I 12 Type II 18 Type III 12 Type IV 20 Type V 10	72 (38–114)	—	Urgent 100	3.6 ± 0.4	438 ± 159	86 ± 47	152 ± 84	98
Eleshra 2022 Rupture ⁴³	Retrospective, single-center	—	Rupture 21	75 ± 9	81	Type I 14 Type II 29 Type III 5 Type IV 10 Type V 14	74 (37–134)	—	Rupture 100	3.8 ± 0.4	387 ± 156	69 ± 29	153 ± 91	95
Kölbl 2021 ⁴⁸	Retrospective, multicenter	542	542	70.5 ± 68.5	72	Type I 5.7 Type II 14.6 Type III 21.8 Type IV 43 Type V 5.9J/ PAAA 9.8	75 ± 25	—	Elective 63 Urgent 29 Rupture 8.5	NM	242 ± 127	58 ± 37	226 ± 71	97
Reilly 2012 ³¹	Prospective, single-center	81	81	73.2 ± 7.8	76.5	Type II 23.5 Type III 13.6 Type IV 23.5 Type V 11.1J/ PAAA 28.4	67.1 ± 10.1	4.9	Elective 97.5 Urgent 2.5	3.8	369.9 ± 121.8	130.4 ± 68.5	137.0 ± 81.6	100
Hongku 2018 ⁴⁷	Retrospective, single-center	11	11	65 (61–72)	36	Type I 9 Type II 55 Type III 18 Type IV 18	71 (68–86)	9	Rupture 100	3.5	430 (395–629)	133 (87–157)	—	64
Ulsaker 2022 ³³	Retrospective, single-center	45	28	69 (66–72.8)	61	Type I 11 Type II 29 Type III 29 Type IV 32	65 (61–72)	—	Elective 82.1 Urgent 14.3 Rupture 3.6	3.6	357 (303–493)	—	—	89
Mirza 2020 ⁴⁹	Prospective, multicenter	54	24	72 ± 10	67	Type I–III 87.5 Type IV 12.5	79 ± 16	—	NM	3.7 ± 0.5	273 ± 66	96 ± 35	197 ± 75	100
Ferrer 2022 ⁴⁵	Retrospective, multicenter	48	48	73 ± 8	73	Type I 6 Type II 19 Type III 15 Type IV 31J/ PAAA 29	70 (55–88)	—	Elective 75 Urgent 25	3.7	—	46 ± 10	—	96

(Continued)

Table II. Continued

Studies	Study design	Patients, <i>n</i>	Patients with t-branch	Age, years	Male, %	Crawford classification	Aneurysm diameter, mm	Dissection, %	Urgency, %	Target vessels per patient, <i>n</i>	Operation time, min	Fluoroscopy time, min	Contrast use, mL	Technical success, %
Tenorio 2022 ³⁰	Retrospective, multicenter	100	100	71 (66–75)	65	Type I 8 Type II 28 Type III 29 Type IV 26 Type V 2 J/ PAAA 7	72 (61–85)	14	Elective 69 Urgent 14 Rupture 17	3	300 (194–469)	66 (43–76)	200 (149–251)	92
Eleshra 2020 ⁴⁴	Retrospective, multicenter	32	32	74 ± 7	81	Type I 9 Type II 13 Type III 28 Type IV 31 PAAA 19	66 ± 22	—	Elective 72 Urgent 16 Rupture 13	3.8 ± 0.6	381 ± 145	84.6 ± 30	167 ± 76	97
Silingardi 2018 ⁵²	Retrospective, multicenter	73	73	72 ± 7	74	Type I 7 Type II 38 Type III 33 Type IV 22	67 ± 15	3	Elective 56 Urgent 44 Rupture 16	3.8	Single stage 331 ± 126 Stage 1 317 ± 222 Stage 2 237 ± 77 Stage 3 144 ± 102	Single stage 96 ± 36 Stage 1 24 ± 27 Stage 2 60 ± 46 Stage 3 22 ± 7	Single stage 228 ± 105 Stage 1 204 ± 125 Stage 2 234 ± 155 Stage 3 78 ± 46	92
Gallitto 2022 ⁴⁶	Prospective, single-center	147	65	73 ± 7	71	Type I–III 83 Type IV 17	76 ± 20	—	Elective 56 Urgent 12 Rupture 42	3.7 ± 0.4	471 ± 140	103 ± 64	201 ± 89	86
Nana 2023 ⁵⁰	Retrospective, 2-center	153	153	71 ± 8	100	Type I 13.7 Type II 14.5 Type III 30 Type IV 28.8 Type V 6.5 PAAA 6.5	69.1 ± 7.0	—	Elective 47 Urgent 53	—	245 ± 120	60.0 ± 33.1	226 ± 76	97.4
Hospital stays, days	Spinal cord ischemia, %	Permanent paraplegia, %	Type I or III endoleak, %	Target vessel occlusion, %	30-day mortality, %	Follow-up periods (months)	Type I or III endoleak, %	Target vessel occlusion, %	Surgical conversion, %	Free from reintervention, %	Survival, %			
24.6 ± 7.9	35.7	—	—	0	7.1	15.0 ± 10.4	7.1	7.1	0	92.9 (36 months)	92.9 (36 months)			
—	5.6	4	—	—	5.6	—	—	—	—	—	—			
12 (8–14)	10	5	—	13.6	0	6 ± 3	0	—	0	90 (6 months)	94 (6 months)			
14.6 ± 10.9	8.8	0	14.1	2.9	1.4	12	18.5	11.5	0	88.8 (12 months)	88.4 (12 months)			
12 ± 10	17	0	14	3.3	7	14 ± 16	3.3	—	0	77 (24 months)	87 (24 months)			
22 ± 16	10	0	16	4.1	16	14 ± 16	4.1	—	0	—	—			
19 ± 13	38	0	15	4.8	24	14 ± 16	4.8	—	4.8	—	—			
12.6 ± 10	10.5	4	5.4	1.5	12.3	—	—	—	—	—	—			
14.4 ± 17.1	23.5	3.7	3.7	1.2	3.7	21.2 ± 17.5	12.8	4.9	0	60.5 (21 months)	93.8 (21 months)			
—	30	2	18.2	30	27	15 (7–39)	0	—	0	—	62.5 (24 months)			
10 (7–19)	18	7	—	—	7	7 (4–29)	0	0	0	43 (24 months)	88 (24 months)			
—	17	—	NM	0	0	18 (range, 1–63)	2	2	0	87 (12 month)	—			
5.7 (4–11)	6	0	4	0	10	5 (1–13)	7	0	0	—	87 (24 months)			
9 (6–17)	15	0	—	—	10	5.4 ± 5.9	3.1	3	—	75 (24 months)	63 (24 months)			
15 ± 10	22	13	3.1	0	13	18 (range, 1–43)	—	9	—	90 (12 months)	82 (12 months)			
—	3	0	1	4	4	18 ± 14	—	8.2	—	89 (24 months)	82 (36 months)			
—	17	5	6.1	11	14	—	—	—	—	60 (24 months)	47 (24 months)			
—	13.7	6.4	2	—	16.3	—	—	—	—	62.1 (24 months)	71.2 (24 months)			

J/PAAA, juxta-/para-renal abdominal aortic aneurysms.

Table III. Literature review of clinical studies available for urgent use of t-branch device

Studies	Patients, <i>n</i>	Technical success, %	Spinal cord ischemia, %	Permanent paraplegia, %	Target vessel occlusion, %	Type I or III endoleak, %	Reinterventions, %	30-day mortality, %
Eleshra 2022 ⁴³	70	97.1	18.6	1	4.3	15.7	—	18.6
Hongku 2018 ⁴⁷	11	64	30	2	30	18.2	—	27
Silingardi 2018 ⁵²	32	88	—	0	1	3	6	9
Nana 2023 ⁵⁰	153	97.6	6.2	—	—	2.5	—	19.8
Gallitto	65	86	17	5	—	—	25	20

TAAA. Lorido et al.⁵⁸ reported an urgent case with a type Ia endoleak due to distal migration of a Nellix endograft and a contained rupture of an AAA measuring 90 mm, where the t-branch was implanted successfully with complete exclusion of the AAA and patency of the target vessels. Rossi et al. reported an urgent case with a symptomatic, rapidly growing, postdissection TAAA treated with the t-branch. The procedure was successful in excluding the TAAA without neurological complications and the patency of all target vessels was demonstrated in 6-month imaging.⁵⁹ Konstantinou et al. also presented the challenging endovascular treatment of a symptomatic, 9 cm postdissection TAAA using the t-branch; a good result was also shown in 3-month follow-up CTA with patent target branches, exclusion of the false lumen aneurysm, and no endoleaks.⁶⁰ Use of the t-branch has been reported in patients with connective tissue disease.^{61,62} Particular caution should always be exercised when implanting a stent-graft in the fragile aorta of patients with genetically triggered aortic disease, although experts seem to agree that when the t-branch (or any other endograft) is landed in a prior surgical graft, it may be safe also for patients with connective tissue disease.

Managing complications. Complex EVAR may have higher complication and reintervention compared to standard EVAR.^{63,64} In practice, BEVAR is not just a technical, physiologic, or mental procedure. The potential for additional complications can significantly impact a patient's quality of life, health condition, and overall healthcare expenditure. Complications common to BEVAR treatments include those associated with the endograft, such as endoleaks, and those related to the target vessels, such as target vessel occlusion. Additional complications may include stroke and SCI due to neurological damage, acute kidney injury, and other ischemic complications such as ischemia of the bowel or lower extremities. Some

invasive procedures such as visceral vessel cannulation, wire insertion, and bridging stent placement could potentially result in embolization or entrapment of the target vessels. While perfectly aligned positioning of the main body stent serves as a prerequisite for the smooth introduction of the catheter and branching stents into the target vessel, any deviation from this position may lead to misalignment with the target vessel, potentially resulting in occlusion and potentially catastrophic consequences. To minimize the risk of target vessels instability, the endograft should be placed near the inner wall of the aorta to narrow the distance between it and the target vessels. In addition, attention should be paid to the type of the bridging stent itself.⁶⁴

Renal functional deterioration and target vessel instability. The incidence of renal functional deterioration ranging from 3.3 to 30% of patients was reported.^{40,42,44,46} Possible causes included preoperative renal insufficiency,^{65,66} contrast use, and embolization/infarct during the procedure. The early (<30-day) target vessel occlusion was between 0% and 30%^{22,40,42–49,51,52} with mid-term (>30-day) occlusion ranging between 0% and 11.5%.^{30,40,42,44,45,47,49,51–53} The loss of visceral vessels may be devastating, resulting in ischemic bowel and/or patient mortality. Fortunately, the incidence of visceral vessel occlusion was infrequent. Based on 9 studies,^{22,30,40,42,44,46,47,49,51,52} a total of 6 patients encountered SMA or celiac artery occlusion during the follow-up period (2 of Bosiers et al.,⁴² 1 of Reilly et al.,⁵¹ 2 of Hongku et al.,⁴⁷ and 2 of Eleshra et al.⁴⁴). Some authors found the use of a balloon-expandable endoprosthesis could improve the patency of target vessels.^{29,67}

SCI prevention. In series studies on t-branch, the perioperative SCI was observed in a range between 3% and 38%.^{22,30,40–53} SCI can be transient or may appear later than 3–7 days after BEVAR, but most of them resolve spontaneously and the

permanent paraplegia rate was reported between 0% and 13%.^{22,30,41–48,50–53} The Society for Vascular Surgery guidelines assigned prophylactic CSFD a I B recommendation for SCI protection in TEVAR cases that are deemed high risk (covering extensive length of descending aorta, previous aortic coverage, compromised pelvic perfusion with diseased or occluded common or internal iliac arteries, diseased or occluded vertebral arteries, planned left subclavian artery coverage, or deemed high risk by the operating surgeon).⁶⁸ The main controversy with CSFD is that it is not an entirely safe procedure, and can be associated with a high incidence of drain-related complications.^{69,70} Other measures reported to reduce SCI included preservation of antegrade perfusion of the left subclavian artery and at least 1 hypogastric artery, paraspinal network preconditioning, allowing for perioperative hypertension, systemic hypothermia, use of motor and somatosensory evoked potentials, staging the coverage of large segments of the aorta, minimization of lower limb ischemia reperfusion injury, distal aortic perfusion or Temporary Aneurysm Sac Perfusion, and purposeful spinal artery embolization (also known as the minimally invasive segmental artery coil embolization technique).^{43,71–73} However, the risk cannot be truly eliminated and paraplegia still occurs in about 5–10% of these patients.^{74–76} Notably, emergency repair usually entails high risk, but paraplegia after extensive endovascular aortic repair may develop as late as 3–7 days after the index procedure. Therefore, clinicians must remain cognizant of this devastating complication, especially in high-risk patients; rescue CSFD may be a lifesaving procedure to reverse, or at least attenuate, SCI when it happens.

Learning Curve and Long-Term Follow-Up

The learning curve plays a crucial role in determining the technical success, complications, and mortality associated with complex EVAR.⁷⁷ What is crucial is the necessity for more extensive training to ensure the successful completion of a t-branch procedure. Spanos et al.⁵⁴ found the 30-day mortality in urgent patients decreased from 22% in initial experience to 9% in more recent years, reflecting the importance of the learning curve with the t-branch.

Close follow-up is very important for TAAA patients undergoing BEVAR. Pini et al.⁷⁸ found that early and late visceral vessel loss and kinking of the stents occurred more frequently in BEVAR than in fenestrated EVAR, especially for renal

arteries. Adjunctive visceral procedures correcting target artery kinking, dissection, stenosis, or bleeding showed safe and effective long-term patency. Early revascularization of occluded renal bridging stent grafts can considerably improve renal function, even in cases of extensive renal parenchyma ischemia times exceeding 24 hours or bilateral occlusion, as long as there is residual perfusion of the renal parenchyma.⁷⁸ Iodinated or gadolinium-based contrast agents are contraindicated in individuals with acute kidney injury and estimated Glomerular Filtration Rate (GFR) less than 30 mL/min/1.73 m².^{79,80} If administration of contrast agents is deemed essential, the patient must be counseled on the potential risk of nephrogenic systemic fibrosis and a nephrologist may be consulted for consideration of postexposure hemodialysis.⁸¹ Optimal management of chronic kidney disease includes cardiovascular risk reduction (e.g., statins and blood pressure management), treatment of albuminuria (e.g., angiotensin-converting enzyme inhibitors or angiotensin II receptor blockers), avoidance of potential nephrotoxins (e.g., nonsteroidal anti-inflammatory drugs), and adjustments to drug dosing (e.g., many antibiotics and oral hypoglycemic agents). Those at high risk of chronic kidney disease progression (e.g., estimated GFR <30 mL/min/1.73 m², albuminuria ≥300 mg per 24 hours, or rapid decline in estimated GFR) should be promptly referred to a nephrologist.⁸² Generally, routine review is required at these time points of 1 month, 3 months, 6 months, and 1 year after surgery, and then annually thereafter.

CONCLUSIONS

The t-branch device currently represents a feasible OTS alternative for treatment of a broad range of thoracoabdominal and peri-visceral aortic pathologies (including aneurysms, postdissection aortas and patients with connective tissue disease, or failure from prior infrarenal stent-grafts), especially in the urgent setting for patients who cannot wait the time required for manufacturing and delivery of custom-made endografts. The anatomical suitability of the device should nonetheless be taken into consideration, especially for female patients who have smaller iliofemoral vessels. Despite promising technical success rates, concerns remain regarding the risk for SCI and further assessment of long-term durability is needed. As the published evidence mainly comes from retrospective registries, it is likely that reported outcomes may suffer from an intrinsic bias as most procedures reported to date

have been carried out at high-volume aortic centers. Nonetheless, with the never-ceasing adoption of new and refined techniques, outcomes are expected to ameliorate, as we move the bar toward a need for excellence in care of patients suffering from complex aortic pathologies.

CREDIT AUTHORSHIP CONTRIBUTION STATEMENT

Yonghui Chen: Writing – original draft, Investigation, Formal analysis, Data curation. **Mohamad Bashir:** Writing – review & editing. **Jiayin Guo:** Writing – original draft. **Gabriele Piffaretti:** Writing – review & editing. **Matti Jubouri:** Writing – review & editing. **Mario D’Oria:** Writing – review & editing, Conceptualization.

REFERENCES

- De Bruin JL, Baas AF, Buth J, et al. Long-term outcome of open or endovascular repair of abdominal aortic aneurysm. *N Engl J Med* 2010;362:1881–9.
- Lederle FA, Freischlag JA, Kyriakides TC, et al. Outcomes following endovascular vs open repair of abdominal aortic aneurysm: a randomized trial. *JAMA* 2009;302:1535–42.
- Simons JP, Crawford AS, Flanagan CP, et al. Evolution of fenestrated/branched endovascular aortic aneurysm repair complexity and outcomes at an organized center for the treatment of complex aortic disease. *J Vasc Surg* 2021;73:1148–1155.e2.
- Oderich GS, Farber MA, Schneider D, et al. Final 5-year results of the United States Zenith Fenestrated prospective multicenter study for juxtarenal abdominal aortic aneurysms. *J Vasc Surg* 2021;73:1128–1138.e2.
- Lee JT, Lee GK, Chandra V, et al. Comparison of fenestrated endografts and the snorkel/chimney technique. *J Vasc Surg* 2014;60:849–56.
- Donas KP, Lee JT, Lachat M, et al. Collected world experience about the performance of the snorkel/chimney endovascular technique in the treatment of complex aortic pathologies: the PERICLES registry. *Ann Surg* 2015;262:546–53.
- Cirillo-Penn NC, Mendes BC, Tenorio ER, et al. Incidence and risk factors for interval aortic events during staged fenestrated-branching endovascular aortic repair. *J Vasc Surg* 2023;78:874–82.
- D’Oria M, Wanhainen A, Mani K, et al. Frequency and type of interval adverse events during the waiting period to complex aortic endovascular repair. *J Vasc Surg* 2022;75:1821–1828.e1.
- Sweet MP, Hiramoto JS, Park KH, et al. A standardized multi-branched thoracoabdominal stent-graft for endovascular aneurysm repair. *J Endovasc Ther* 2009;16:359–64.
- Chuter TA, Hiramoto JS, Park KH, et al. The transition from custom-made to standardized multibranched thoracoabdominal aortic stent grafts. *J Vasc Surg* 2011;54:660–7.
- Park KH, Hiramoto JS, Reilly LM, et al. Variation in the shape and length of the branches of a thoracoabdominal aortic stent graft: implications for the role of standard off-the-shelf components. *J Vasc Surg* 2010;51:572–6.
- Grandi A, Carta N, Cambiaghi T, et al. Sex-related anatomical feasibility differences in endovascular repair of thoracoabdominal aortic aneurysms with a multibranched stent-graft. *J Endovasc Ther* 2021;28:283–94.
- Gasper WJ, Reilly LM, Rapp JH, et al. Assessing the anatomical applicability of the multibranched endovascular repair of thoracoabdominal aortic aneurysm technique. *J Vasc Surg* 2013;57:1553–8.
- Bisdas T, Donas KP, Bosiers M, et al. Anatomical suitability of the T-branch stent-graft in patients with thoracoabdominal aortic aneurysms treated using custom-made multibranched endografts. *J Endovasc Ther* 2013;20:672–7.
- Mazzaccaro D, Avishay D, Nano G. Factors affecting the visceral suitability of a multibranched off-the-shelf endograft for the treatment of thoraco-abdominal aortic aneurysms. *Ann Vasc Surg* 2022;81:113–20.
- Edman NI, Bartek MA, Kang PC, et al. Anatomic eligibility for commercial branched endograft repair of thoracoabdominal aortic aneurysms. *Ann Vasc Surg* 2021;70:481–90.
- Ramanan B, Fernandez CC, Sobel JD, et al. Low-profile versus standard-profile multibranched thoracoabdominal aortic stent grafts. *J Vasc Surg* 2016;64:39–45.
- Bertoglio L, Grandi A, Carta N, et al. Comparison of anatomic feasibility of three different multibranched off-the-shelf stent-grafts designed for thoracoabdominal aortic aneurysms. *J Vasc Surg* 2021;74:1472–1482.e4.
- Bilman V, Rinaldi E, Loschi D, et al. Suitability of current off-the-shelf devices for endovascular TAAA repair: a systematic review. *J Cardiovasc Surg* 2023;64:459–69.
- D’Oria M, Oderich GS, Tenorio ER, et al. Safety and efficacy of totally percutaneous femoral access for fenestrated-branching endovascular aortic repair of pararenal-thoracoabdominal aortic aneurysms. *Cardiovasc Intervent Radiol* 2020;43:547–55.
- Gallitto E, Gargiulo M, Faggioli G, et al. Impact of iliac artery anatomy on the outcome of fenestrated and branching endovascular aortic repair. *J Vasc Surg* 2017;66:1659–67.
- Bisdas T, Donas KP, Bosiers M, et al. Custom-made versus off-the-shelf multibranched endografts for endovascular repair of thoracoabdominal aortic aneurysms. *J Vasc Surg* 2014;59:19S. <https://doi.org/10.1016/j.jvs.2014.03.048>.
- Timaran CH, Stanley GA, Baig MS, et al. The sequential catheterization amid progressive endograft deployment technique for fenestrated endovascular aortic aneurysm repair. *J Vasc Surg* 2017;66:311–5.
- Malekpour F, Scott CK, Kirkwood ML, et al. Sequential catheterization and progressive deployment of the Zenith t-Branch device for branching endovascular aortic aneurysm repair. *Cardiovasc Intervent Radiol* 2021;44:156–60.
- Grandi A, D’Oria M, Melloni A, et al. A scoping review on the approaches for cannulation of reno-visceral target vessels during complex endovascular aortic repair. *Eur J Cardio Thorac Surg* 2022;62:ezac478.
- Makaloski V, Tsilimparis N, Rohlfes F, et al. Use of a steerable sheath for retrograde access to antegrade branches in branching stent-graft repair of complex aortic aneurysms. *J Endovasc Ther* 2018;25:566–70.
- Mario D, Alessandro G, Giovanni P, et al. Total transfemoral branching endovascular thoracoabdominal aortic repair (TORCH2): short-term and 1-year outcomes from a national multicenter registry. *J Endovasc Ther* 2023;15266028231179864.

28. Gallitto E, Gargiulo M, Freyrie A, et al. Off-the-shelf multi-branched endograft for urgent endovascular repair of thoracoabdominal aortic aneurysms. *J Vasc Surg* 2017;66:696–704.e5.
29. Gallitto E, Faggioli G, Fenelli C, et al. The combined use of a distal self-expandable and proximal balloon-expandable stent graft in bridging hostile renal arteries in thoracoabdominal branched endografting. *Ann Vasc Surg* 2020;68:326–37.
30. Tenorio ER, Oderich GS, Kölbel T, et al. Outcomes of off-the-shelf multibranched stent grafts with intentional occlusion of directional branches using endovascular plugs during endovascular repair of complex aortic aneurysms. *J Vasc Surg* 2022;75:1142–1150.e4.
31. Xodo A, Tagliavero J, Lepidi S, et al. Novel technique for intentional occlusion of directional branches during complex endovascular aortic repair using microvascular plugs. *Vasc Endovascular Surg* 2023;58:110–4.
32. Dijkstra ML, Eagleton MJ, Greenberg RK, et al. Intraoperative C-arm cone-beam computed tomography in fenestrated/branched aortic endografting. *J Vasc Surg* 2011;53:583–90.
33. Tenorio ER, Oderich GS, Sandri GA, et al. Prospective non-randomized study to evaluate cone beam computed tomography for technical assessment of standard and complex endovascular aortic repair. *J Vasc Surg* 2020;71:1982–1993.e5.
34. Mezzetto L, Mastroianni D, Abatucci G, et al. Impact of cone beam computed tomography in advanced endovascular aortic aneurysm repair using last generation 3D C-arm. *Ann Vasc Surg* 2022;78:132–40.
35. Gennai S, Leone N, Saitta G, et al. Intravascular ultrasound in branched and fenestrated endovascular aneurysm repair: initial experience in a single-center cohort study. *J Endovasc Ther* 2021;28:828–36.
36. Ascitutto G, Ibrahim A, Leone N, et al. Intravascular ultrasound in the detection of bridging stent graft instability during fenestrated and branched endovascular aneurysm repair procedures: a multicentre study on 274 target vessels. *Eur J Vasc Endovasc Surg* 2023;67:99–104.
37. Mezzetto L, D’Oria M, Mani K, et al. Scoping review of radiologic assessment and prognostic impact of skeletal muscle sarcopenia in patients undergoing endovascular repair for aortic disease. *J Vasc Surg* 2022;76:1407–16.
38. Kölbel T, Nana P, Torrealba JI, et al. The association of sarcopenia and ASA score to spinal cord ischemia in patients treated with the t-branch device. *J Endovasc Ther* 2023;15266028231179414.
39. D’Oria M, Bertoglio L, Bignamini AA, et al. Editor’s Choice - PRINciples of optimal antithrombotic therapy and coagulation managEment during elective fenestrated and branched EndovaScular aortic repairS (PRINCE(2)SS): an International Expert Based Delphi Consensus Study. *Eur J Vasc Endovasc Surg* 2022;63:838–50.
40. Baba T, Ohki T, Kanaoka Y, et al. Clinical outcomes of spinal cord ischemia after fenestrated and branched endovascular stent grafting during total endovascular aortic repair for thoracoabdominal aortic aneurysms. *Ann Vasc Surg* 2017;44:146–57.
41. Bertoglio L, Cambiagli T, Ferrer C, et al. Comparison of sacrificed healthy aorta during thoracoabdominal aortic aneurysm repair using off-the-shelf endovascular branched devices and open surgery. *J Vasc Surg* 2018;67:695–702.
42. Bosiers M, Kölbel T, Resch T, et al. Early and midterm results from a postmarket observational study of Zenith t-Branch thoracoabdominal endovascular graft. *J Vasc Surg* 2021;74:1081–1089.e3.
43. Eleshra A, Hatm M, Spanos K, et al. Early outcomes of t-Branch off-the-shelf multibranched stent graft in urgent and emergent repair of thoracoabdominal aortic aneurysms. *J Vasc Surg* 2022;75:416–424.e2.
44. Eleshra A, Oderich GS, Spanos K, et al. Short-term outcomes of the t-Branch off-the-shelf multibranched stent graft for reintervention after previous infrarenal aortic repair. *J Vasc Surg* 2020;72:1558–66.
45. Ferrer C, Orrico M, Spataro C, et al. Outcomes of multi-branched off-the-shelf stent graft in elective and urgent/emergent repair of complex aortic aneurysms with narrow internal aortic lumen. *J Vasc Surg* 2022;76:326–34.
46. Gallitto E, Faggioli G, Spath P, et al. Urgent endovascular repair of thoracoabdominal aneurysms using an off-the-shelf multibranched endograft. *Eur J Cardio Thorac Surg* 2022;61:1087–96.
47. Hongku K, Sonesson B, Björse K, et al. Mid-term outcomes of endovascular repair of ruptured thoraco-abdominal aortic aneurysms with off the shelf branched stent grafts. *Eur J Vasc Endovasc Surg* 2018;55:377–84.
48. Kölbel T, Spanos K, Jama K, et al. Early outcomes of the t-Branch off-the-shelf multi-branched stent graft in 542 patients for elective and urgent aortic pathologies: a retrospective observational study. *J Vasc Surg* 2021;74:1817–24.
49. Mirza AK, Tenorio ER, Kärkkäinen JM, et al. Outcomes of a novel upper extremity preloaded delivery system for fenestrated-branched endovascular repair of thoracoabdominal aneurysms. *J Vasc Surg* 2020;72:470–9.
50. Nana P, Spanos K, Kölbel T, et al. Early and mid-term outcomes of females treated with t-branch off the shelf device. *Ann Vasc Surg* 2023;95:32–41.
51. Reilly LM, Rapp JH, Grenon SM, et al. Efficacy and durability of endovascular thoracoabdominal aortic aneurysm repair using the caudally directed cuff technique. *J Vasc Surg* 2012;56:53–63.
52. Silingardi R, Gennai S, Leone N, et al. Standard “off-the-shelf” multibranched thoracoabdominal endograft in urgent and elective patients with single and staged procedures in a multicenter experience. *J Vasc Surg* 2018;67:1005–16.
53. Ulsaker H, Seternes A, Brekken R, et al. Midterm outcomes for endovascular repair of thoraco-abdominal aortic aneurysms. *EJVES Vasc Forum* 2022;56:6–10.
54. Spanos K, Kölbel T, Theodorakopoulou M, et al. Early outcomes of the t-branch off-the-shelf multibranched stent-graft in urgent thoracoabdominal aortic aneurysm repair. *J Endovasc Ther* 2018;25:31–9.
55. Chen Y, Liu Z, Wang S, et al. Systematic review and meta-analysis of short-term and mid-term outcomes after use of t-branch off-the-shelf multibranched endograft for elective and urgent treatment of thoracoabdominal aortic aneurysms. *J Endovasc Ther* 2023;15266028231220322. <https://doi.org/10.1177/15266028231220322>.
56. Budtz-Lilly J, D’Oria M, Gallitto E, et al. European multicentric experience with fenestrated-branched ENDOvascular stent grafting after previous FAILed infrarenal aortic repair: the EU-FBENDO-FAIL registry. *Ann Surg* 2023;278:e389–95.
57. Rinaldi E, Cambiagli T, Ferreira M. Use of a physician-modified off-the-shelf T-branch device to treat a symptomatic type Ia endoleak. *J Vasc Interv Radiol* 2019;30:126–9.
58. Lorigo A, Orrico M, Marino M, et al. Late failure of a nellix endoprosthesis treated with the t-Branch off-the-shelf multibranched stent graft. *J Vasc Surg Cases Innov Tech* 2019;5:576–9.

59. Rossi G, Perini P, Tecchio T, et al. Floating stent-graft as a support to bridge an unfavorable renal artery during postdissection TAAA repair using a multibranched thoracoabdominal endograft. *J Endovasc Ther* 2020;27:922–8.
60. Konstantinou N, Banafsche R, Mehmedovic A, et al. Balloon-assisted true lumen expansion and fenestration of a symptomatic, triple-Barrel, postdissection thoracoabdominal aneurysm with collapsed true lumen to facilitate endovascular treatment with a t-branch. *Ann Vasc Surg* 2021;74:521.e515–21.
61. Eleshra A, Panuccio G, Spanos K, et al. Endovascular repair of postdissection thoracoabdominal aortic aneurysm in patients with vascular ehlers-danlos syndrome. *J Endovasc Ther* 2021;28:804–11.
62. Hung CC, Lee KC, Wei J, et al. False lumen off-the-shelf t-branch in a marfan patient with recurrent aortic dissections. *Acta Cardiol Sin* 2023;39:189–93.
63. Glebova NO, Selvarajah S, Orion KC, et al. Fenestrated endovascular repair of abdominal aortic aneurysms is associated with increased morbidity but comparable mortality with infrarenal endovascular aneurysm repair. *J Vasc Surg* 2015;61:604–10.
64. Xodo A, D’Oria M, Mendes B, et al. Peri-operative management of patients undergoing fenestrated-branched endovascular repair for juxtarenal, pararenal and thoracoabdominal aortic aneurysms: preventing, recognizing and treating complications to improve clinical outcomes. *J Pers Med* 2022;12:1018.
65. Cajas-Monson L, D’Oria M, Tenorio E, et al. Effect of renal function on patient survival after endovascular thoracoabdominal and pararenal aortic aneurysm repair. *J Vasc Surg* 2021;74:13–9.
66. D’Oria M, Wanhainen A, Lindström D, et al. Editor’s choice - pre-operative moderate to severe chronic kidney disease is associated with worse short-term and mid-term outcomes in patients undergoing fenestrated-branched endovascular aortic repair. *Eur J Vasc Endovasc Surg* 2021;62:859–68.
67. Gallitto E, Faggioli G, Pini R, et al. First/preliminary experience of Gore Viabahn balloon-expandable endoprosthesis as bridging stent in fenestrated and branched endovascular aortic repair. *Ann Vasc Surg* 2019;61:299–309.
68. Upchurch GR Jr, Escobar GA, Azizzadeh A, et al. Society for Vascular Surgery clinical practice guidelines of thoracic endovascular aortic repair for descending thoracic aortic aneurysms. *J Vasc Surg* 2021;73:55s–83s.
69. Dias NV, Sonesson B, Kristmundsson T, et al. Short-term outcome of spinal cord ischemia after endovascular repair of thoracoabdominal aortic aneurysms. *Eur J Vasc Endovasc Surg* 2015;49:403–9.
70. Jónsson GG, Mani K, Mosavi F, et al. Spinal drain-related complications after complex endovascular aortic repair using a prophylactic automated volume-directed drainage protocol. *J Vasc Surg* 2023;78:575–583.e2.
71. Katsargyris A. Is it really time to eliminate prophylactic cerebrospinal fluid drainage in TAAA endovascular repair? *Eur J Vasc Endovasc Surg* 2019;57:649.
72. Etz CD, Debus ES, Mohr FW, et al. First-in-man endovascular preconditioning of the paraspinal collateral network by segmental artery coil embolization to prevent ischemic spinal cord injury. *J Thorac Cardiovasc Surg* 2015;149:1074–9.
73. Scali ST, Kim M, Kubilis P, et al. Implementation of a bundled protocol significantly reduces risk of spinal cord ischemia after branched or fenestrated endovascular aortic repair. *J Vasc Surg* 2018;67:409–423.e4.
74. Rossi SH, Patel A, Saha P, et al. Neuroprotective strategies can prevent permanent paraplegia in the majority of patients who develop spinal cord ischaemia after endovascular repair of thoracoabdominal aortic aneurysms. *Eur J Vasc Endovasc Surg* 2015;50:599–607.
75. Sobel JD, Vartanian SM, Gasper WJ, et al. Lower extremity weakness after endovascular aneurysm repair with multibranched thoracoabdominal stent grafts. *J Vasc Surg* 2015;61:623–8.
76. Bisdas T, Panuccio G, Sugimoto M, et al. Risk factors for spinal cord ischemia after endovascular repair of thoracoabdominal aortic aneurysms. *J Vasc Surg* 2015;61:1408–16.
77. Mirza AK, Tenorio ER, Karkkainen JM, et al. Learning curve of fenestrated and branched endovascular aortic repair for pararenal and thoracoabdominal aneurysms. *J Vasc Surg* 2020;72:423–434.e1.
78. Pini R, Faggioli G, Gallitto E, et al. The different effect of branches and fenestrations on early and long-term visceral vessel patency in complex aortic endovascular repair. *J Vasc Surg* 2020;71:1128–34.
79. Bahrainwala JZ, Leonberg-Yoo AK, Rudnick MR. Use of radiocontrast agents in CKD and ESRD. *Semin Dial* 2017;30:290–304.
80. Davenport MS, Perazella MA, Yee J, et al. Use of intravenous iodinated contrast media in patients with kidney disease: consensus statements from the American college of radiology and the national kidney foundation. *Radiology* 2020;294:660–8.
81. Stevens PE, Levin A. Evaluation and management of chronic kidney disease: synopsis of the kidney disease: improving global outcomes 2012 clinical practice guideline. *Ann Intern Med* 2013;158:825–30.
82. Chen TK, Knicely DH, Grams ME. Chronic kidney disease diagnosis and management: a review. *JAMA* 2019;322:1294–304.