

CASE REPORT

A primary intraosseous squamous cell carcinoma case report and literature review. The new WHO classification

Michele Maglione  | Rossana Bussani  | Nicolò Camurri Piloni | Lorenzo Bevilacqua 

Department of Medical, Surgical and Health Sciences, University of Trieste, Trieste, Italy

Correspondence

Lorenzo Bevilacqua, Department of Surgical, Medical and Health Sciences, University of Trieste, Piazza dell'Ospitale 1, 34125 Trieste, Italy.
Email: l.bevilacqua@fmc.units.it

Funding information

This research did not receive any specific grant from funding agencies in the public, commercial or not-for-profit sectors.

Abstract

Aim: Cyst-like lesions in the mandible rarely develop into malignancies, and the reported incidence is between 0.3% and 2%. The present study describes a rare case of primary intraosseous squamous cell carcinoma of the mandible arising from an odontogenic cyst.

Materials and Methods: An 80-year-old male was referred to Trieste University Maggiore Hospital (Trieste, Italy), with acute pain in the left retromolar area.

An initial examination revealed extra oral swelling without paresthesia of the IAN. Following an intraoral examination, the oral mucosa was edematous, percussion pain was experienced on the lower left second molar. Panoramic radiography revealed a retained lower left wisdom tooth and an irregular radiolucent area between the lower left second molar and the mandibular angle with clear margins. Computed tomography revealed diffuse bone resorption and an extensive loss of cortical bone on the lingual side.

Results: A biopsy was performed during the surgery to remove the second lower left molar and the wisdom tooth, the pathological diagnosis was of squamous cell carcinoma arising from the epithelial lining of the odontogenic cyst. MRI with contrast agent was also performed. Shortly after the patient has been proposed a complete resective surgery of the mass including the infiltrated areas and then a reconstructive part to restore the function and aesthetic.

Conclusion: The follow-up of a large inflammatory cyst is essential for early diagnosis of malignant neoplasm. This approach allows lower invasive treatments and major survival of these patients.

KEYWORDS

clinicopathological feature, malignant neoplasm, odontogenic cyst, primary intraosseous squamous cell carcinoma, wisdom tooth

1 | INTRODUCTION

Primary intraosseous squamous cell carcinoma (PIOSCC) is a rare carcinoma arising, without any connection to the oral mucosa, from the odontogenic epithelium; the aetiology is

associated with the malignant degeneration of embryological remains, such as Malassez's epithelial rest. The factors responsible for the malignant transformation of the cystic lining remains unclear; the most common factor should be chronic inflammation and predisposing genetic cofactors. In

This is an open access article under the terms of the [Creative Commons Attribution-NonCommercial-NoDerivs](https://creativecommons.org/licenses/by-nc-nd/4.0/) License, which permits use and distribution in any medium, provided the original work is properly cited, the use is non-commercial and no modifications or adaptations are made.

© 2022 The Authors. *Oral Surgery* published by British Association of Oral Surgeons and John Wiley & Sons Ltd.

2017, the WHO defined PIOSCC as a central jaw carcinoma that cannot be categorized as any other type of carcinoma. It is assumed to arise from odontogenic epithelium. Some cases arise in odontogenic cysts or other benign precursors.¹

Primary intraosseous carcinoma (PIOC) is rare. The incidence is low and approximately 200 cases are reported in the literature.²⁻⁵

The aetiology seems to be related to the malignant degeneration of embryological remains. In this line, epithelial rests of Malassez, dental lamina and epithelium of the dental follicle represent potential suspects.⁶ It was also observed that long-standing chronic inflammation in the benign odontogenic cyst was the most probable etiopathological factor responsible for the malignant transformation of a benign cystic lining.⁷⁻⁹

PIOC arising in a dentigerous cyst is a rare observation. PIOC from odontogenic cysts have an incident rate of 0.3%–2% and only 16%–51% of them are PIOC from dentigerous cyst.^{10,11}

As described in a recent review¹⁰ PIOC shows a male predilection (69.3%) and is more frequent in the posterior body and ramus of the mandible than in the maxilla (7:1). Maxillary lesions are usually in the anterior segment. Determining origin is important for diagnosis. Carcinoma arising in the oral mucosa and infiltrating the mandible, an antral primary and metastatic carcinoma must be excluded, and ulceration to the oral cavity is normally considered to preclude the definitive diagnosis. PIOC in the mandible usually arises above the inferior dental canal, whereas metastases usually have their epicentre below it. Cases arising in cysts are more common in the mandible.

Waldron and Mustoe proposed a different classification that has been widely accepted; however, certain more recently described types of odontogenic epithelial malignancies are not included. It is often difficult to definitively diagnose PIOSCC as the lesions need to be distinguished from alveolar carcinoma that could invade the bone from the overlying soft tissues or from tumours that have metastasized to the jaw from a distant site and primary tumours of maxillary sinus origin. PIOC occurs between 1.3 and 90 years, with a mean age of 60.2 years; the incidence is much higher in males than females. Approximately only 200 cases have been reported to date. The most frequent area is the molar-ramus region of the mandible and the most common clinical symptoms are swelling, pain/toothache and lesion growth; these symptoms are usually followed by trismus and hypoesthesia of the mandibular nerve. Although the diagnostic criteria of PIOSCC remain still unclear, the following criteria have been suggested:

- The tumour must be a histopathologically-based squamous cell carcinoma without the involvement of any other odontogenic cysts or metastatic tumour cells.
- It must exhibit intact mucosa.
- No other distant primary tumour must be present at the time of diagnosis, with at least a 6-month absence of malignancy during the follow-up period.

In the current study, a case of PIOC arising from an odontogenic cyst is presented and the issues concerning the

differential diagnosis and management are discussed. The patient provided written informed consent.

2 | CASE REPORT

An 80-year-old male patient was referred to Trieste University, Maggiore Hospital (Trieste, Italy) with acute pain in the left retromolar area; there was no history of tobacco use, however, the patients' medical history was significant for diabetes, hypertension and chronic kidney failure. He arrived at the hospital, sent by his private dentist, due to acute pain in the retromolar area. At the time of the visit, a previous parotid tumour of Warthin was reported in the patient's medical record.

Physical examination revealed first a left extraoral swelling without signs of paresthesia in the III branch of the ipsilateral V Cranial Nerve. Exploration of the oral cavity revealed edematous oral mucosa in the left retromolar region associated with pain evoked by percussion of element 3.7. The two-dimensional radiographic examination has the presence of impacted third molar associated with a radiolucency formation located between elements 3.7 and 3.8 characterized by predominantly defined margins (Figure 1).

A radiological investigation was subsequently requested three-dimensional by means of volumetric CT from which it was possible to appreciate associated diffuse bone resorption to a considerable loss of both lingual and vestibular cortical walls (Figure 1). Subsequently, the extraction of elements 3.7 and 3.8 was planned and performed and at the same time a biopsy of the lesion was performed (Figure 2). The histological report revealed squamous cell carcinoma primary intraosseous developed from the lining epithelium of an odontogenic cyst (Figures 3 and 4). MRI with contrast medium was performed 2 weeks after surgery which revealed a primitive neoformation localized in the proximal third of the left mandibular branch, lytic expansive, infiltrating the distal end of the masseter muscle, the medial pterygoid muscle and marginally also the distal mandibular insertion of the ipsilateral mylohyoid muscle (Figure 5). There were also multiple lymph node swellings at levels I–II (a–b). The patient underwent segmental mandibulectomy associated with complete latero-cervical emptying followed by plastic

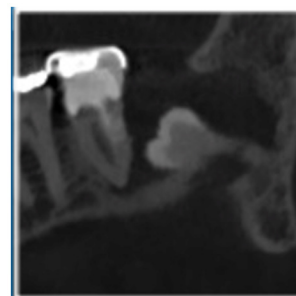


FIGURE 1 Element 3.7 with bone resorption. Considerable loss of both lingual and vestibular cortical walls

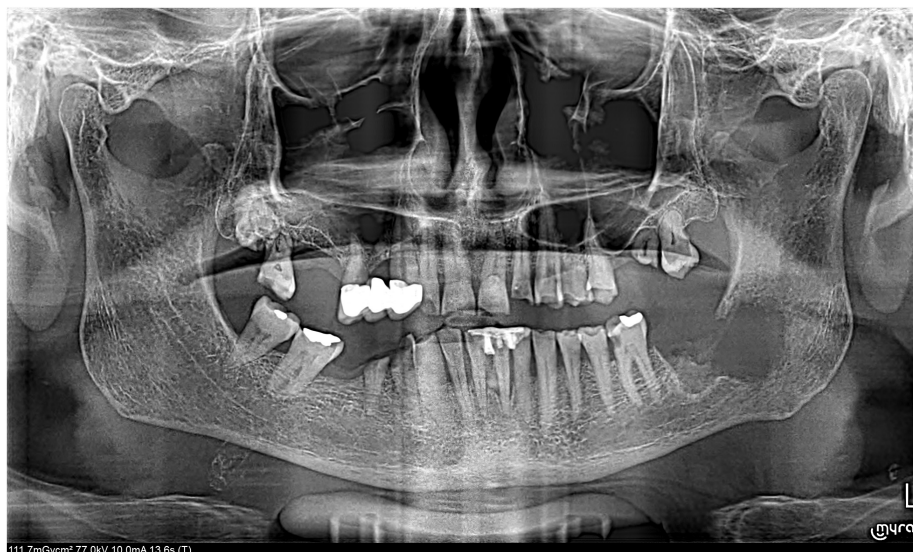


FIGURE 2 Panoramic X-ray after surgery

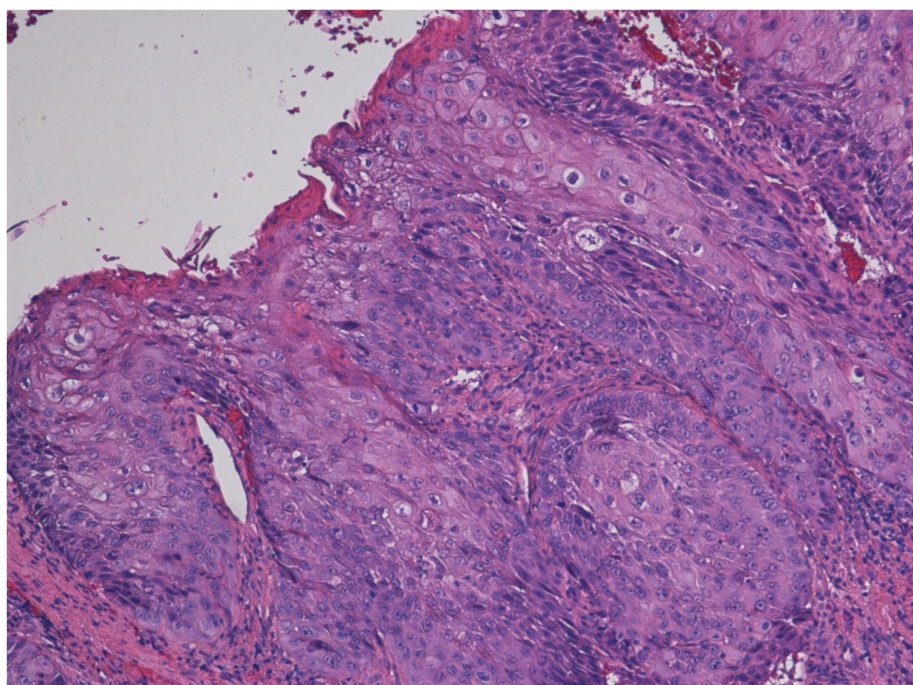


FIGURE 3 Histological report: Showing squamous cell carcinoma in a fibrous stroma

reconstruction by means of a fibula and radial flap. During the surgical procedure, it was not possible to use the fibula flap, due to the removal, during the operation, also of the mandibular condyle.

3 | DISCUSSION

PIOC is rare.¹ As of 2011, only 116 cases arising in cysts had been reported.¹² As of 2001, 35 cases with no precursor lesion had been reported. The stringent diagnostic criteria

for confident diagnosis of odontogenic origin are difficult to assess with certainty, and a precursor benign lesion can be confidently excluded or confirmed in only a minority of cases.¹³ All types of PIOC (whether developing in cysts or not) show a male predilection, with a male-to-female ratio of almost 2:1 (reflecting the prevalence of cysts) and a mean patient age diagnosis of 55–60 years. Although the age range is broad, and cases have been reported in children.

Most lesions are asymptomatic incidental radiographic findings. More-advanced lesions cause non-specific signs and symptoms suggesting malignancy: slow-growing

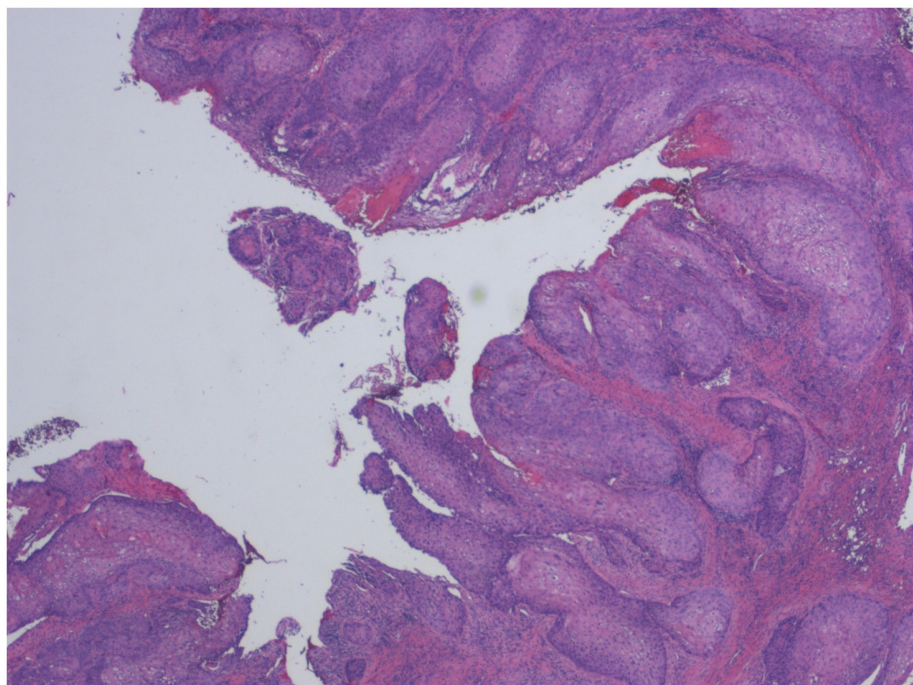


FIGURE 4 Histological report: Verrucous dysplasia in an odontogenic cyst. The features are primarily architectural, with limited or no cytological atypia

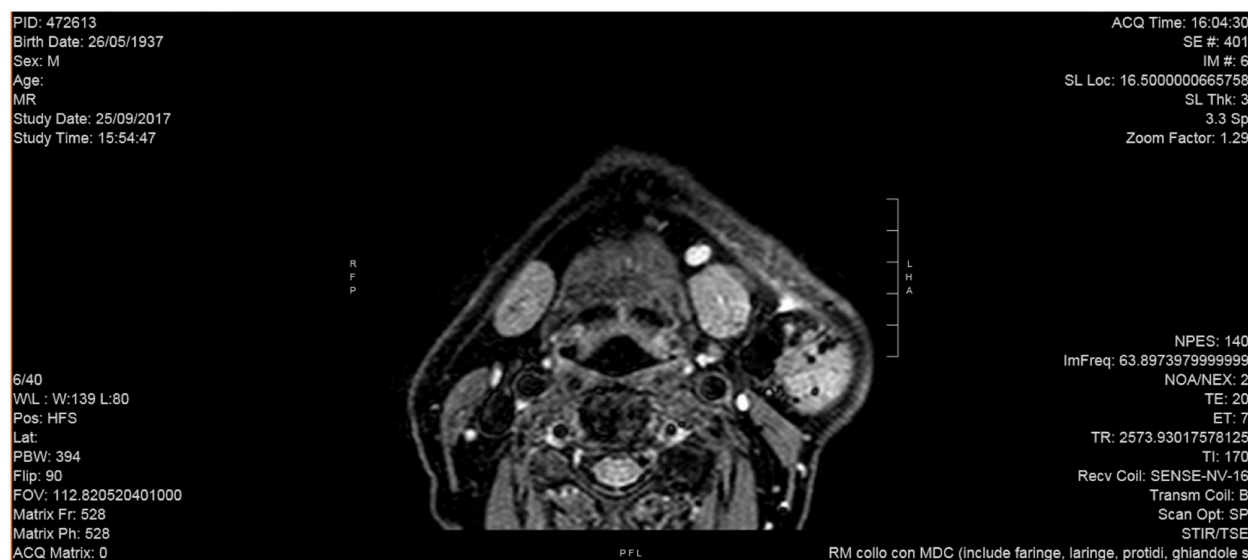

FIGURE 5 MRI with contrast. Revealed a primitive neoplasm localized in the proximal third of the left mandibular branch, lytic expansive, infiltrating the distal end of the masseter muscle, the medial pterygoid muscle and marginally also the distal mandibular insertion of the ipsilateral mylohyoid muscle

swelling of the jaw, pain, ulceration, loosening of the teeth, non-healing extraction sockets, pathological fracture and nerve signs. Radiographically, the tumours produce a poorly defined, non-corticated radiolucency. Approximately 40% of patients have metastasis on presentation.³

Radicular/residual cysts are the most common precursors, followed by dentigerous cysts and odontogenic keratocysts, reflecting their relative prevalence.¹⁴ When the tumour is detected early, the radiological features appear benign and the carcinoma is an incidental histological finding on enucleation. More frequently, there is a subtle loss of cortication or

tooth resorption. Advanced lesions develop fully malignant appearances. The only evidence of the benign precursor cyst may be in previous radiographs.¹⁵

Almost all lesions are squamous in type and composed of islands or small nests of neoplastic squamous epithelium, with pickle pick-cell differentiation and without prominent keratinization. Many appear cytologically bland, and most are considered moderately differentiated. Necrosis is unusual. Some show limited peripheral palisading or a plexiform pattern that suggests their odontogenic origin. An insufficient number of cases have been reported to determine the outcome, but the prognosis is generally poor and is best predicted by histological grade. Radical resection has been the primary treatment modality, with neck dissection for metastasis or reconstruction. Multimodality treatment provides added benefit and has been reported to provide a 3-year survival rate of 40%. As many as 60% of lesions recur locally¹; none series, patients with local recurrence all died of the disease. Distant metastasis is infrequent and is usually to the lung. As of 2001, the 5-year survival rate of reported cases was 52%.¹⁰ Cases arising in cysts often appear to be better differentiated and have a more prolonged course, but the 5-year survival rate of reported cases is slightly lower, at 40%. When cysts are found to harbour incidental dysplasia or carcinoma in situ after enucleation, conservative close follow-up is appropriate.

According to Shear's study in 1969, the 5-year survival was 30%–40%.^{16,17}

More recently, based on a 2021 review selecting 22 articles with 29 patients only 7 of these patients (24.1%) showed local recurrence, three patients (10.3%) developed cervical metastasis, three patients (10.3%) developed distant metastasis (in the pleura in one case and the lung in two cases) and seven patients died from the disease during the follow-up period and the disease-specific 5-year survival rate in the study group was 53.2%.¹⁸

4 | CONCLUSIONS

Carcinomas on cysts have radiological 'red flag' characteristics (bone erosion, large dimension, involvement of Inferior Alveolar Nerve) that must be taken into consideration in order to perform an early diagnosis and a correct treatment. The accurate radiological study can reduce misdiagnosis and improper treatment. PIOSCC have a progression of the disease and a different prognosis from real intraosseous carcinomas (PIC) and although it is a rare entity it must be considered in the differential diagnosis of larger osteolytic lesions.

Resuming, this case underlines the importance of routine follow-up of patients presenting large inflammatory cyst. This is essential for increasing the overall survival of these patients.

ACKNOWLEDGEMENT

Open Access Funding provided by Università degli Studi di Trieste within the CRUI-CARE Agreement. [Correction

added on 16 May 2022, after first online publication: CRUI funding statement has been added.]

CONFLICT OF INTEREST

The authors declare that they have no conflict of interest in relation to this paper. The study was self-funded by the authors.

ORCID

Michele Maglione  <https://orcid.org/0000-0003-0410-1784>

Rossana Bussani  <https://orcid.org/0000-0001-8241-9726>

Lorenzo Bevilacqua  <https://orcid.org/0000-0002-7245-8358>

REFERENCES

1. El-Naggar AK, Chan JKC, Grandis JR, Takata T, Slootweg PJ. WHO classification of head and neck tumours. Vol 9. 4th ed. Geneva: WHO; 2017.
2. González-García R, Sastre-Pérez J, Nam-Cha SH, Muñoz-Guerra MF, Rodríguez-Campo FJ, Naval-Gas L. Primary intraosseous carcinomas of the jaws arising within an odontogenic cyst, ameloblastoma, and de novo: report of new cases with reconstruction considerations. *Oral Surg Oral Med Oral Pathol Oral Radiol Endod*. 2007;103(2):e29–33. <https://doi.org/10.1016/j.tripleo.2006.08.007>
3. Nomura T, Monobe H, Tamaruya N, Kishishita S, Saito K, Miyamoto R, et al. Primary intraosseous squamous cell carcinoma of the jaw: two new cases and review of the literature. *Eur Arch Otorhinolaryngol*. 2013;270(1):375–9. <https://doi.org/10.1007/s00405-012-2235-9>
4. Takahashi H, Takaku Y, Kozakai A, Otsuru H, Murata Y, Myers MW. Primary intraosseous squamous cell carcinoma arising from a dentigerous cyst of the maxillary wisdom tooth. *Case Rep Oncol*. 2020;13(2):611–6. <https://doi.org/10.1159/000507478>
5. Woolgar JA, Triantafyllou A, Ferlito A, Devaney KO, Lewis JS Jr, Rinaldo A, et al. Intraosseous carcinoma of the jaws: a clinicopathologic review. Part III: primary intraosseous squamous cell carcinoma. *Head Neck*. 2013;35(6):906–9. <https://doi.org/10.1002/hed.22922>
6. Eversole LR. Malignant epithelial odontogenic tumors. *Semin Diagn Pathol*. 1999;16(4):317–24.
7. Jain M, Mittal S, Gupta DK. Primary intraosseous squamous cell carcinoma arising in odontogenic cysts: an insight in pathogenesis. *J Oral Maxillofac Surg*. 2013;71(1):e7–14. <https://doi.org/10.1016/j.joms.2012.08.031>
8. Abdelkarim AZ, Elzayat AM, Syed AZ, Lozanoff S. Delayed diagnosis of a primary intraosseous squamous cell carcinoma: a case report. *Imaging Sci Dent*. 2019;49(1):71–7. <https://doi.org/10.5624/isd.2019.49.1.71>
9. Panneerselvam K, Parameswaran A, Kavitha B, Panneerselvam E. Primary intraosseous squamous cell carcinoma in a dentigerous cyst. *South Asian J Cancer*. 2017;6(3):105. <https://doi.org/10.4103/2278-330X.214579>
10. Marchal A, Gérard É, Curien R, Bourgeois G. Primary intraosseous carcinoma arising in dentigerous cyst: case report. *Int J Surg Case Rep*. 2020;76:530–3. <https://doi.org/10.1016/j.ijscr.2020.10.059>
11. de Moraes EF, Carlan LM, de Farias Moraes HG, Pinheiro JC, Martins HDD, Barboza CAG, et al. Primary intraosseous squamous cell carcinoma involving the jaw bones: a systematic review and update. *Head Neck Pathol*. 2021;15(2):608–16. <https://doi.org/10.1007/s12105-020-01234-z>
12. Bodner L, Manor E, Shear M, van der Waal I. Primary intraosseous squamous cell carcinoma arising in an odontogenic cyst: a clinicopathologic analysis of 116 reported cases. *J Oral Pathol Med*. 2011;40(10):733–8. <https://doi.org/10.1111/j.1600-0714.2011.01058.x>

13. Bacci C, Donolato L, Stellini E, Berengo M, Valente M. A comparison between histologic and clinical diagnoses of oral lesions. *Quintessence Int.* 2014;45(9):789–94. <https://doi.org/10.3290/j.qi.a32440>
14. Açıkgöz A, Uzun-Bulut E, Özden B, Gündüz K. Prevalence and distribution of odontogenic and nonodontogenic cysts in a Turkish population. *Med Oral Patol Oral Cir Bucal.* 2012;17(1):e108–15. <https://doi.org/10.4317/medoral.17088>
15. Wenguan X, Hao S, Xiaofeng Q, Zhiyong W, Yufeng W, Qingang H, et al. Prognostic factors of primary intraosseous squamous cell carcinoma (PIOSCC): a retrospective review. *PLoS One.* 2016;11(4):e0153646. <https://doi.org/10.1371/journal.pone.0153646>
16. Acharya S, Tayaar AS, Hallkeri K, Adirajaet S, Gopalkrishnan K. Squamous cell carcinoma emerging in an orthokeratinized odontogenic cyst: a case report and brief review. *J Oral Maxillofac Surg Med Pathol.* 2014;4:563–8. <https://doi.org/10.1016/j.ajoms.2013.06.011>
17. Kikuchi K, Ide F, Takizawa S, Suzuki S, Sakashita H, Li TJ, et al. Initial-stage primary intraosseous squamous cell carcinoma derived from odontogenic Keratocyst with unusual Keratoameloblastomatous change of the maxilla: a case report and literature discussion. *Case Rep Otolaryngol.* 2018;2018:7959230. <https://doi.org/10.1155/2018/7959230>
18. Ye P, Wei T, Gao Y, Zhang W, Peng X. Primary intraosseous squamous cell carcinoma arising from an odontogenic keratocyst: case series and literature review. *Med Oral Patol Oral Cir Bucal.* 2021;26(1):e49–55. <https://doi.org/10.4317/medoral.23947>

How to cite this article: Maglione M, Bussani R, Camurri Piloni N, Bevilacqua L. A primary intraosseous squamous cell carcinoma case report and literature review. The new WHO classification. *Oral Surg.* 2022;15:657–662. doi:[10.1111/ors.12737](https://doi.org/10.1111/ors.12737)