

Diagnosis of chronic anaemia in gastrointestinal disorders: A guideline by the Italian Association of Hospital Gastroenterologists and Endoscopists (AIGO) and the Italian Society of Paediatric Gastroenterology Hepatology and Nutrition (SIGENP)

Luca Elli ^{a,*}, Lorenzo Norsa ^b, Angelo Zullo ^c, Antonio Carroccio ^{d,e}, Carlo Girelli ^f, Salvatore Oliva ^g, Claudio Romano ^h, Gioacchino Leandro ⁱ, Massimo Bellini ^j, Riccardo Marmo ^k, Marco Soncini ^l, Fabio Monica ^m, Vincenzo De Francesco ⁿ, Emma Paulon ^m, Maria Domenica Cappellini ^{o,p}, Irene Motta ^{o,p}, Francesca Ferretti ^a, Stefania Orlando ^a, Pasquale Mansueto ^e, Elisabetta Buscarini ^q, Guido Manfredi ^q, Carlo Agostoni ^{r,p}, Carolina Tomba ^s, Renato Cannizzaro ^t

^a Gastroenterology and Endoscopy Division/Center for Prevention and Diagnosis of Coeliac Disease, Fondazione IRCCS Ca' Granda Ospedale Maggiore Policlinico, Milano

^b Division of Paediatric Gastroenterology, Hepatology and Transplantation, ASST "Pope Giovanni XXIII", Bergamo

^c Gastroenterology and Digestive Endoscopy, "Nuovo Regina Margherita" Hospital, Rome

^d Internal Medicine, "Giovanni Paolo II" Hospital, Siacca

^e Biomedical Department of Internal and Specialist Medicine – DiBiMIS, University of Palermo, Palermo

^f Gastroenterology and Digestive Endoscopy Unit, Hospital of Busto Arsizio, Busto Arsizio

^g Paediatric Gastroenterology and Liver Unit, University "La Sapienza" of Rome, Roma

^h Paediatric Gastroenterology and Cystic Fibrosis Unit, Department of Human Pathology in Adulthood and Childhood "G. Barresi", University of Messina, Messina

ⁱ National Institute of Gastroenterology "S. De Bellis" Research Hospital, Castellana Grotte, Italy

^j Gastrointestinal Unit, Department of Translational Research and New Technology in Medicine and Surgery, University of Pisa, Pisa

^k Gastroenterology ed Endoscopy, Polla Hospital, Salerno

^l Internal Medicine, "Alessandro Manzoni" Hospital, ASST-Lecco, Lecco

^m Gastroenterology and Digestive Endoscopy Unit, Cattinara Hospital, Trieste

ⁿ Gastroenterology Unit, "Riuniti" Hospital, Foggia, Italy

^o Rare Diseases Center, Department of Medicine, Fondazione IRCCS Ca' Granda Ospedale Maggiore Policlinico, Milano

^p Department of Clinical Sciences and Community Health, University of Milan, Milano

^q Gastroenterology Unit, ASST Ospedale Maggiore di Crema, Crema

^r Paediatric Intermediate Care Unit, Fondazione IRCCS Ca' Granda Ospedale Maggiore Policlinico, Milano

^s Gastroenterology 2, ASST Papa Giovannin XXIII, Bergamo

^t Oncological Gastroenterology Division, Centro di Riferimento Oncologico (CRO) IRCCS, Aviano

A B S T R A C T

Anaemia is a common pathologic condition, present in almost 5% of the adult population. Iron deficiency is the most common cause; other mechanisms can be involved, making anaemia a multi-factorial disorder in most cases. Anaemia being a frequent manifestation in the diseases of the gastrointestinal tract, patients are often referred to gastroenterologists. Furthermore, upper and lower endoscopy and enteroscopy are pivotal to the diagnostic roadmap of anaemia. In spite of its relevance in the daily clinical practice, there is a limited number of gastroenterological guidelines dedicated to the diagnosis of anaemia. For this reason, the Italian Association of Hospital Gastroenterologists and Endoscopists and the Italian Society of Paediatric Gastroenterology, Hepatology and Nutrition commissioned a panel of experts to prepare a specific guideline on anaemia and its diagnostic roadmap in the gastroenterological scenario. The panel also discussed about the potential involvement of gastroenterologists and endoscopists in the management of patients with anaemia, with particular attention to the correct use of investigations. The panel

* Corresponding author at: Gastroenterology and Endoscopy Division Center for Prevention and Diagnosis of Coeliac Disease Fondazione IRCCS Ca' Granda Ospedale Maggiore Policlinico Via F. Sforza 28, Milan, 20122, Italy.

1. Introduction

Anaemia is a worldwide pathological condition that affects almost 5% of the adult population in the Western countries, iron deficiency (ID) being its most frequent cause [1,2]. The disorders of the gastrointestinal (GI) tract frequently lead to an anaemic status and thus patients are frequently referred to a gastroenterologist [3,4]. GI diseases can induce anaemia through different mechanisms: malabsorption (e.g. coeliac disease, CD) [5], obscure bleeding (e.g. intestinal vascular malformations) [6], chronic inflammation (e.g. inflammatory bowel disease) [7], autoimmune reactions against specific factors (e.g. pernicious anaemia) [8] or, frequently, as a consequence of combined mechanisms. Furthermore, anaemia is a major indication for endoscopy (upper, lower and, in specific cases, enteroscopy) and thus, gastroenterologists should be aware about the differential diagnosis, blood and faecal tests, and diagnostic procedures to use when facing anaemic patients [3]. In spite of its relevance in daily clinical practice, only a few guidelines specifically written for the gastroenterological setting have been published, none of which from the Italian gastroenterological societies [3,9–11].

The present guideline aims to support gastroenterologists in their practice when dealing with patients with anaemia. Apart the necessity to develop a national guideline and differently from the other published guidelines, the proposed one focused on the role of the gastroenterologists and endoscopists in the diagnostic process of patients with anaemia presenting specific sections and including the pediatric and adult settings.

2. Methods

In March 2017 the Italian Association of Hospital Gastroenterologists and Endoscopists (AIGO), supported by the Italian Society of Paediatric Gastroenterology, Hepatology and Nutrition (SIGNEP), commissioned a panel of experts, with the aim to prepare a guideline to support specialists in the diagnosis of anaemia related to GI tract diseases. Furthermore, the panel was supported by two members of the Italian Society of Hematology (MDC and IM). The specific tasks carried out by the panel members are reported in the Supplementary File 1 herewith provided.

Key questions were developed following the PICO format [12] and voted. A PubMed/EMBASE search for English-written articles, with no time limits and using appropriate MeSH terms (Supplementary File 1) was performed. Regular conference calls, web-based exchanges and two intermediate meetings were scheduled. The levels of evidence and recommendations were defined for every part of the statement according to the GRADE system [13]. At the end, the panel voted the statements. For clearness, a list of abbreviation is reported in supplementary file 2.

3. Classification, diagnosis and clinical biomarkers of anaemia

Anaemia is defined as haemoglobin (Hb) levels <12 g/dl in women and <13 g/dl in men [1]. It is found in one third of the world population and children aged <5 years and women have the highest burden. Half of the cases of anaemia worldwide are due to ID [14]. For practical purposes, anaemia can be classified on the basis

of either the mean cellular volume (MCV), or the underlying pathological mechanism (hypoproliferative, maturation abnormalities, increased destruction of red cells) or the patient's clinical history (acquired or congenital, acute or chronic). In the presence of low MCV (<80 fl), the iron status (serum iron, transferrin, transferrin saturation or total iron capacity and ferritin) is necessary to identify ID anaemia (IDA) [15]. However, a normal MCV level does not exclude the presence of ID, the same way as in chronic inflammatory diseases. Recently, a panel of experts defined ID in chronic inflammatory disorders as "a health-related condition in which iron availability is insufficient to meet the body needs" and the following cut-off values have been proposed for diagnosis: i) serum ferritin <100 mcg/L or transferrin saturation (TSAT) <20%; ii) serum ferritin between 100 mcg/L and 300 mcg/L and TSAT <20% [16]. A high level of MCV (>100 fl) is found in "megaloblastic anaemia", usually due to nutritional deficiency or malabsorption of vitamin B₁₂ and/or folate [17]. In order to evaluate the underlying pathological mechanism, reticulocyte count, a marker of red blood cell production can direct further investigation. Reticulocytes are usually expressed as percentage of the number of red blood cells or as an absolute number, but the most appropriate parameter is the reticulocyte index (RI): $\text{Reticulocyte\%} \times \text{Ht} \times \text{normal } 45\%^{-1}$ (for example in case of reticulocyte 2%, Ht 45% the RI is 2) which is corrected for the severity of anaemia. Several novel serological bio-markers are today available to diagnose, classify and evaluate the therapeutic response (Table 1).

3.1. Faecal occult blood test

Noteworthy, the use of the stool-based tests is frequently inappropriately used in clinical practice. Thanks to their diagnostic accuracy and non-invasiveness, they are widely carried out in primary care and recommended as first-line screening tools for colorectal cancer (CRC) [18,19]. The most frequently used stool-based CRC screening tests are the guaiac-based faecal occult blood test (gFOBT), and the faecal immunochemical test (FIT). Stool-based tests are a screening tool and, therefore, should be reserved for asymptomatic subjects within the average-risk cohort for CRC screening. The inadequate use of stool-based tests (e.g. outside the age criteria or on subjects with a life expectancy less than 10 years or patients with a family history of CRC who should better undergo direct colonoscopy) increases the number of inappropriate colonoscopies, the amount of costs and overall exposure to potential endoscopic complications [20]. Moreover, stool-based screening tests should not be used in symptomatic subjects such as those reporting anaemia, ID, overt gastrointestinal bleeding, non-bloody diarrhea, abdominal pain or change in bowel habits, as their use postpones the necessary endoscopic investigation, thus leading to diagnostic delays [21,22].

3.1.1. Panel recommendations

- *Stool-based tests (FOBT or FIT) should not be carried out on patients with anaemia to investigate its origin (strong recommendation, moderate level of evidence).*

Vote result: strongly agree 60%, agree 26.7%, moderately agree 6.7%, moderately disagree 0%, disagree 0%, strongly disagree 6.7%

Table 1
Serological biomarkers available for diagnosing, classifying and managing anaemia.

Biomarker	Normal range	Clinical utility
Haemoglobin	Adult Male: 13–18 g/dl. Adult Female: 12–16 g/dl.	To diagnose anaemia. To evaluate therapeutic response.
Mean cellular volume, MCV	80–100 fl	To define Normo-/Macro-/Micro-cytic anaemia.
Mean corpuscular haemoglobin, MCH	26–32 pg/cell	To define Normo-/Iper-/Ipo-chromic anaemia.
Mean corpuscular haemoglobin concentration, MCHC	32%–36%	To define Normo-/Iper-/Ipo-chromic anaemia.
Red blood cell distribution width, RDW	11.8%–15.6%	To evaluate RBC distribution. If increased: suspicion of concomitant presence of different populations of RBC (as in iron and/or folate and/or vitamin B ₁₂ deficiency) or presence of reticulocytes.
Reticulocytes	Absolute values: 25–75 × 10 ⁹ /l Reticulocytes Index: 0.5%–2.5%	Index of erythropoietic activity.
Ferritin	20–200 mcg/l	It reflects the total amount of iron deposits in the body and is essential to define iron deficiency. Inflammatory protein.
Transferrin	240–360 mg/dl	Main iron transport protein in the bloodstream. Usually increased in iron deficiency anemia, pregnancy, estrogen administration and decreased during iron overload, malnutrition, inflammatory condition Useful to distinguish anaemia due to chronic disorders from iron deficiency anaemia.
Total iron binding capacity, TIBC	240–450 mcg/dl	Indirect measurement of transferrin's capacity of binding iron. Increased in iron deficiency.
Transferrin saturation, TSAT	males: 20%–50% females: 15%–50%	Sideraemia/TIBC × 100 Indirect measurement of transferrin's capacity of binding iron. Usually decrease in iron deficiency and increase in iron overload.
Sideraemia	53–167 mcg/dl	Not indicative of body deposits. If decreased: severe iron deficiency, chronic and/or neoplastic and/or inflammatory diseases. Limited diagnostic value (significant decrease only when the body deposits are almost depleted).
Soluble transferrin receptor	4–7 mg/l	Increased in hyperplastic erythropoiesis and/or iron deficiency. Decreased in hypoplastic erythropoiesis Useful to distinguish iron deficiency anaemia from anaemia caused by chronic or inflammatory diseases.
Hepcidin	Variable values (based on different laboratory methods, nonstandardized normal values are available)	Liver peptide hormone. It regulates iron homeostasis. Acute phase protein. Increased in chronic inflammatory conditions.
Zinc Protoporphyrin	Variable values (based on different laboratory methods, no standardized normal values are available)	Increased in erythropoiesis disorders, including hypochromic anaemia. Not useful for differentiating iron deficiency anaemia from chronic inflammation anaemia.
Erythropoietin	2–25 U/l	Hormone stimulating erythropoiesis. Decreased in chronic kidney disease.
Vitamin B12	150–900 pg/ml	Decreased in megaloblastic anaemia.
Folate	2.7–17 ng/ml	Decreased in megaloblastic anaemia.
Haptoglobin	32–205 mg/dl	Protein binding the extra-globular haemoglobin and conveying it to the reticuloendothelial system. Decreased in hemolytic anaemia.
Bilirubin	Total: 0.3–1.0 mg/dl Direct: 0.0–0.4 mg/dl Indirect: 0.1–1.0 mg/dl	Increased in hemolytic anaemia (total and indirect).
Lactate dehydrogenase, LDH	135–225 U/l	Intra-cytoplasmatic enzyme. Increased in haemolytic anaemia.
Urinary hemoglobin	Absent	Increased in haemolytic anaemia.
Urinary urobilinogen	<0.2 EU/dl	Increased in haemolytic anaemia.

4. Role of endoscopy

4.1. Upper endoscopy

Although invasive, upper endoscopy is widely carried out in the Western countries. Considering the demographic characteristics and clinical history of a patient, it is possible to schedule an adequate strategy and a correct timing for upper endoscopy. IDA in pre-menopausal women is usually attributed to excessive menstrual blood loss (9% to 14% of all women) [23] or to an inadequate dietary intake [24]. In this subset of subjects, if the gynaecological work-up is unremarkable and patients do not respond to iron replacement therapy (IRT), upper endoscopy should firstly be performed to exclude occult blood bleeding from gastric or duodenal GI lesions [25–27]. Significant upper GI tract lesions are present in up to 30% of pre-menopausal women with IDA, as erosive lesions caused by *H. pylori* or NSAID use (55%–68% of cases); upper GI cancers are very rare (0%–3%) [27]. All pre-menopausal women with anaemia should be screened for coeliac disease (CD), which is present in up to 6% of them [25] and duodenal biopsies should be taken.

An increased risk of diagnosing GI cancer within the subsequent two years was observed among men and post-menopausal women with IDA (in 6% of patients older than 50 years and in 9% of women older 65 years) [28]. With these groups of patients, GI sources of bleeding should be excluded, as the first step of the diagnostic flowchart. The current recommendations from the American Family Physicians [29] support upper endoscopy as the first investigation; however, there are no clear guidelines about the correct sequence of the endoscopic investigations [30]. In patients over 50 years, the colonoscopy-first strategy should be preferred [31].

The existence of site-specific symptoms can be a disease predictor, suggesting the route of insertion (upper or lower) [32]. If necessary, upper and lower GI endoscopy can be performed in the same session and the combination of both exams is highly specific to localize any bleeding GI sites that cause anaemia [33,34].

Upper endoscopy can find the cause of digestive bleeding in about 90% of symptomatic cases; its diagnostic yield (DY) drops to 62%–70% in case of asymptomatic patients [32]. Noteworthy, lesions can be missed at the first investigation in about 10% of all upper endoscopies [35]; superficial lesions in hiatal hernia or vascular ectasia of the upper GI tract are often underdiagnosed and

can be difficult to detect. Simultaneous lesions of both the upper and lower gastrointestinal tracts have been found in 9% [36]. An upper GI bleeding source is found in more than one third of the patients with IDA, and most of the lesions are benign [37]. It is important to consider also the existence of non-bleeding sources of IDA, including: CD, gastric surgery, atrophic gastritis, *H. pylori* infection, autoimmune gastritis [37]. For these reasons upper GI endoscopy should include random gastric antral and fund biopsies in addition to duodenal biopsies [38].

It is still unclear whether site-specific symptoms (in the upper and/or lower GI tract) are really predictors of a bleeding lesion at the corresponding site [39,40,41]. Predictors comprise: abdominal symptoms, weight loss (Δ -10% of body weight), and haemoglobin level <10 g/dl with MCV <72 fl. The prevalence of GI cancers in patients with non-ID anaemia is low as compared with patients with IDA (up to 15%) [42]. Although the ferritin cut-off value to be considered in anaemic patients as a predictor of malignancy is not clear, evaluating the GI tract of patients with ferritin levels higher than 100 ng/ml (in the absence of an acute phase response) by endoscopy should not be considered, but the evidence available is still scanty [43,44].

If upper endoscopy is normal and anaemia is not severe without alarm symptoms, oral IRT and a watch-and-wait strategy can be carried out. For patients that do not respond to IRT or with suspected serious illness, a second look by endoscopy may be justified [45].

4.1.1. Panel recommendations

- Upper endoscopy should be performed on pre-menopausal women, in case of failure of the iron replacement therapy (strong recommendation, low level of evidence).

Vote result: strongly agree 33.3%, agree 60%, moderately agree 6.7%, moderately disagree 0%, disagree 0%, strongly disagree 0%

- In case of macroscopically negative upper endoscopy, gastric and duodenal biopsies should be taken in order to exclude coeliac disease and autoimmune gastritis (strong recommendation, low level of evidence).

Vote result: strongly agree 53.3%, agree 40%, moderately agree 6.7%, moderately disagree 0%, disagree 0%, strongly disagree 0%

- Upper endoscopy is often complementary to colonoscopy in the search of a bleeding source. When a source is found in patients aged over 50 years, we suggest avoiding colonoscopy only in the presence of an upper GI cancer (weak recommendation, low level of evidence)

Vote result: strongly agree 40%, agree 46.7%, moderately agree 13.3%, moderately disagree 0%, disagree 0%, strongly disagree 0%

4.2. Lower endoscopy

Blood loss from the GI tract is the most frequent cause of IDA in men and post-menopausal women [46]. Among post-menopausal women and adult men with IDA, upper endoscopy and colonoscopy reveal upper GI lesions in 7%–72%, lower GI lesions in 7%–58%, and lesions affecting both tracts in 0%–29% of the cases. The main colonoscopy findings are: colorectal cancer (0%–34%), adenomas (1%–27%), inflammatory bowel disease (0.4%–10%) and angiodysplasia (0%–7%) [47]. In pre-menopausal women with IDA the DY of endoscopic investigations is up to 95% for upper GI lesions and up to 16% for lower GI lesions. In this group the prevalence of cancer is low (0%–6%) and mostly found in patients aged over 40 years [28]. Based on these findings [48] and the high prevalence of

GI malignancies in adults, the current guidelines recommend that upper and lower GI investigations should be offered to patients aged >50 years [3]. As previously mentioned, the order of the investigations should be guided by the suggestive symptoms (when present), although colonoscopy should be prioritized for patients aged >50 years, because of the high prevalence (roughly 10%) of CRC in this scenario [49].

In pre-menopausal women presenting IDA GI bleedings have been found, mainly, in the upper GI tract while lesions of the lower GI tract have been infrequently described [47]. The guidelines from the British Society of Gastroenterology (BSG) recommend colonoscopy for pre-menopausal <50 years old women with lower abdominal symptoms, a family history for CRC or persistent IDA in spite of IRT [3]. Furthermore, despite the lack of evidence, the BSG guidelines recommend that young men (<50 years old) with IDA should be investigated in the same manner as older men [3]. This recommendation is weakly supported by the few published studies, which have confirmed the infrequent presence of any significant lower GI pathology in young men with IDA [50–52]. A recent study compared colonoscopy findings in young patients (both male and female, aged 40–49 years) to the average-risk of individuals aged 50–54 years undergoing colonoscopy. It concluded that young patients with IDA have a significant lower risk of advanced neoplasia, therefore it would be less likely that they were to benefit from colonoscopy [52]. Noteworthy, the possible increase in the DY by adding ileoscopy during standard colonoscopy has not been specifically investigated in the setting of anaemia; however, the potential usefulness of ileitis detection in this setting represents a potential indication.

4.2.1. Panel recommendations

- Colonoscopy should be performed on all men and post-menopausal women with IDA (strong recommendation, low quality of evidence).

Vote result: strongly agree 66.7%, agree 26.7%, moderately agree 6.7%, moderately disagree 0%, disagree 0%, strongly disagree 0%

- The visualization of the distal ileum during standard endoscopy should be performed to reveal the presence of ileitis (conditional recommendation, low quality of evidence).

Vote result: strongly agree 26.7%, agree 60%, moderately agree 13.3%, moderately disagree 0%, disagree 0%, strongly disagree 0%

- Colonoscopy should be performed on pre-menopausal women with IDA in one or more of the following scenarios: proven absence of a gynaecological cause of IDA, strong family history for CRC, presence of lower abdominal symptoms, failure to respond to IRT (strong recommendation, low quality of evidence).

Vote result: strongly agree 53.3%, agree 46.7%, moderately agree 0%, moderately disagree 0%, disagree 0%, strongly disagree 0%

4.3. Small-bowel endoscopy

In case of normal findings at upper and lower gastrointestinal endoscopy, the small bowel (SB) of anaemic patients, should be deeply investigated [53–57]. A systematic review with meta-analysis, including 24 studies and 1960 patients with IDA, has provided an overall pooled DY of capsule enteroscopy (CE) of 47% (95% CI, 42–52) [58]. In 4 studies (264 patients) focusing on patients with IDA, the DY was 66% (95% CI, 61–72). The most frequently detected lesions were: vascular (31%), inflammatory (18%), and mass/tumor (8%). Noteworthy, a similar finding frequency was for patients less than 50 years of age, underlying the usefulness of CE

for young patients [59]. Furthermore, in case of normal CE results, a watch-and-wait strategy with scheduled clinical re-evaluation is advised by recent guidelines and meta-analyses [53,55–59].

Endoscopic SB exploration is nowadays feasible by means of CE (for diagnostic purposes) and device-assisted enteroscopy (DAE, diagnostic and therapeutic options). A meta-analysis [60] compared the DY of CE vs. double-balloon enteroscopy (DBE) in patients with obscure GI bleeding. The authors pooled the data from 10 studies: the DY was 62% (95% CI, 47–76) for CE and 56% (95% CI, 48–62) for DBE, with an odds ratio for CE compared with DBE of 1.4 (95% CI, 0.9–2.2). A sub-group analysis demonstrated that the DY of a CE-DBE sequential approach was 75% (95% CI, 60–90), with an odds ratio of 1.8 (95% CI, 1–3). Conversely, the DY of DBE after a negative CE was 27% (95% CI, 16–38). Moreover, the CE finding facilitates the decision about the route of insertion and is associated with better long-term outcomes, decreased number of complications and more effective use of endoscopic resources [61].

In a meta-analysis pooling 46 studies and 5796 patients [62], the overall risk of re-bleeding was significantly higher after positive CE compared to negative CE in the Asian studies (OR: 1.8; 95% CI, 1.1–3). The application of a specific therapy after a positive CE index was associated with a lower re-bleeding risk in both the Western (OR 0.4; 95% CI, 0.2–0.9) and Eastern (OR 0.4; 95% CI, 0.2–0.7) populations independently of the bleeding presentation (overt vs. occult).

4.3.1. Panel recommendations

- For patients with anaemia and suspected obscure mid gut bleeding, CE is the first-line diagnostic tool (strong recommendation, low level of evidence).

Vote result: strongly agree 66.7%, agree 33.3%, moderately agree 0%, moderately disagree 0%, disagree 0%, strongly disagree 0%

- DAE should be performed as the second-line intervention and in case of operative enteroscopy or bioptic sampling (strong recommendation, moderate level of evidence).

Vote result: strongly agree 60%, agree 33.3%, moderately agree 6.7%, moderately disagree 0%, disagree 0%, strongly disagree 0%

5. Role of radiologic imaging of the gastrointestinal tract

The studies evaluating the role of imaging techniques in assessing patients with anaemia have focused on computed tomography (CT) and magnetic resonance (MR). Beyond the low invasiveness, the advantages of cross-sectional imaging include the ability to examine the bowel loops throughout, with no superimposition, and the visualization of extra-luminal structures. Imaging can be performed by either enterography technique, requiring ingestion of large volumes of contrast medium, or enteroclysis, with direct administration of enteric fluid by a nasoenteric tube. The majority of studies focused on CT, which features superior temporal and spatial resolution, as compared with MR, and is widely available. Other imaging techniques are not considered; in particular, a specific role of ultrasound is not defined. The barium examination of the SB shows a low DY (3%–17%) [55] in detecting abnormalities in suspected SB bleeding. Some studies have demonstrated that CT enterography (CTE) is potentially useful to detect the source of GI bleeding in patients with overt but not occult bleeding. In absence of overt bleeding, imaging techniques can be considered for selected patients when conventional endoscopy and CE are inconclusive. The majority of CT studies compared the DY of radiology to that of endoscopy (such as CE and DAE) in case of obscure GI bleeding (OGIB). The DY of CE and CTE may be dependent upon

the underlying causes of OGIB, thus CTE should not be considered as a first-line investigation but rather as a complementary examination to CE and it can help to determine the cause of OGIB in selected patients. Compared with cross-sectional imaging, CE is uniformly superior to detect vascular abnormalities, whereas cross-sectional imaging can identify masses and some inflammatory changes missed at CE [63,64].

A single prospective study comparing CE and CTE in IDA has been published [65]. CE demonstrated to be superior to SB enteroclysis (DY 57% vs. 12%) and CTE (DY 78% vs. 22%) for patients with unexplained IDA and negative results at routine endoscopy [65]. However, the combination of the two techniques reached diagnosis in 37 out of 45 patients (82%). Other studies have reported significantly lower results in the subset of OGIB with a DY for CTE ranging from 10%–15% [66,67] to 30% [68]. A few other small-scale studies (with case series including patients with both overt and obscure bleeding) have failed to demonstrate any significant difference between CE and CTE even if the DY of CE showed superior [64,69,70]. With regard to OGIB, DAE has a higher DY than DAE; however, a complementary role of CE, CTE and DAE has been suggested in a recent retrospective study [68] which demonstrated that the DY for DAE could be increased after obtaining a previous examination with CE or CTE, in order to assess the better enteroscopic approach.

MR enterography (MRE) is a non-invasive imaging technique with a known role in monitoring the disease activity and complications of Crohn's disease (CrD). The usefulness of MRE extends to the investigation of patients with symptoms related to the jejunoileal tract, including suspected midgut bleeding. In this setting, MRE is both alternative and complementary to CE with a prominent role when obstructive symptoms are present and in case of young age because of the prevalence of SB tumors and CrD in young patients with IDA. Moreover, the absence of ionizing radiation represents the major strength of MRE, along with rapid image acquisition and high-contrast resolution. Oral and intravenous contrast agents enable the detection of intestinal wall abnormalities. Nevertheless, some limitation in diagnostic accuracy has been measured due to the sub-optimal distension of the proximal intestinal tract. The data from the literature is limited in terms of adequate inter-comparison of SB imaging techniques. MR role has been explored in prospective and retrospective studies in which the enrolment criteria consisted in IDA and/or GI symptoms suggestive of SB disease [71,72]. In those studies, MRE and CE showed comparable DY as to suspected mid-gut bleeding; however, a warning rose about a tendency towards limited radiologic accuracy in the proximal SB tract [72]. The head-to-head comparison of MRE and CE DY, using DBE and expert panel consensus as the reference standard, was accomplished by designing a prospective study including 38 OGIB patients [73]: CE and MRE resulted in 61% (95% CI, 36–81) and 21% (95% CI, 7–46) sensitivity and 85% (95% CI, 61–96) and 100% (95% CI, 9–100) specificity vs. the reference standard, respectively. The performance of CE strengthened its role as the first-choice option in suspected mid-gut bleeding cases and outlined the alternative and complementary usefulness of MRE in this context.

5.1. Panel recommendation

- For patients with anaemia, cross-sectional imaging, such as MR and CT, is not indicated as a first-line investigation (strong recommendation, moderate level of evidence).

Vote result: strongly agree 40%, agree 53.3%, moderately agree 6.7%, moderately disagree 0%, disagree 0%, strongly disagree 0%

- With IDA and suspected OGIB, CTE and MRE may be complementary to CE (and DAE) for selected patients with non-diagnostic CE,

contraindication to CE and/or suspected SB tumor (strong recommendation, moderate level of evidence).

Vote result: strongly agree 53.3%, agree 46.7%, moderately agree 0%, moderately disagree 0%, disagree 0%, strongly disagree 0%

- MRE represents a valuable diagnostic tool for IDA patients under high clinical suspicion of SB neoplasia (strong recommendation, low level of evidence).

Vote result: strongly agree 26.7%, agree 73.3%, moderately agree 0%, moderately disagree 0%, disagree 0%, strongly disagree 0%

6. Specific factors

6.1. *Helicobacter pylori*

H. pylori infection is a chronic disease that may cause IDA through different mechanisms, including blood loss, iron malabsorption, and iron consumption [74]. Occult blood loss may occur from infection-induced ulcerative or erosive lesions in the gastro-duodenal mucosa. *H. pylori*-associated chronic active gastritis, particularly when pangastritis or atrophy develops, causes some alterations of the gastric function, including decreased secretion of both gastric and ascorbic acids, which are essential to the intestinal absorption of dietary iron. Moreover, it has been observed that *H. pylori* induces hepcidin expression in the gastric mucosa [75]. The increased serum hepcidin levels in *H. pylori*-infected IDA patients decrease after successful *H. pylori* eradication [76]. Finally, iron sequestration and utilization by *H. pylori* itself have been reported [77].

A recent meta-analysis of cross-sectional studies overall found that *H. pylori*-infected patients are at increased risk of both IDA (OR 1.72; 95% CI, 1.2–2.4) and ID (OR 1.33; 95% CI, 1.1–1.5) as compared to those with no infection. A sub-group analysis of 4 studies on adults showed an OR of 1.7 (95% CI, 1–2.8) for IDA in *H. pylori* infected patients [78].

Four meta-analyses compared Hb level modifications (Standardized Mean Difference; SMD) at 1–3 months following *H. pylori* eradication therapy plus iron supplementation as compared to iron supplementation alone, and showed conflicting results [78–81]. A meta-analysis (16 trials: 13 paediatric and 3 on adults, involving 956 patients) found a significant difference between the two groups (SMD: 1.48 g/dl; 95% CI, 1–2). When taking into account the 3 studies including adults, we computed that the SMD of haemoglobin increases was 5.83 g/dl in 103 patients receiving *H. pylori* treatment and iron as compared to 3.8 g/dl in the 82 patients treated with iron alone (SMD: 2 g/dl; 95% CI, 1.5–2.5; $P=0.05$) [79]. Another meta-analysis (8 trials: 6 paediatric and 2 on adults; 450 patients) found that the overall increase of haemoglobin levels was significantly higher in *H. pylori* eradicated patients (SMD: 1.29 g/dl; 95% CI, 0.6–2, $P=0.0002$) [80]. However, the sub-group analysis of the studies on adults failed to find a significant difference (SMD: 1.5 g/dl; 95% CI, 0.8–2.2, $P=0.51$; 128 patients). A meta-analysis of 4 high-quality paediatric studies found that the increases in haemoglobin levels did not significantly differ between patients receiving iron and eradication therapy and those on only IRT (SMD: 4.06 g/dl; 95% CI, 2.6–10.7; $P=0.23$) [81]. Similarly, a more recent meta-analysis (7 studies: 6 paediatric and 1 on adults; 515 patients) has found that the haemoglobin increase did not significantly differ in the whole analysis (SMD: 0.36 g/dl; 95% CI, 7–0.78; $P=1$), as well as in the single study on adults [78]. It should be noted that all the trials on adults were confined to Asia, the quality of the studies was judged low, a significant heterogeneity among the studies emerged, and there was evidence of publication bias.

Three uncontrolled interventional studies assessed the long-term effect of *H. pylori* eradication without IRT in adult IDA patients with unexplained iron refractoriness or dependency. In an Italian study [82] on 30 patients, 18 (75%) and 22 (91.7%) out of 24 *H. pylori*-cured patients achieved IDA recovery at 6 and 12 months, respectively, at per protocol (PP) analysis, whilst no modifications occurred in the 3 patients who failed eradication. Of note, as many as 24 (80%) of these patients had pangastritis [9]. Another study performed in Israel showed IDA regression 4–69 months following bacterial eradication in 11 (78.6%) out of 14 male patients with *H. pylori* alone, as well as in further 2 (25%) out of 8 of patients with both *H. pylori* and autoimmune gastritis [83]. Finally, in a Spanish study on 84 patients (M/F: 10/74), recovery from IDA at 6 months was achieved in 80% of males, 71.4% of post-menopausal women, and 23.3% of pre-menopausal women at PP analysis [84].

6.1.1. Panel recommendations

- *H. pylori* infection needs testing in adult patients with IDA (strong recommendation, high level of evidence).

Vote result: strongly agree 33.3%, agree 53.3%, moderately agree 13.3%, moderately disagree 0%, disagree 0%, strongly disagree 0%

- Bacterial eradication may improve and accelerate IDA recovery when associated with oral iron supplementation (conditional recommendation, low level of evidence).

Vote result: strongly agree 13.3%, agree 53.3%, moderately agree 26.7%, moderately disagree 6.7%, disagree 0%, strongly disagree 0%

- *H. pylori* eradication is a therapeutic option for patients with otherwise unexplained IDA (strong recommendation, low level of evidence).

Vote result: strongly agree 13.3%, agree 60%, moderately agree 26.7%, moderately disagree 0%, disagree 0%, strongly disagree 0%

6.2. Coeliac disease

Anaemia is one of the most common presentations of CD, found in 12%–69% of adult patients, and may be the only presenting symptom [85–92]. Anaemia is mainly due to ID (80% of cases) [86,87] as a consequence of iron malabsorption [93]. On the other hand, contrasting data on the prevalence of CD in patients with anaemia have been reported. A systematic review [94] evaluated 12 studies and assessed the prevalence of CD among patients with anaemia (especially IDA) [40,92,95–104]. These authors reported a CD frequency in IDA patients with gastrointestinal symptoms ranging from 10.3% to 15% [95,99,100]. Four studies assessed the prevalence of CD in asymptomatic IDA patients by serology and CD prevalence ranged from 2.3% to 5.0% [92,97,101,102]. Other three studies assessed the prevalence of CD by duodenal histology in asymptomatic IDA patients and found values ranging from 2.9% to 6% [40,96,104]. A systematic review [105] examined 13 studies and concluded that CD is demonstrable in 1.8% to 14.6% of IDA patients [25,37,106–112]. CD frequency is higher among patients who have not responded to oral IRT compared to responsive ones [106]. Furthermore, several studies have reported that 73%–100% of IDA patients diagnosed with CD were adult pre-menopausal women. The higher iron demand in adult pre-menopausal women, as a result of menstrual loss, associated to a condition of chronic iron malabsorption attributable to CD, probably explains this higher prevalence of CD. However, such studies on CD and anaemia were heterogeneous in design, as some included only patients with IDA whereas other studies included both folate and iron-deficiency

patients, and used different methods to diagnose CD, often in selected referral populations.

In CD serological screening, the presence of IgA-anti-transglutaminase (anti-tTG IgA) or IgG-anti-deamidated gliadin peptides (anti-DGP IgG) is considered with high suspicion of CD [113]. Other guidelines suggest anti-tTG IgA testing as the only exam [114], as its accuracy is considered sufficiently high, with sensitivity and specificity of about 95%. However, as IgA deficiency occurs in 2%–3% of patients with CD [115], the measurement of IgA levels should be recommended, when only IgA-based CD serology is performed. In any case, intestinal biopsy and duodenal histology evaluation are essential for the diagnosis of adult CD and cannot be replaced by serology. Furthermore, the prevalence of sero-negative CD could be much higher than commonly considered (with estimation between 6% and 22% of all diagnosed cases) [116]. Consequently, intestinal biopsies have been suggested for individuals with anaemia of unknown origin, irrespective of whether they have had serology for CD. However, HLA DQ2/DQ8 testing should be performed on the sero-negative patients who show a high clinical suspicion of CD diagnosis, due to its high negative predictive value [117].

Noteworthy, iron malabsorption is not the only cause of anaemia in CD. In some patients, nutritional fiber/calcium deficiency may also contribute to ID in CD [118,119] as well as genetic factors [120]. Furthermore, other pathological mechanisms leading to anaemia in CD patients are folate and/or vitamin B12 malabsorption and deficiency. In affected individuals, low plasma folate and vitamin B12 deficiency were observed in 10%–81% and 5%–41% respectively [121–125].

Finally, persistent anaemia in CD patients on a gluten free diet needs to be carefully investigated. In this context, physicians must consider other concomitant causes of anaemia in such patients (i.e. blood loss, inflammation, nutritional deficiencies, folate and vitamin B₁₂ malabsorption and deficiency), development of refractory CD [126,127], concomitant *H. pylori* infection [78] or and iron-refractory iron deficiency anaemia (IRIDA, an autosomal recessive sideropenic anaemia) [128].

6.2.1. Panel recommendations

- All patients with anaemia must be serologically tested for CD (strong recommendation, high level of evidence).

Vote result: strongly agree 86.7%, agree 6.7%, moderately agree 6.7%, moderately disagree 0%, disagree 0%, strongly disagree 0%

- As the prevalence of sero-negative CD could be high, intestinal biopsies have been suggested for individuals with anaemia of unknown origin, irrespective of whether they have had serology for CD (conditional recommendation, moderate level of evidence).

Vote result: strongly agree 26.7%, agree 46.7%, moderately agree 20%, moderately disagree 6.7%, disagree 0%, strongly disagree 0%

6.3. Inflammatory bowel disease

Anaemia is the most common extra-intestinal manifestation of IBD [129], with blood loss, malabsorption, dietary restrictions, SB insufficiency being the main mechanisms [9]. Chronic disease anaemia and ID often co-exist in IBD, but the latter is prevalent [130,131].

The prevalence of anaemia in IBD is varied and depends on the studied population (in/out-patient settings) and the applied criteria. A recent meta-analysis of 6 European series has showed a cumulative prevalence of 24% (95% CI, 18–31); IDA was present in 57% of cases. Among the variables, CrD and active inflamma-

tion were the strongest risk factors [130]. The Norwegian IBSEN inception cohort (756 patients prospectively assessed at 1, 5, 10 years) showed that the relative risk (RR) for anaemia was 2.9 (95% CI, 1.9–4.2) and 1.7 (95% CI, 1.1–2.4) for CrD and ulcerative colitis (UC), respectively. The prevalence of anaemia faded with the time and extent of observation; unfortunately, the data on iron status to define the type of anaemia were unavailable [132]. Furthermore, a recent retrospective study from the USA (on administrative data) on 5104 CrD and 6249 UC cases has showed that up to one third of IBD patients present with anaemia (32.4% and 27.6% of the CrD and UC cases, respectively) and most of them have IDA [131].

The guidelines to avail recommend iron therapy to all patients with IBD and IDA, with the aim of normalizing Hb levels [9]. From 2011 to date, 5 meta-analyses [133–137], a systematic review [138] comparing intravenous (i.v.) vs. oral IRT, and a meta-analysis comparing different i.v. iron formulations [137] for patients with IDA and IBD, have been published. The first meta-analysis by Lee *et al.* [133], which included three RCTs involving 333 patients, has showed a superiority of i.v.-administered IRT compared with oral IRT; however a high number of patients discontinued oral therapy for GI side effects (OR 6.2; 95% CI, 2.2–17); 5 out of 203 patients stopped i.v. therapy for severe side effects (rash, thrombocytopenia, thrombophlebitis, edema). Except for one meta-analysis [135], all the other studies [134,136,137] confirmed an advantage of i.v. IRT over oral IRT, with a relevant number of discontinuations during oral therapy for GI symptoms, whereas in the case of i.v. therapy the side effects were rare but clinically severe. Furthermore, a network meta-analysis [137] comparing i.v. and oral therapy and the efficacy of different i.v. iron formulations (iron carboxymaltose, iron isomaltoside, iron sucrose) found that iron carboxymaltose was superior to oral therapy (OR= 1.9; 95% CI, 1.1–3.2), without differences in safety of the different i.v. iron formulations. Interestingly, a recent study [139] has showed a shift of gut microbiota toward an unsafer composition in patients administered with oral IRT, although the clinical implication of this finding is not yet fully understood.

6.3.1. Panel recommendations

- The prevalence of anaemia in IBD patients is high, thus, the presence of IBD in patients with anaemia should be carefully screened (conditional recommendation, low level of evidence).

Vote result: strongly agree 53.3%, agree 13.3%, moderately agree 33.3%, moderately disagree 0%, disagree 0%, strongly disagree 0%

- IRT is recommended for IDA and it is effective to use both the i.v. and oral routes. However, the i.v. route should be preferred (strong recommendation, high level of evidence).

Vote result: strongly agree 53.3%, agree 40%, moderately agree 6.7%, moderately disagree 0%, disagree 0%, strongly disagree 0%

7. Approach to patients with non-iron deficiency anaemia

Non-ID anaemia is infrequent and principally derives from vitamin B₁₂ and/or folate deficiency. The most frequent cause of megaloblastic anaemia is autoimmune atrophic gastritis (pernicious anemia) and thus patients with macrocytic anaemia are referred to the gastroenterologist. The diagnostic work-up includes the detection of anti-parietal cell antibodies (APCA), assessment of vitamin B₁₂ serological levels and upper endoscopy. APCA can be found in more than 85% of patients, whilst isolate intrinsic factor antibodies presence occurs in less than 1% of patients [140]. Also pepsinogen I levels can be useful in the flowchart [141]. At upper endoscopy, multiple biopsies in antrum, gastric body, fundus and duodenum should be taken, in order to perform a complete

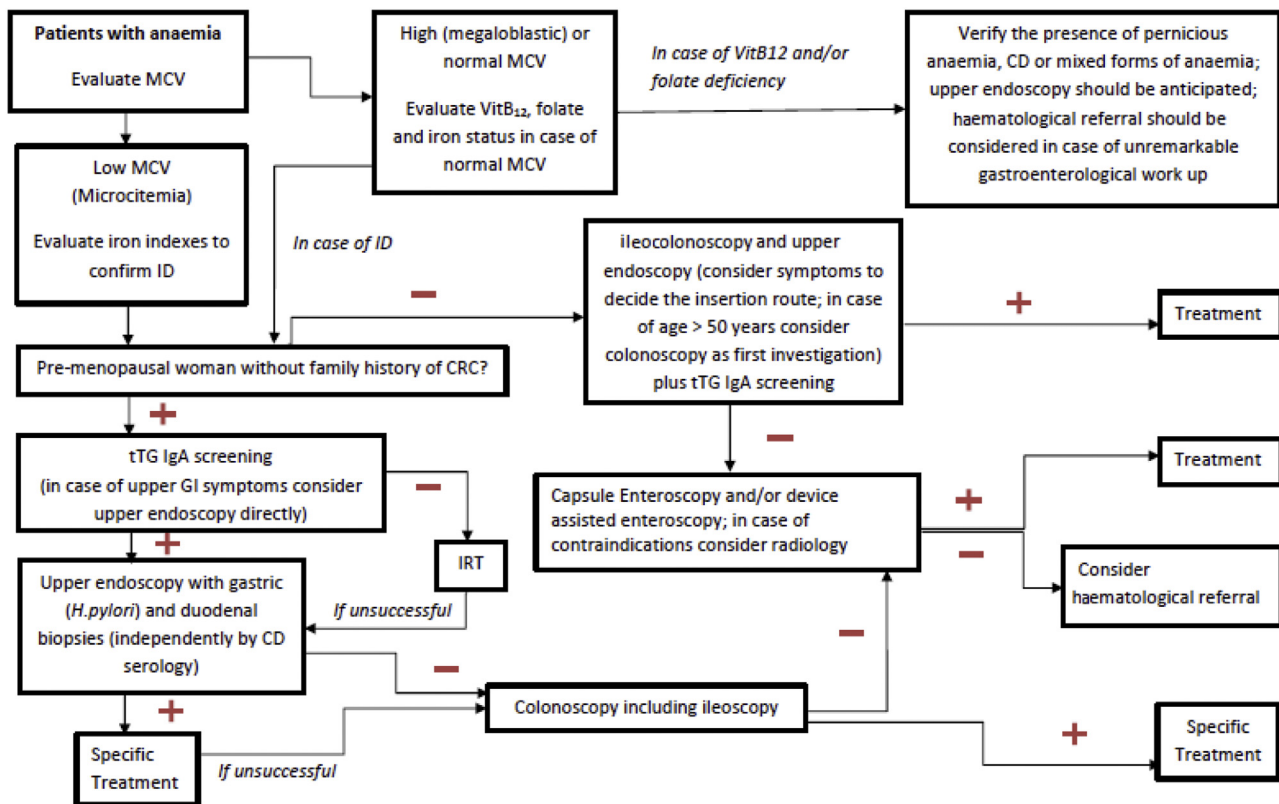


Fig. 1. Diagnostic gastroenterological flowchart for adult patients with anaemia.

assessment of the potential causes of megaloblastic anaemia. Typically, autoimmune atrophic gastritis, with or without intestinal metaplasia, is confined in the mucosa of the gastric body and fundus, sparing the antrum. It represents a precancerous condition for both neuroendocrine tumors and gastric cancer, thus deserving endoscopic-histologic follow up every 3–4 years [142,143].

In general, the absorption of Vitamin B12 requires the normal function of the stomach, pancreas and small intestine [144]. Other causes of its deficiency are manifold: dietary low intake (as in strict vegan diet), gastrectomy, pancreatic abnormalities (chronic pancreatitis, pancreatectomy), SB disease (ileal disease, CD or CrD) terminal ileal resection or bypass, bacterial overgrowth, fish tapeworm *i.e.* *Diphyllobothrium latum* [145]. Among the malabsorption causes of B₁₂ vitamin deficiency the most frequent one is pernicious anaemia [144]. In pernicious anaemia, Vitamin B12 deficiency is treated with intramuscular injection of hydroxocobalamin 1 mg three times a week for two weeks and then three-monthly for life to prevent neurological consequences related to chronic vitamin B₁₂ deficiency [146]. Patients with an unremarkable gastroenterological work-up should be referred to the haematologist to rule out myelofibrosis and other haematological causes (inherited disorders, transcobalamin II deficiency, intrinsic factor deficiency, cubilin deficiency, etc.) [145].

7.1. Panel recommendations

- Patients with megaloblastic anaemia should be investigated for autoimmune atrophic gastritis. When pernicious anaemia is diagnosed, long-life intramuscular supplementation of vitamin B12 is needed, as well as a scheduled endoscopic surveillance (strong recommendation, high level of evidence)

Vote result: strongly agree 86.7%, agree 6.7%, moderately agree 6.7%, moderately disagree 0%, disagree 0%, strongly disagree 0%

Table 2

Haemoglobin cut-off values for the definition of anaemia in children.

Age	Hemoglobin cut-off value (g/dl)
0–1 weeks	13.5
2 months	9
4–24 months	10.5
2–5 years	11
5–11 years	11.5
12–14 years	12

- Patients with megaloblastic anaemia without pernicious anaemia should be referred to the haematologist for further diagnostic work-up (strong recommendation, low level of evidence)

Vote result: strongly agree 60%, agree 33.3%, moderately agree 6.7%, moderately disagree 0%, disagree 0%, strongly disagree 0%

8. Approach to anaemic patients during childhood

Anaemia is a diagnostic challenge during childhood as well: a systematic review has shown that IDA is a frequent condition among pre-school children all over the world [147] with a prevalence of 9.6% (95% CI, 7.2–12.0). The normal values of Hb during childhood are reported in Table 2 [148]. Although GI diseases are well-known causes of refractory anaemia in children, the real prevalence is unclear because of the lack of systematic reviews and manuscripts investigating this specific issue. Evidence is available about the role of *H. pylori*, peptic diseases and IDA: a meta-analysis published in 2016 [78] has shown an important association (OR 2.2; 95% CI, 1.4–3.4) by analyzing four paediatric studies [149–152]. Following this meta-analysis, a population-based study was published [153], confirming the association between *H. pylori* and IDA (OR 1.7; 95% CI, 1.2–2.3). Two paediatric studies [154,155] evaluated the prevalence of CD in children with IDA, showing a 21.3% and

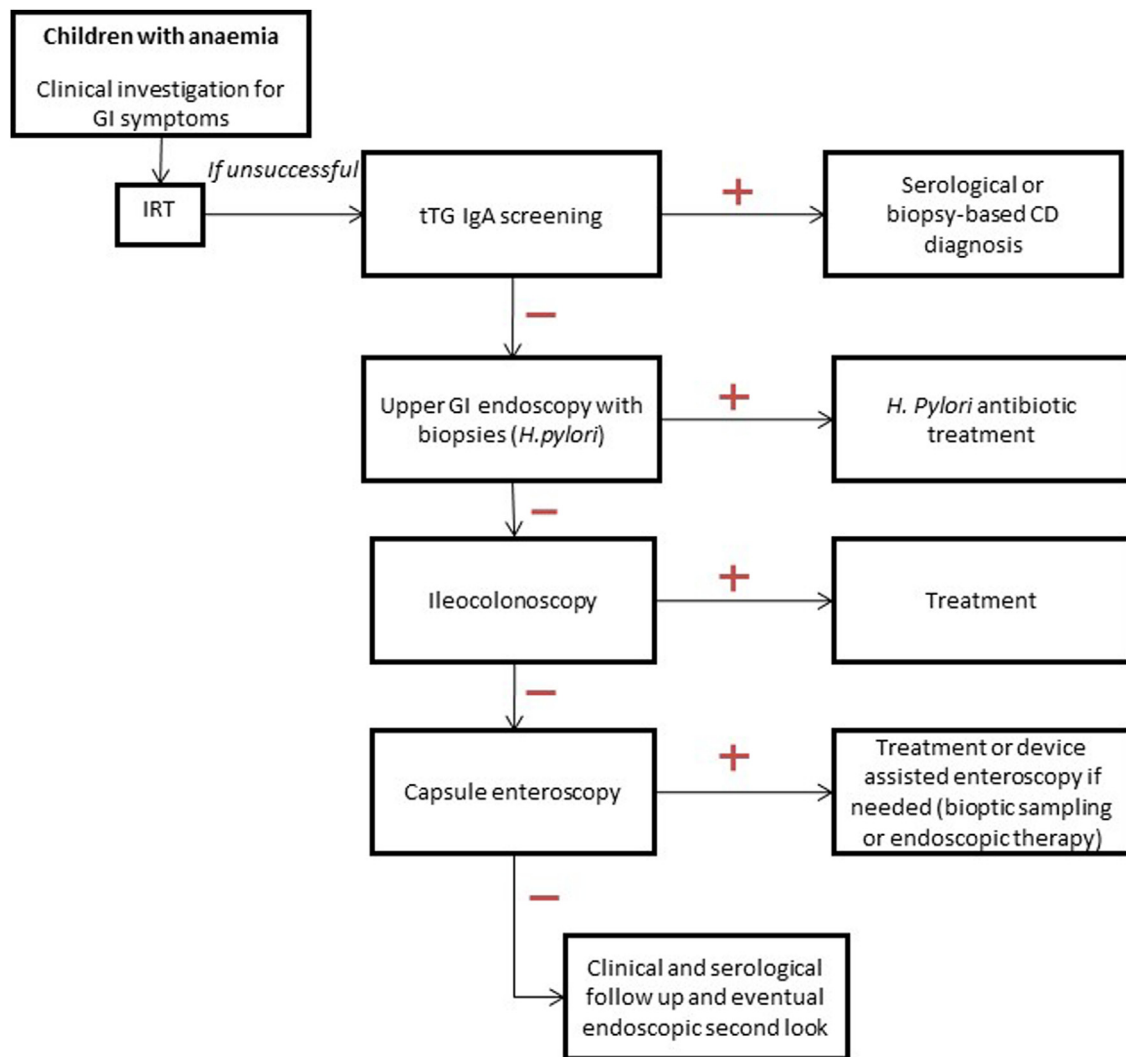


Fig. 2. Diagnostic gastroenterological flowchart for pediatric patients with anaemia.

8.4% prevalence, respectively, and demonstrated the need for CD screening in children with IDA. Although IDA is a common complication of IBD, this issue has never been investigated as the possible alarm symptom. In a large meta-analysis, IDA was described in 24% of adults with IBD [130]. Furthermore, three studies [156–158] suggested a high prevalence of IDA at diagnosis (74%, 30% and 61% respectively).

Other GI conditions to be possibly associated with chronic anaemia in children were only anecdotally reported. IDA can be caused by: gastric diseases, such as autoimmune gastritis [159,160] and collagenous gastritis [161,162], occult gastrointestinal bleeding due to post-surgical conditions (e.g. post anastomotic ulcerations) [163,164], vascular malformations [165,166] or blue rubber bleb nevus syndrome (BRBNS) [167,168]. Endoscopy is routinely performed to assess chronic refractory anaemia, but the evidence regarding children is scarce. Two studies [169,170] addressing the role of upper gastrointestinal endoscopy, showed a DY of 84% and 43%, respectively, in a small cohort of children with IDA. Lower GI endoscopy was not studied in that scenario.

OGIB and IDA are the most frequent clinical indications in children who underwent CE [171,172]. The DY of CE in this setting ranged from a 37% [173] to 53% [172], up to a 64% [174]. As to imaging, a study investigated the DY of MR in children with OGIB [175]: MR was performed on 13 children with a DY of 77%. Two studies on DAE in children have been published with OGIB being

the indication in 28% and 16%, respectively, of the cases considered, with a DY of 50% and 62%, respectively.

8.1. Panel recommendations

- Upper GI endoscopy should be considered for chronic refractory anaemia of unknown etiology in children (weak recommendation, low level of evidence).

Vote result: strongly agree 46.2%, agree 73.3%, moderately agree 46.2%, moderately disagree 0%, disagree 0%, strongly disagree 0%

- Lower GI endoscopy should be considered towards the diagnosis of chronic refractory anaemia (conditional recommendation, low level of evidence).

Vote result: strongly agree 46.2%, agree 23.1%, moderately agree 30.8%, moderately disagree 0%, disagree 0%, strongly disagree 0%

- In case of operative endoscopy CE and DAE should be performed on children with persistent anaemia and in case of inconclusive upper and lower endoscopy (conditional recommendation, low level of evidence).

Vote result: strongly agree 38.5%, agree 30.8%, moderately agree 30.8%, moderately disagree 0%, disagree 0%, strongly disagree 0%

- DAE can be indicated in the diagnostic and therapeutic approaches to chronic refractory anaemia after or together with CE findings (conditional recommendation, low level of evidence).

Vote result: strongly agree 23.1%, agree 46.2%, moderately agree 30.8%, moderately disagree 0%, disagree 0%, strongly disagree 0%

9. Final raccomandations

Anaemia always poses a diagnostic challenge as numerous are the GI diseases leading to a decrease in Hb levels. A correct diagnostic approach is essential to improve a patient's prognosis and to establish correct therapeutic and follow-up processes. In view of the importance of anaemia in the clinical routine, the current lack of studies investigating this issue is bemusing. Figs. 1 and 2 provide the diagnostic roadmaps to handle adults and children with anaemia.

Acknowledgments

We thank Marcello Hinxman-Allegri for the English language revision and editing of the manuscript.

Funding

None declared.

Fondazione IRCCS Ca' Granda was funded by grants from the Italian Ministry of Health and Lombardy's Regional Government Authority (Ministero della Salute e Regione Lombardia call no. R.F.GR 2011-02348234).

References

- [1] Beutler E, Waalen J. The definition of anemia: what is the lower limit of normal of the blood hemoglobin concentration. *Blood* 2006;107:1747–50.
- [2] Cappellini MD, Motta I. Anemia in clinical practice-Definition and classification: does hemoglobin change with aging. *Semin Hematol* 2015;52:261–9.
- [3] Goddard AF, James MW, McIntyre AS, Scott BB. Gastroenterology BSo Guidelines for the management of iron deficiency anaemia. *Gut* 2011;60:1309–16.
- [4] Buscarini E, Conte D, Cannizzaro R, Bazzoli F, De Boni M, Delle Fave G. White paper of Italian Gastroenterology: delivery of services for digestive diseases in Italy: weaknesses and strengths. *Dig Liver Dis* 2014;46:579–89.
- [5] Freeman HJ. Iron deficiency anemia in celiac disease. *World J Gastroenterol* 2015;21:9233–8.
- [6] Jackson CS, Strong R. Gastrointestinal angiodysplasia: diagnosis and management. *Gastrointest Endosc Clin N Am* 2017;27:51–62.
- [7] Peyrin-Biroulet L, Lopez A, Cummings JRF, Dignass A, Detlie TE, Danese S. Review article: treating-to-target for inflammatory bowel disease-associated anaemia. *Aliment Pharmacol Ther* 2018;48:610–7.
- [8] Bizzaro N, Antico A. Diagnosis and classification of pernicious anemia. *Autoimmun Rev* 2014;13:565–8.
- [9] Dignass AU, Gasche C, Bettenworth D, Birgegård G, Danese S, Gisbert JP, et al. European consensus on the diagnosis and management of iron deficiency and anaemia in inflammatory bowel diseases. *J Crohns Colitis* 2015;9:211–22.
- [10] Gasche C, Berstad A, Befrits R, Beglinger C, Dignass A, Erichsen K, et al. Guidelines on the diagnosis and management of iron deficiency and anemia in inflammatory bowel diseases. *Inflamm Bowel Dis* 2007;13:1545–53.
- [11] Goddard AF, McIntyre AS, Scott BB. Guidelines for the management of iron deficiency anaemia British Society of Gastroenterology. *Gut* 2000;46(Suppl 3-4):IV1–5.
- [12] Bergus GR, Randall CS, Sinift SD, Rosenthal DM. Does the structure of clinical questions affect the outcome of curbside consultations with specialty colleagues. *Arch Fam Med* 2000;9:541–7.
- [13] Atkins D, Best D, Briss PA, Eccles M, Falck-Ytter Y, Flottorp S, et al. Grading quality of evidence and strength of recommendations. *BMJ* 2004;328:1490.

- [14] Kassebaum NJ, Jasrasaria R, Naghavi M, Wulf SK, Johns N, Lozano R, et al. A systematic analysis of global anemia burden from 1990 to 2010. *Blood* 2014;123:615–24.
- [15] Taher AT, Weatherall DJ, Cappellini MD. Thalassemia. *Lancet* 2018;391:155–67.
- [16] Cappellini MD, Comin-Colet J, de Francisco A, Dignass A, Doehner W, Lam CS, et al. Iron deficiency across chronic inflammatory conditions: international expert opinion on definition, diagnosis, and management. *Am J Hematol* 2017;92:1068–78.
- [17] Green R, Dwyre DM. Evaluation of macrocytic anemias. *Semin Hematol* 2015;52:279–86.
- [18] Winawer S, Fletcher R, Rex D, Bond J, Burt R, Ferrucci J, et al. Colorectal cancer screening and surveillance: clinical guidelines and rationale-Update based on new evidence. *Gastroenterology* 2003;124:544–60.
- [19] Knudsen AB, Zauber AG, Rutter CM, Naber SK, Doria-Rose VP, Pabiniak C, et al. Estimation of benefits burden, and harms of colorectal cancer screening strategies: modeling study for the US preventive services task force. *JAMA* 2016;315:2595–609.
- [20] Fisher DA, Judd L, Sanford NS. Inappropriate colorectal cancer screening: findings and implications. *Am J Gastroenterol* 2005;100:2526–30.
- [21] Friedman A, Chan A, Chin LC, Deen A, Hammerschlag G, Lee M, et al. Use and abuse of faecal occult blood tests in an acute hospital inpatient setting. *Intern Med J* 2010;40:107–11.
- [22] Mosadeghi S, Ren H, Catungal J, Yen I, Liu B, Wong RJ, et al. Utilization of fecal occult blood test in the acute hospital setting and its impact on clinical management and outcomes. *J Postgrad Med* 2016;62:91–5.
- [23] Percy L, Mansour D, Fraser I. Iron deficiency and iron deficiency anaemia in women. *Best Pract Res Clin Obstet Gynaecol* 2017;40:55–67.
- [24] Kujovich JL. Evaluation of anemia. *Obstet Gynecol Clin North Am* 2016;43:247–64.
- [25] Carter D, Maor Y, Bar-Meir S, Avidan B. Prevalence and predictive signs for gastrointestinal lesions in premenopausal women with iron deficiency anemia. *Dig Dis Sci* 2008;53:3138–44.
- [26] Green BT, Rockey DC. Gastrointestinal endoscopic evaluation of premenopausal women with iron deficiency anemia. *J Clin Gastroenterol* 2004;38:104–9.
- [27] Park DI, Ryu SH, Oh SJ, Yoo TW, Kim HJ, Cho YK, et al. Significance of endoscopy in asymptomatic premenopausal women with iron deficiency anemia. *Dig Dis Sci* 2006;51:2372–6.
- [28] Ioannou GN, Rockey DC, Bryson CL, Weiss NS. Iron deficiency and gastrointestinal malignancy: a population-based cohort study. *Am J Med* 2002;113:276–80.
- [29] Short MW, Domagalski JE. Iron deficiency anemia: evaluation and management. *Am Fam Physician* 2013;87:98–104.
- [30] Liu K, Kaffes AJ. Iron deficiency anaemia: a review of diagnosis, investigation and management. *Eur J Gastroenterol Hepatol* 2012;24:109–16.
- [31] Castells A, Marzo M, Bellas B, Amador FJ, Lanás A, Mascort JJ, et al. [Clinical guidelines for the prevention of colorectal cancer]. *Gastroenterol Hepatol* 2004;27:573–634.
- [32] Rockey DC, Cello JP. Evaluation of the gastrointestinal tract in patients with iron-deficiency anemia. *N Engl J Med* 1993;329:1691–5.
- [33] Hardwick RH, Armstrong CP. Synchronous upper and lower gastrointestinal endoscopy is an effective method of investigating iron-deficiency anaemia. *Br J Surg* 1997;84:1725–8.
- [34] Gordon SR, Smith RE, Power GC. The role of endoscopy in the evaluation of iron deficiency anemia in patients over the age of 50. *Am J Gastroenterol* 1994;89:1963–7.
- [35] Tee HP, Kaffes AJ. Non-small-bowel lesions encountered during double-balloon enteroscopy performed for obscure gastrointestinal bleeding. *World J Gastroenterol* 2010;16:1885–9.
- [36] Stray N, Weberg R. A prospective study of same day bi-directional endoscopy in the evaluation of patients with occult gastrointestinal bleeding. *Scand J Gastroenterol* 2006;41:844–50.
- [37] Hershko C, Hoffbrand AV, Keret D, Souroujon M, Maschler I, Monselise Y, et al. Role of autoimmune gastritis Helicobacter pylori and celiac disease in refractory or unexplained iron deficiency anemia. *Haematologica* 2005;90:585–95.
- [38] Dickey W, McMillan SA, McCrum EE, Evans AE. Association between serum levels of total IgA and IgA class endomysial and anti gliadin antibodies: implications for coeliac disease screening. *Eur J Gastroenterol Hepatol* 1997;9:559–62.
- [39] Capurso G, Baccini F, Osborn J, Panzuto F, Di Giulio E, Delle Fave G, et al. Can patient characteristics predict the outcome of endoscopic evaluation of iron deficiency anemia: a multiple logistic regression analysis. *Gastrointest Endosc* 2004;59:766–71.
- [40] McIntyre AS, Long RG. Prospective survey of investigations in outpatients referred with iron deficiency anaemia. *Gut* 1993;34:1102–7.
- [41] Rockey DC. Occult gastrointestinal bleeding. *N Engl J Med* 1999;341:38–46.
- [42] Powell N, McNair A. Gastrointestinal evaluation of anaemic patients without evidence of iron deficiency. *Eur J Gastroenterol Hepatol* 2008;20:1094–100.
- [43] Sawhney MS, Lipato T, Nelson DB, Lederle FA, Rector TS, Bond JH. Should patients with anemia and low normal or normal serum ferritin undergo colonoscopy? *Am J Gastroenterol* 2007;102:82–8.
- [44] Wang SA, Fadare O, Nagar A, Shafi NQ, Rose MG. Gastrointestinal endoscopic findings in men with unexplained anemia and low normal ferritin values. *Am J Hematol* 2006;81:324–7.

- [45] Moses PL, Smith RE. Endoscopic evaluation of iron deficiency anemia. A guide to diagnostic strategy in older patients. *Postgrad Med* 1995;98:213–6, 9, 22–4 passim.
- [46] Zuckerman GR, Prakash C, Askin MP, Lewis BS. AGA technical review on the evaluation and management of occult and obscure gastrointestinal bleeding. *Gastroenterology* 2000;118:201–21.
- [47] Peytremann-Bridevaux I, Arditi C, Froehlich F, O'Malley J, Fairclough P, Le Moine O, et al. Appropriateness of colonoscopy in europe (EPAGE II). Iron-deficiency anemia and hematochezia. *Endoscopy* 2009;41:227–33.
- [48] Carter D, Levi G, Tzur D, Novis B, Avidan B. Prevalence and predictive factors for gastrointestinal pathology in young men evaluated for iron deficiency anemia. *Dig Dis Sci* 2013;58:1299–305.
- [49] Rockey DC. Occult and obscure gastrointestinal bleeding: causes and clinical management. *Nat Rev Gastroenterol Hepatol* 2010;7:265–79.
- [50] Landy J, Macfarlane B. Synchronous bidirectional endoscopy for iron deficiency anaemia: is it appropriate for patients under 50? *Postgrad Med J* 2010;86:338–40.
- [51] Kim NH, Park JH, Park DI, Sohn CI, Choi K, Jung YS. Should asymptomatic young men with iron deficiency anemia necessarily undergo endoscopy? *Korean J Intern Med* 2018.
- [52] Saks K, Enestvedt BK, Holub JL, Lieberman D. Colonoscopy identifies increased prevalence of large polyps or tumors in patients 40–49 years old with hematochezia vs other gastrointestinal indications. *Clin Gastroenterol Hepatol* 2016;14:843–9.
- [53] Pennazio M, Spada C, Eliakim R, Keuchel M, May A, Mulder CJ, et al. Small-bowel capsule endoscopy and device-assisted enteroscopy for diagnosis and treatment of small-bowel disorders: european Society of Gastrointestinal Endoscopy (ESGE) Clinical Guideline. *Endoscopy* 2015;47:352–76.
- [54] Rondonotti E, Spada C, Adler S, May A, Despott EJ, Koulaouzidis A, et al. Small-bowel capsule endoscopy and device-assisted enteroscopy for diagnosis and treatment of small-bowel disorders: european Society of Gastrointestinal Endoscopy (ESGE) Technical Review. *Endoscopy* 2018;50:423–46.
- [55] Gerson LB, Fidler JL, Cave DR, Leighton JA. ACG clinical guideline: diagnosis and management of small bowel bleeding. *Am J Gastroenterol* 2015;110:1265–87, quiz 88.
- [56] Gurudu SR, Bruining DH, Acosta RD, Eloubeidi MA, Faulx AL, Khashab MA, et al. The role of endoscopy in the management of suspected small-bowel bleeding. *Gastrointest Endosc* 2017;85:22–31.
- [57] Enns RA, Hookey L, Armstrong D, Bernstein CN, Heitman SJ, Teshima C, et al. Clinical practice guidelines for the use of video capsule endoscopy. *Gastroenterology* 2017;152:497–514.
- [58] Koulaouzidis A, Rondonotti E, Giannakou A, Plevris JN. Diagnostic yield of small-bowel capsule endoscopy in patients with iron-deficiency anemia: a systematic review. *Gastrointest Endosc* 2012;76:983–92.
- [59] Yung DE, Rondonotti E, Giannakou A, Avni T, Rosa B, Toth E, et al. Capsule endoscopy in young patients with iron deficiency anaemia and negative bidirectional gastrointestinal endoscopy. *United European Gastroenterol J* 2017;5:974–81.
- [60] Teshima CW, Kuipers EJ, van Zanten SV, Mensink PB. Double balloon enteroscopy and capsule endoscopy for obscure gastrointestinal bleeding: an updated meta-analysis. *J Gastroenterol Hepatol* 2011;26:796–801.
- [61] Gerson L, Kamal A. Cost-effectiveness analysis of management strategies for obscure GI bleeding. *Gastrointest Endosc* 2008;68:920–36.
- [62] Tziatzios G, Gkolfakis P, Hassan C, Toth E, Zullo A, Koulaouzidis A, et al. Meta-analysis shows similar re-bleeding rates among Western and Eastern populations after index video capsule endoscopy. *Dig Liver Dis* 2018;50:226–39.
- [63] Huprich JE, Fletcher JG, Fidler JL, Alexander JA, Guimarães LS, Siddiki HA, et al. Prospective blinded comparison of wireless capsule endoscopy and multiphase CT enterography in obscure gastrointestinal bleeding. *Radiology* 2011;260:744–51.
- [64] Khalife S, Soyer P, Alatawi A, Vahedi K, Hamzi L, Dray X, et al. Obscure gastrointestinal bleeding: preliminary comparison of 64-section CT enteroclysis with video capsule endoscopy. *Eur Radiol* 2011;21:79–86.
- [65] Milano A, Balatsinou C, Filippone A, Caldarella MP, Laterza F, Lapenna D, et al. A prospective evaluation of iron deficiency anemia in the GI endoscopy setting: role of standard endoscopy, videocapsule endoscopy, and CT-enteroclysis. *Gastrointest Endosc* 2011;73:1002–8.
- [66] Lee SS, Oh TS, Kim HJ, Chung JW, Park SH, Kim AY, et al. Obscure gastrointestinal bleeding: diagnostic performance of multidetector CT enterography. *Radiology* 2011;259:739–48.
- [67] Jain TP, Gulati MS, Makharia GK, Bandhu S, Garg PK. CT enteroclysis in the diagnosis of obscure gastrointestinal bleeding: initial results. *Clin Radiol* 2007;62:660–7.
- [68] Law R, Varayil JE, WongKeeSong LM, Fidler J, Fletcher JG, Barlow J, et al. Assessment of multi-modality evaluations of obscure gastrointestinal bleeding. *World J Gastroenterol* 2017;23:614–21.
- [69] He B, Gong S, Hu C, Fan J, Qian J, Huang S, et al. Obscure gastrointestinal bleeding: diagnostic performance of 64-section multiphase CT enterography and CT angiography compared with capsule endoscopy. *Br J Radiol* 2014;87:20140229.
- [70] Gong PY, Li JX, Huang LY, Zhang LM, Xie HZ, Sui YB. Prospective blinded comparison of computed tomographic enterography and small bowel endoscopy in obscure gastrointestinal bleeding. *Hepatogastroenterology* 2014;61:984–8.
- [71] Cengic I, Tureli D, Aydin H, Bugdayci O, Imeryuz N, Tuney D. Magnetic resonance enterography in refractory iron deficiency anemia: a pictorial overview. *World J Gastroenterol* 2014;20:14004–9.
- [72] Böcker U, Dinter D, Litterer C, Hummel F, Knebel P, Franke A, et al. Comparison of magnetic resonance imaging and video capsule endoscopy in diagnosing small-bowel pathology: localization-dependent diagnostic yield. *Scand J Gastroenterol* 2010;45:490–500.
- [73] Wiarda BM, Heine DG, Mensink P, Stolk M, Dees J, Hazenberg HJ, et al. Comparison of magnetic resonance enteroclysis and capsule endoscopy with balloon-assisted enteroscopy in patients with obscure gastrointestinal bleeding. *Endoscopy* 2012;44:668–73.
- [74] Stein J, Connor S, Virgin G, Ong DE, Pereyra L. Anemia and iron deficiency in gastrointestinal and liver conditions. *World J Gastroenterol* 2016;22:7908–25.
- [75] Schwarz P, Kübler JA, Strnad P, Müller K, Barth TF, Gerloff A, et al. Hepcidin is localised in gastric parietal cells, regulates acid secretion and is induced by *Helicobacter pylori* infection. *Gut* 2012;61:193–201.
- [76] Sapmaz F, Başıyigit S, Kalkan I, Kisa U, Kavak EE, Güllüer S. The impact of *Helicobacter pylori* eradication on serum hepcidin-25 level and iron parameters in patients with iron deficiency anemia. *Wien Klin Wochenschr* 2016;128:335–40.
- [77] He X, Liao X, Li H, Xia W, Sun H. Bismuth-Induced inactivation of ferric uptake regulator from *Helicobacter pylori*. *Inorg Chem* 2017;56:15041–8.
- [78] Hudak L, Jaraisa A, Haj S, Muhsen K. An updated systematic review and meta-analysis on the association between *Helicobacter pylori* infection and iron deficiency anemia. *Helicobacter* 2017;22.
- [79] Yuan W, Yumin Li, Kehu Yang, Bin Ma, Quanlin Guan, Wang D, et al. Iron deficiency anemia in *Helicobacter pylori* infection: meta-analysis of randomized controlled trials. *Scand J Gastroenterol* 2010;45:665–76.
- [80] Huang X, Qu X, Yan W, Huang Y, Cai M, Hu B, et al. Iron deficiency anaemia can be improved after eradication of *Helicobacter pylori*. *Postgrad Med J* 2010;86:272–8.
- [81] Qu XH, Huang XL, Xiong P, Zhu CY, Huang YL, Lu LG, et al. Does *Helicobacter pylori* infection play a role in iron deficiency anemia? A meta-analysis. *World J Gastroenterol* 2010;16:886–96.
- [82] Annibale B, Marignani M, Monarca B, Antonelli G, Marcheggiano A, Martino G, et al. Reversal of iron deficiency anemia after *Helicobacter pylori* eradication in patients with asymptomatic gastritis. *Ann Intern Med* 1999;131:668–72.
- [83] Hershko C, Ianculovich M, Sourouj M. A hematologist's view of unexplained iron deficiency anemia in males: impact of *Helicobacter pylori* eradication. *Blood Cells Mol Dis* 2007;38:45–53.
- [84] Monzón H, Forné M, Esteve M, Rosinach M, Loras C, Espinós JC, et al. *Helicobacter pylori* infection as a cause of iron deficiency anaemia of unknown origin. *World J Gastroenterol* 2013;19:4166–71.
- [85] Unsworth DJ, Lock FJ, Harvey RF. Iron-deficiency anaemia in premenopausal women. *Lancet* 1999;353:1100.
- [86] Volta U, Caio G, Stanghellini V, De Giorgio R. The changing clinical profile of celiac disease: a 15-year experience (1998–2012) in an Italian referral center. *BMC Gastroenterol* 2014;14:194.
- [87] Wierdsma NJ, van Bokhorst-de van der Schueren MA, Berkenpas M, Mulder CJ, van Bodegraven AA. Vitamin and mineral deficiencies are highly prevalent in newly diagnosed celiac disease patients. *Nutrients* 2013;5:3975–92.
- [88] Bottaro G, Cataldo F, Rotolo N, Spina M, Corazza GR. The clinical pattern of subclinical/silent celiac disease: an analysis on 1026 consecutive cases. *Am J Gastroenterol* 1999;94:691–6.
- [89] Lo W, Sano K, Lebwahl B, Diamond B, Green PH. Changing presentation of adult celiac disease. *Dig Dis Sci* 2003;48:395–8.
- [90] Kolho KL, Färkkilä MA, Savilahti E. Undiagnosed coeliac disease is common in Finnish adults. *Scand J Gastroenterol* 1998;33:1280–3.
- [91] Hin H, Bird G, Fisher P, Mahy N, Jewell D. Coeliac disease in primary care: case finding study. *BMJ* 1999;318:164–7.
- [92] Howard MR, Turnbull AJ, Morley P, Hollier P, Webb R, Clarke A. A prospective study of the prevalence of undiagnosed coeliac disease in laboratory defined iron and folate deficiency. *J Clin Pathol* 2002;55:754–7.
- [93] Çekin AH, Çekin Y, Sezer C. Celiac disease prevalence in patients with iron deficiency anemia. *Turk J Gastroenterol* 2012;23:490–5.
- [94] Dubé C, Rostom A, Sy R, Cranney A, Saloojee N, Garrity C, et al. The prevalence of celiac disease in average-risk and at-risk Western European populations: a systematic review. *Gastroenterology* 2005;128:S57–67.
- [95] Ackerman Z, Eliakim R, Stalnikowicz R, Rachmilewitz D. Role of small bowel biopsy in the endoscopic evaluation of adults with iron deficiency anemia. *Am J Gastroenterol* 1996;91:2099–102.
- [96] Annibale B, Capurso G, Chistolini A, D'Ambrà G, DiGiulio E, Monarca B, et al. Gastrointestinal causes of refractory iron deficiency anemia in patients without gastrointestinal symptoms. *Am J Med* 2001;111:439–45.
- [97] Corazza GR, Valentini RA, Andreani ML, D'Anchino M, Leva MT, Ginaldi L, et al. Subclinical coeliac disease is a frequent cause of iron-deficiency anaemia. *Scand J Gastroenterol* 1995;30:153–6.
- [98] Dickey W, Kenny BD, McMillan SA, Porter KG, McConnell JB. Gastric as well as duodenal biopsies may be useful in the investigation of iron deficiency anaemia. *Scand J Gastroenterol* 1997;32:469–72.
- [99] Kepczyk T, Kadakia SC. Prospective evaluation of gastrointestinal tract in patients with iron-deficiency anemia. *Dig Dis Sci* 1995;40:1283–9.
- [100] Oxentenko AS, Grisolan SW, Murray JA, Burgart LJ, Dierkhising RA, Alexander JA. The insensitivity of endoscopic markers in celiac disease. *Am J Gastroenterol* 2002;97:933–8.

- [101] Ransford RA, Hayes M, Palmer M, Hall MJ. A controlled, prospective screening study of celiac disease presenting as iron deficiency anemia. *J Clin Gastroenterol* 2002;35:228–33.
- [102] Unsworth DJ, Lock RJ, Harvey RF. Improving the diagnosis of coeliac disease in anaemic women. *Br J Haematol* 2000;111:898–901.
- [103] Annibale B, Lahner E, Chistolini A, Gaiulluci C, Di Giulio E, Capurso G, et al. Endoscopic evaluation of the upper gastrointestinal tract is worthwhile in premenopausal women with iron-deficiency anaemia irrespective of menstrual flow. *Scand J Gastroenterol* 2003;38:239–45.
- [104] van Mook WN, Bouras-Bremers IH, Bos LP, Verhoeven HM, Engels LG. The outcome of esophagogastroduodenoscopy (EGD) in asymptomatic outpatients with iron deficiency anemia after a negative colonoscopy. *Eur J Intern Med* 2001;12:122–6.
- [105] Fernández-Bañares F, Monzón H, Forné M. A short review of malabsorption and anemia. *World J Gastroenterol* 2009;15:4644–52.
- [106] Carroccio A, Iannitto E, Cavataio F, Montalto G, Tumminello M, Campagna P, et al. Sideropenic anemia and celiac disease: one study, two points of view. *Dig Dis Sci* 1998;43:673–8.
- [107] Haslam N, Lock RJ, Unsworth DJ. Coeliac disease, anaemia and pregnancy. *Clin Lab* 2001;47:467–9.
- [108] Annibale B, Severi C, Chistolini A, Antonelli G, Lahner E, Marcheggiano A, et al. Efficacy of gluten-free diet alone on recovery from iron deficiency anemia in adult celiac patients. *Am J Gastroenterol* 2001;96:132–7.
- [109] Grisolano SW, Oxentenko AS, Murray JA, Burgart LJ, Dierkhising RA, Alexander JA. The usefulness of routine small bowel biopsies in evaluation of iron deficiency anemia. *J Clin Gastroenterol* 2004;38:756–60.
- [110] Mandal AK, Mehdi I, Munshi SK, Lo TC. Value of routine duodenal biopsy in diagnosing coeliac disease in patients with iron deficiency anaemia. *Postgrad Med J* 2004;80:475–7.
- [111] Kalayci AG, Kanber Y, Birinci A, Yildiz L, Albayrak D. The prevalence of coeliac disease as detected by screening in children with iron deficiency anaemia. *Acta Paediatr* 2005;94:678–81.
- [112] Zamani F, Mohamadnejad M, Shakeri R, Amiri A, Najafi S, Alimohamadi SM, et al. Gluten sensitive enteropathy in patients with iron deficiency anemia of unknown origin. *World J Gastroenterol* 2008;14:7381–5.
- [113] Ludvigsson JF, Bai JC, Biagi F, Card TR, Ciacci C, Ciclitira PJ, et al. Diagnosis and management of adult coeliac disease: guidelines from the British Society of Gastroenterology. *Gut* 2014;63:1210–28.
- [114] Rubio-Tapia A, Hill ID, Kelly CP, Calderwood AH, Murray JA. ACG clinical guidelines: diagnosis and management of celiac disease. *Am J Gastroenterol* 2013;108:656–76, quiz 77.
- [115] McGowan KE, Lyon ME, Butzner JD. Celiac disease and IgA deficiency: complications of serological testing approaches encountered in the clinic. *Clin Chem* 2008;54:1203–9.
- [116] Volta U, Caio G, Boschetti E, Giancola F, Rhoden KJ, Ruggeri E, et al. Seronegative celiac disease: shedding light on an obscure clinical entity. *Dig Liver Dis* 2016;48:1018–22.
- [117] Rubio-Tapia A, Hill ID, Kelly CP, Calderwood AH, Murray JA. Gastroenterology ACo ACG clinical guidelines: diagnosis and management of celiac disease. *Am J Gastroenterol* 2013;108:656–76, quiz 77.
- [118] Aspuru K, Villa C, Bermejo F, Herrero P, López SG. Optimal management of iron deficiency anemia due to poor dietary intake. *Int J Gen Med* 2011;4:741–50.
- [119] Martin J, Geisel T, Maresch C, Krieger K, Stein J. Inadequate nutrient intake in patients with celiac disease: results from a German dietary survey. *Digestion* 2013;87:240–6.
- [120] Elli L, Poggiali E, Tomba C, Andreozzi F, Nava I, Bardella MT, et al. Does TMPRSS6 R5855791 polymorphism contribute to iron deficiency in treated celiac disease? *Am J Gastroenterol* 2015;110:200–2.
- [121] Bodé S, Gudmand-Høyer E. Symptoms and haematologic features in consecutive adult coeliac patients. *Scand J Gastroenterol* 1996;31:54–60.
- [122] Pittschieler K. Folic acid concentration in the serum and erythrocytes of patients with celiac disease. *Pediatr Padol* 1986;21:363–6.
- [123] Dahele A, Ghosh S. Vitamin B12 deficiency in untreated celiac disease. *Am J Gastroenterol* 2001;96:745–50.
- [124] Dickey W. Low serum vitamin B12 is common in coeliac disease and is not due to autoimmune gastritis. *Eur J Gastroenterol Hepatol* 2002;14:425–7.
- [125] Harper JW, Holleran SF, Ramakrishnan R, Bhagat G, Green PH. Anemia in celiac disease is multifactorial in etiology. *Am J Hematol* 2007;82:996–1000.
- [126] Ryan BM, Kelleher D. Refractory celiac disease. *Gastroenterology* 2000;119:243–51.
- [127] Elli L, Casazza G, Locatelli M, Branchi F, Ferretti F, Conte D, et al. Use of enteroscopy for the detection of malignant and premalignant lesions of the small bowel in complicated celiac disease: a meta-analysis. *Gastrointest Endosc* 2017;86:264–73, e1.
- [128] Heeney MM, Finberg KE. Iron-refractory iron deficiency anemia (IRIDA). *Hematol Oncol Clin North Am* 2014;28:637–52.
- [129] Gasche C, Lomer MC, Cavill I, Weiss G. Iron anaemia, and inflammatory bowel diseases. *Gut* 2004;53:1190–7.
- [130] Filmann N, Rey J, Schneeweiss S, Ardizzone S, Bager P, Bergamaschi G, et al. Prevalence of anemia in inflammatory bowel diseases in European countries: a systematic review and individual patient data meta-analysis. *Inflamm Bowel Dis* 2014;20:936–45.
- [131] Akhemonkhan E, Parian A, Miller K, Hanauer S, Hutfless S. Prevalence and screening for anaemia in mild to moderate Crohn's disease and ulcerative colitis in the United States, 2010–2014. *BMJ Open Gastroenterol* 2017;4:e000155.
- [132] Høivik ML, Reinisch W, Cvancarova M, Moum B. Anaemia in inflammatory bowel disease: a population-based 10-year follow-up. *Aliment Pharmacol Ther* 2014;39:69–76.
- [133] Lee TW, Kolber MR, Fedorak RN, van Zanten SV. Iron replacement therapy in inflammatory bowel disease patients with iron deficiency anemia: a systematic review and meta-analysis. *J Crohns Colitis* 2012;6:267–75.
- [134] Avni T, Bieber A, Steinmetz T, Leibovici L, Gafter-Gvili A. Treatment of anemia in inflammatory bowel disease—systematic review and meta-analysis. *PLoS One* 2013;8:e75540.
- [135] Abhyankar A, Moss AC. Iron replacement in patients with inflammatory bowel disease: a systematic review and meta-analysis. *Inflamm Bowel Dis* 2015;21:1976–81.
- [136] Bonovas S, Fiorino G, Allocchio M, Lytras T, Nikolopoulos GK, Peyrin-Biroulet L, et al. Biologic therapies and risk of infection and malignancy in patients with inflammatory bowel disease: a systematic review and network meta-analysis. *Clin Gastroenterol Hepatol* 2016;14:1385–97, e10.
- [137] Aksan A, Işık H, Radeke HH, Dignass A, Stein J. Systematic review with network meta-analysis: comparative efficacy and tolerability of different intravenous iron formulations for the treatment of iron deficiency anaemia in patients with inflammatory bowel disease. *Aliment Pharmacol Ther* 2017;45:1303–17.
- [138] Nielsen OH, Ainsworth M, Coskun M, Weiss G. Management of iron-Deficiency anemia in inflammatory bowel disease: a systematic review. *Medicine (Baltimore)* 2015;94:e963.
- [139] Lee T, Clavel T, Smirnov K, Schmidt A, Lagkouvardos I, Walker A, et al. Oral versus intravenous iron replacement therapy distinctly alters the gut microbiota and metabolome in patients with IBD. *Gut* 2017;66:863–71.
- [140] Khan S, Del-Duca C, Fenton E, Holding S, Hirst J, Doré PC, et al. Limited value of testing for intrinsic factor antibodies with negative gastric parietal cell antibodies in pernicious anaemia. *J Clin Pathol* 2009;62:439–41.
- [141] De Re V, Orzes E, Canzonieri V, Maiero S, Fornasari M, Alessandrini L, et al. Pepsinogens to distinguish patients with gastric intestinal metaplasia and helicobacter pylori infection among populations at risk for gastric cancer. *Clin Transl Gastroenterol* 2016;7:e183.
- [142] Dinis-Ribeiro M, Areia M, de Vries AC, Marcos-Pinto R, Monteiro-Soares M, O'Connor A, et al. Management of precancerous conditions and lesions in the stomach (MAPS): guideline from the European society of gastrointestinal endoscopy (ESGE), European Helicobacter Study Group (EHSG) European Society of Pathology (ESP), and the Sociedade Portuguesa de Endoscopia Digestiva (SPED). *Endoscopy* 2012;44:74–94.
- [143] Lahner E, Hassan C, Esposito G, Carabotti M, Zullo A, Dinis-Ribeiro M, et al. Cost of detecting gastric neoplasia by surveillance endoscopy in atrophic gastritis in Italy: a low risk country. *Dig Liver Dis* 2017;49:291–6.
- [144] Lahner E, Annibale B. Pernicious anemia: new insights from a gastroenterological point of view. *World J Gastroenterol* 2009;15:5121–8.
- [145] Shipton MJ, Thachil J. Vitamin B12 deficiency – a 21st century perspective. *Clin Med (Lond)* 2015;15:145–50.
- [146] Minalyan A, Benhammou JN, Artashesyan A, Lewis MS, Pisegna JR. Autoimmune atrophic gastritis: current perspectives. *Clin Exp Gastroenterol* 2017;10:19–27.
- [147] Petry N, Olofin I, Hurrell RF, Boy E, Wirth JP, Moursi M, et al. The proportion of anemia associated with iron deficiency in low medium, and high human development index countries: a systematic analysis of national surveys. *Nutrients* 2016;8.
- [148] Domellöf M, Braegger C, Campoy C, Colomb V, Decsi T, Fewtrell M, et al. Iron requirements of infants and toddlers. *J Pediatr Gastroenterol Nutr* 2014;58:119–29.
- [149] Baggott HC, Parkinson AJ, Muth PT, Gold BD, Gessner BD. Endemic iron deficiency associated with Helicobacter pylori infection among school-aged children in Alaska. *Pediatrics* 2006;117:e396–404.
- [150] Cherian S, Forbes D, Sanfilippo F, Cook A, Burgner D. The epidemiology of Helicobacter pylori infection in African refugee children resettled in Australia. *Med J Aust* 2008;189:438–41.
- [151] Choe YH, Kwon YS, Jung MK, Kang SK, Hwang TS, Hong YC. Helicobacter pylori-associated iron-deficiency anemia in adolescent female athletes. *J Pediatr* 2001;139:100–4.
- [152] Xia W, Zhang X, Wang J, Sun C, Wu L. Survey of anaemia and Helicobacter pylori infection in adolescent girls in Suihua, China and enhancement of iron intervention effects by H. pylori eradication. *Br J Nutr* 2012;108:357–62.
- [153] Taye B, Enquesselassie F, Tsegaye A, Amberbir A, Medhin G, Fogarty A, et al. Effect of early and current Helicobacter pylori infection on the risk of anaemia in 6.5-year-old Ethiopian children. *BMC Infect Dis* 2015;15:270.
- [154] Ertekin V, Tozun MS, Küçük N. The prevalence of celiac disease in children with iron-deficiency anemia. *Turk J Gastroenterol* 2013;24:334–8.
- [155] Karaman K, Akbayram S, Kar S, Demirören K. Prevalence of celiac disease in children with iron deficiency anemia in van lake region of Turkey. *J Pediatr Hematol Oncol* 2016;38:143–6.
- [156] Wiskin AE, Fleming BJ, Wootton SA, Beattie RM. Anaemia and iron deficiency in children with inflammatory bowel disease. *J Crohns Colitis* 2012;6:687–91.
- [157] Sjöberg D, Holmström T, Larsson M, Nielsen AL, Holmquist L, Rönnblom A. Anemia in a population-based IBD cohort (ICURE): still high prevalence after 10 years, especially among pediatric patients. *Inflamm Bowel Dis* 2014;20:2266–70.
- [158] Gonçalves C, Oliveira ME, Palha AM, Ferrão A, Morais A, Lopes AI. Autoimmune gastritis presenting as iron deficiency anemia in childhood. *World J Gastroenterol* 2014;20:15780–6.

- [159] Miguel N, Costa E, Santalha M, Lima R, Vizcaino JR, Pereira F, et al. Refractory iron-deficiency anemia and autoimmune atrophic gastritis in pediatric age group: analysis of 8 clinical cases. *J Pediatr Hematol Oncol* 2014;36:134–9.
- [160] Pogoriler J, Kamin D, Goldsmith JD. Pediatric non-*Helicobacter pylori* atrophic gastritis: a case series. *Am J Surg Pathol* 2015;39:786–92.
- [161] Hijaz NM, Septer SS, Degaetano J, Attard TM. Clinical outcome of pediatric collagenous gastritis: case series and review of literature. *World J Gastroenterol* 2013;19:1478–84.
- [162] Ma C, Park JY, Montgomery EA, Arnold CA, McDonald OG, Liu TC, et al. A comparative clinicopathologic study of collagenous gastritis in children and adults: the same disorder with associated immune-mediated diseases. *Am J Surg Pathol* 2015;39:802–12.
- [163] Charbit-Henrion F, Chardot C, Ruemmele F, Talbotec C, Morali A, Goulet O, et al. Anastomotic ulcerations after intestinal resection in infancy. *J Pediatr Gastroenterol Nutr* 2014;59:531–6.
- [164] Gibbons TE, Casteel HB, Vaughan JF, Dassinger MS. Staple line ulcers: a cause of chronic GI bleeding following STEP procedure. *J Pediatr Surg* 2013;48:E1–3.
- [165] Kalmar PI, Petnehazy T, Wießpeiner U, Beer M, Hauer AC, Till H, et al. Large, segmental, circular vascular malformation of the small intestine (in a female toddler with hematochezia): unusual presentation in a child. *BMC Pediatr* 2014;14:55.
- [166] Kim SH, Cho YH, Kim HY. Vascular malformations of the small intestine manifesting as chronic anemia: two pediatric cases managed by single-site umbilical laparoscopic surgery. *Int J Surg Case Rep* 2017;31:233–6.
- [167] Agnese M, Cipolletta L, Bianco MA, Quitadamo P, Miele E, Staiano A. Blue rubber bleb nevus syndrome. *Acta Paediatr* 2010;99:632–5.
- [168] Srinivasan P, Brandler M, D'Souza A, Millman P, Moreau H. Allergic enterocolitis presenting as recurrent necrotizing enterocolitis in preterm neonates. *J Perinatol* 2010;30:431–3.
- [169] Fayed SB, Aref MI, Fathy HM, Abd El Dayem SM, Emara NA, Maklof A, et al. Prevalence of celiac disease, *Helicobacter pylori* and gastroesophageal reflux in patients with refractory iron deficiency anemia. *J Trop Pediatr* 2008;54:43–53.
- [170] Gulen H, Kasirga E, Yildirim SA, Kader S, Sahin G, Ayhan S. Diagnostic yield of upper gastrointestinal endoscopy in the evaluation of iron deficiency anemia in older children and adolescents. *Pediatr Hematol Oncol* 2011;28:694–701.
- [171] Cohen SA, Klevens AI. Use of capsule endoscopy in diagnosis and management of pediatric patients, based on meta-analysis. *Clin Gastroenterol Hepatol* 2011;9:490–6.
- [172] Fritscher-Ravens A, Scherbakov P, Bufler P, Torroni F, Ruuska T, Nuutinen H, et al. The feasibility of wireless capsule endoscopy in detecting small intestinal pathology in children under the age of 8 years: a multicentre European study. *Gut* 2009;58:1467–72.
- [173] Cohen SA, Ephrath H, Lewis JD, Klevens A, Bergwerk A, Liu S, et al. Pediatric capsule endoscopy: review of the small bowel and patency capsules. *J Pediatr Gastroenterol Nutr* 2012;54:409–13.
- [174] Oliva S, Pennazio M, Cohen SA, Aloï M, Barabino A, Hassan C, et al. Capsule endoscopy followed by single balloon enteroscopy in children with obscure gastrointestinal bleeding: a combined approach. *Dig Liver Dis* 2015;47:125–30.
- [175] Casciani E, Nardo GD, Chin S, Masselli G, Polettoni E, Oliva S, et al. MR Enterography in paediatric patients with obscure gastrointestinal bleeding. *Eur J Radiol* 2017;93:209–16.