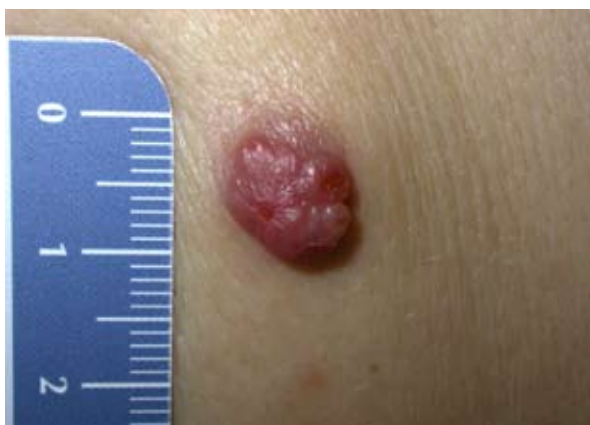

## Dermoscopy of Skin Adnexal Neoplasms: A Continuous Challenge

### Dear Editor,

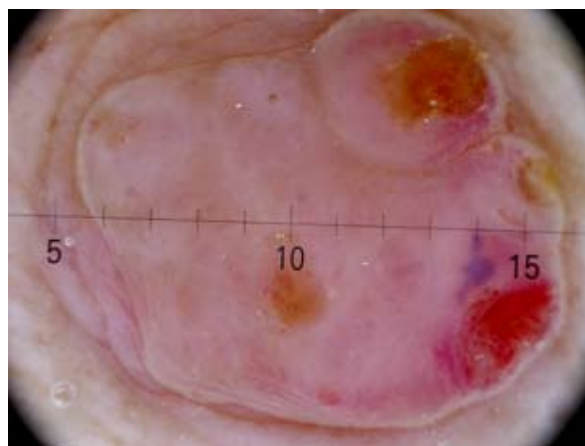
Apocrine hidradenoma is a rare benign adnexal tumor related to the more common poroma, as they both originate from sweat glands. Hidradenoma usually has an eccrine differentiation, but an apocrine differentiation is possible. Due to its rarity and non-specific clinical appearance it is difficult to differentiate it from other malignant cutaneous lesions. In this challenging task, dermoscopy could be particularly helpful to better describe, recognize, and differentiate these lesions. Unfortunately, the literature offers only few dermoscopic descriptions of this rare cutaneous neoplasm.

A 70-year-old woman in fair general condition was referred to our Department for an asymptomatic 10×8 mm single nodule on her left scapula. This nodule was red, dome shaped, well circumscribed, firm, and mildly tender (Figure 1). The patient reported that it had been present since approximately 7 months. The lesion was neither painful nor itchy and there was no bleeding. A skin examination did not show any other lesions with the same features or other suspicious lesions.

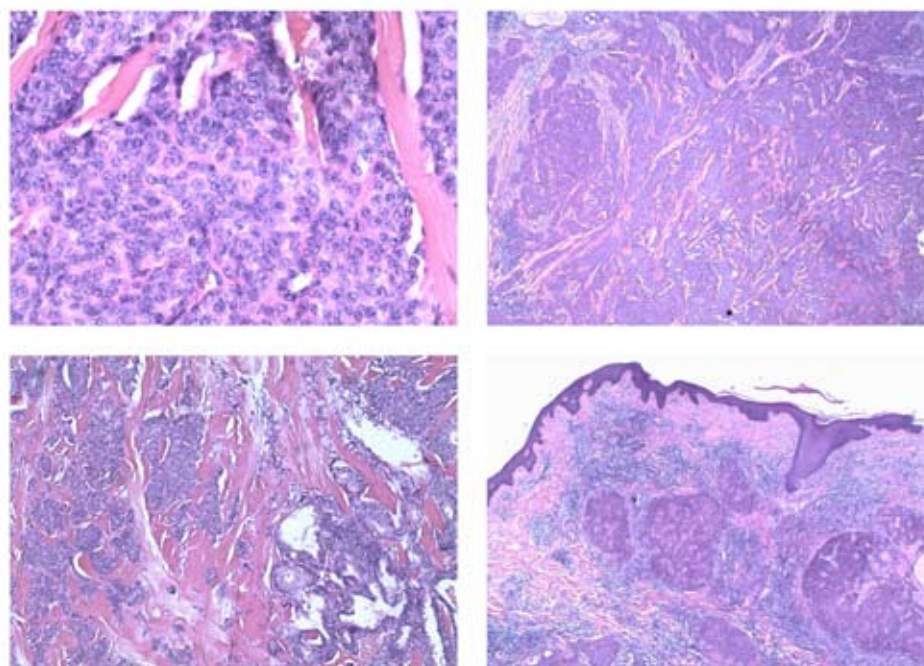


**Figure 1.** Mildly tender dome shaped red nodule on the left scapula.

Dermoscopy revealed milky-pinkish areas with dotted vessels, linear-irregular vessels, and hairpin vessels: some of these aspects can also be found in amelanotic melanoma (1). There were also homogeneous blue areas similar to lacunae, characteristic but not exclusive to vascular or sarcomatous neoplasms and basal cell carcinoma (1,2). Furthermore, small ulcerations covered by an amber crust were identified, which can usually be found in basal cell carcinoma. Regarding the background of the lesion, we noticed peculiar, translucent, pinkish, soft, large lobular areas (Figure 2). On the basis of this analysis, we suspected an atypical presentation of a basal cell carcinoma, an amelanotic melanoma, or a sarcomatous skin neoplasm. A metastasis of an unknown solid tumor was also taken into consideration. The histological examination revealed an adnexal neoplasm and specifically an apocrine hidradenoma. The neoplasm had variably sized nests and nodules of neoplastic epithelial



**Figure 2.** Dermoscopic features (20×). Soft lobular background. Milky-pinkish areas with dotted, linear-irregular vessels and hairpin vessels. Homogeneous blue areas similar to lacunae and small ulcerations covered by an amber crust.



**Figure 3.** Histological features (hematoxylin and eosin stain): lobulated and circumscribed masses composed of two cell types: polygonal cells and elongate, darker, and smaller cells.

cells, with a small ductular lumens confined within the upper dermis. The lesion was composed mainly of two cell types: polygonal and smaller, elongated, and darker cells. The cuboidal/polygonal cells were seen lining the duct-like spaces and slots and resembled those of poroma (Figure 3).

The adnexal skin tumors group includes a complex variety of uncommon tumors that can be distinguished only histologically, and most of them are benign (3). Searching the literature for "hidradenoma dermoscopy" and "adnexal dermoscopy" yields multiple descriptions of poromas but few dermatoscopic descriptions of hidradenoma (4). There was only one report of the presence of "arborizing vessels" (5), and another described "reddish purple areas and some linear or hairpin-like vessels on the surface of the tumor" (6). In another paper we found: "irregular scar like whitish areas and a polymorphous vascular pattern including irregular reddish-purple areas mimicking lacunar appearance of hemangiomas with thick hairpin vessels at the periphery" (7). It is very difficult to make use of such scant data especially in order to detect a leading pattern for a specific diagnosis. Moreover, the described structures lack in specificity, being also present in many other lesions. Analyzing our dermatoscopic image and comparing it to the other ones available in the literature, we identified a peculiar background. It consisted in the presence of multilobular translucent and pinkish soft areas, which fit the previously described dermatoscopic criteria.

We hypothesize there is a correlation between this feature and the histopathological presentation with variably sized nests and nodules. Of course, further case reports of hidradenoma are needed to identify the soft lobular background as a distinctive dermatoscopic feature. Due to the lack of specific features both clinically than dermatoscopically, histopathological analysis remains the only gold standard for diagnosis of these benign mimicking lesions.

### References:

1. Gatti A, di Meo N, Trevisan G. Dermoscopy of eccrine acrospiroma masquerading as nodular malignant melanoma. *Acta Dermatoven APA* 2010;19:23-5.
2. Obaidat N, Alsaad K, Ghazarian D. Skin adnexal neoplasms--part 2: An approach to tumours of cutaneous sweat glands. *J Clin Pathol* 2007;60:145-59.
3. Storm CA, Seykora JT. Cutaneous adnexal neoplasms. *Am J Clin Pathol* 2002;118:S33-S49
4. Zalaudek I, Kreusch J, Giacomel J, Ferrara G, Cattricà C, Argenziano G. How to diagnose nonpigmented skin tumors: a review of vascular structures seen with dermoscopy. *J Am Acad Dermatol* 2010;63:377-86.
5. Sgambato A, Zalaudek I, Ferrara G, Giorgio C, Moscarella E, Nicolino R, *et al.* Adnexal tumors: clinical

and dermoscopic mimickers of basal cell carcinoma. Arch Dermatol 2008;144:426.

6. Yoshida Y, Nakashima K, Yamamoto O. Dermoscopic features of clear cell hidradenoma. Dermatology 2008;217:250-1.
7. Demirci GT, Atis G, Altunay IK, Sakiz D. A giant benign clear cell hidradenoma on the anterior trunk. Dermatology Reports. 2011;3(3):e45. doi:10.4081/dr.2011.e45.

**Nicola di Meo<sup>1</sup>, Giuseppe Stinco<sup>2</sup>,  
Alessandro Gatti<sup>1</sup>, Mattia Fadel<sup>1</sup>, Silvia Vichi<sup>1</sup>,  
Giusto Trevisan<sup>1</sup>**

<sup>1</sup> *Department of Dermatology and Venerology,  
University of Trieste, Trieste, Italy*

<sup>2</sup> *Department of Experimental and Clinical Medicine,  
Institute of Dermatology, University of Udine,  
Udine, Italy*

**Corresponding Author:**

Mattia Fadel, MD  
Dermatology Department  
University of Trieste  
Ospedale Maggiore  
Piazza dell'Ospitale 1  
34135 Trieste  
Italy  
*dr.mattia.fadel@gmail.com*

Received: September 9, 2015

Accepted: February 23, 2016