

---

# Salivary bypass tube placement in esophageal stricture: A technical note and report of three cases

Giancarlo Tirelli, Roberto Baruca, Francesca Boscolo Nata \*

ENT Clinic, Head and Neck Department, Azienda Sanitaria Universitaria Integrata di Trieste, Strada di Fiume 447, 34149 Trieste, Italy

---

## ARTICLE INFO

### Keywords:

Esophageal-stricture  
Montgomery-salivary-bypass-tube  
Dysphagia  
Oral-feeding  
Quality-of-life

## ABSTRACT

Hypopharyngeal and cervical esophageal strictures can be caused by advanced malignancies, ingestion of caustic materials, or can follow surgery or radiation therapy.

They cause marked dysphagia and consequently patients need nasogastric or gastrostomy tube feeding, with a remarkable impact on quality of life.

To restore oral feeding, the stenosis can be progressively dilated by using rubber bougies of increasing diameter, and a Montgomery<sup>®</sup> Salivary Bypass Tube can then be inserted to maintain the obtained calibre. However, while its flexibility makes it easy to tolerate, it has the drawback of making insertion difficult because the tube tends to bend.

The aim of this paper is to present a possible solution to this problem. A Montgomery<sup>®</sup> Salivary Bypass Tube was distally sutured to a Cook Airway Exchange Catheter<sup>®</sup> to simplify its initial insertion through a laryngoscope and following replacements. The catheter was then easily removed leaving the bypass tube in the correct position.

In our experience, this innovative approach proved effective in facilitating Montgomery<sup>®</sup> Salivary Bypass Tube insertion in three patients, without risks for the patient, additional operative time or increase in costs.

---

## 1. Introduction

Hypopharyngeal and cervical esophageal strictures can be caused by advanced malignancies and ingestion of caustic materials or they can follow surgery or radiation therapy [1,2]. Affected patients suffer from marked dysphagia [3] and consequently require nutrition support through intravenous or enteral (nasogastric or gastrostomy tube) feeding, with an important decline of quality of life. In the management of a hypopharyngeal and cervical esophageal stricture, the dilation has first to be accomplished by using bougie dilators, which come in a variety of designs, calibres and lengths [4]. Once the stricture has been dilated, the diameter needs to be maintained constant. To this end, the use of a Montgomery<sup>®</sup> salivary bypass tube (MSBT) can be an effective solution allowing for the patient's

physiological nutrition. However, in some cases, placement of this tube may prove difficult because the flexibility of the tube combined with the need to lubricate it to negotiate the stricture can result in slippage and difficulty in handling it. These problems may be experienced not only during the first insertion of the tube, but also when it deteriorates and has to be replaced. In this paper we propose a new technique to simplify the placement of a MSBT by using a Cook Airway Exchange Catheter.

## 2. Case report

This study was conducted in accordance with the principles stated in the Declaration of Helsinki (1964) and was approved by our University ethics committee; patients gave their written informed consent for the publication of case details, images and video.

Patient #1 was a 58-year-old man with a history of T1a squamous cell carcinoma of the right vocal cord treated with

---


\* Corresponding author. Fax: +39 040 3994180.

E-mail address: [francesca.boscolonata@gmail.com](mailto:francesca.boscolonata@gmail.com) (F. Boscolo Nata).

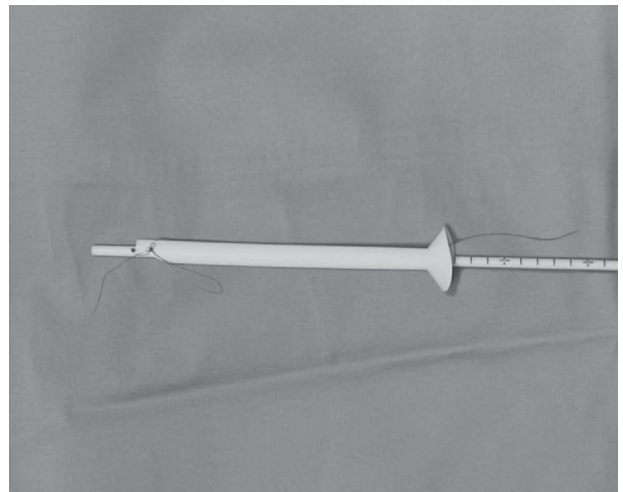
type III right laser cordectomy in October 2011 and adjuvant radiation therapy for the presence of “close” margins (0.1–3 mm, according to our Pathology Department) at histology. In December 2012 the patient underwent a total laryngectomy with bilateral neck dissection and hemi-thyroidectomy for a T4a laryngeal cancer. One month later he experienced a salivary fistula requiring a surgical revision; after two failures, a pectoralis major flap was set up, the fistula was closed and an esophageal stent was placed. The stent was removed two months later but the patient developed near total dysphagia. Microlaryngoscopy revealed near total hypopharyngeal stenosis; so, in September 2014, the stenotic tract was removed and a radial free flap with an esophageal stent to maintain patency was used to rebuild the damaged tract. The stent was removed three months later but the patient complained of total dysphagia, so a number 12 Montgomery<sup>®</sup> salivary bypass tube (MSBT) was inserted to maintain patency. During the following replacements, the procedure proved to be rather difficult.

Therefore, for the last replacement procedure in September 2015 we decided to attempt a new insertion method. After positioning a laryngoscope under general anaesthesia, we first used rubber bougie dilators (Fig. 1) of progressive diameters (Porges<sup>®</sup> Neoplex France) to dilate the stenosis; we then inserted a 19.0-French Cook Airway Exchange Catheter<sup>®</sup> (Cook Medical USA) inside a no. 16 MSBT (Boston Medical Products, USA) and anchored it with a stitch passing through the hole at its distal tip (Fig. 2). We introduced the system through the laryngoscope (Fig. 3) until the proximal end of the MSBT was positioned at the level of the base of the tongue. Finally, we withdrew the Cook Airway Exchange Catheter<sup>®</sup> while maintaining the MSBT in the correct position and, with the scissors generally used for microlaryngoscopy, we cut the residual thread (Video 1). The same procedure was used in January and May 2016 to replace the tube with a new no. 16 MSBT.

Supplementary Video 1 related to this article can be found, in the online version, at <http://dx.doi.org/10.1016/j.anl.2016.11.007>.

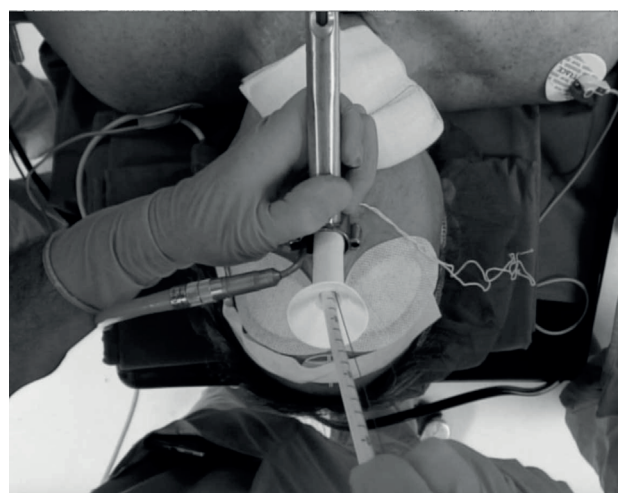


**Fig. 1.** Rubber bougie dilators of progressive diameters (Porges<sup>®</sup> Neoplex France).



**Fig. 2.** A Cook Airway Exchange Catheter<sup>®</sup> with a diameter of 19.0 French (Cook Medical USA) is inserted inside a no. 16 Montgomery<sup>®</sup> Salivary Bypass Tube (Boston medical products USA) and distally sutured with a stitch passing through the hole at its distal end.

Patient #2 was a 71-year-old man with a previous history of radiotherapy for positive surgical margins after an anterior pelvicotomy for a T1 squamous cell carcinoma of the anterior floor of the mouth in October 2007. In May 2015, the patient underwent a total laryngectomy with bilateral neck dissection for a T3 laryngeal cancer. Six days after surgery he developed a salivary fistula requiring a cervicotomy. Two surgical repairs were unsuccessful so a pectoralis major flap was set up and the fistula was closed. Twenty-three days after surgery the patient started to complain of dysphagia, and a tight stenosis of the neo-esophagus was found on microlaryngoscopy. A no. 8 MSBT was inserted but the procedure proved rather difficult. During the last replacement procedure in September 2015, we decided to use the method reported above. In this patient a no. 10 MSBT was initially used, and a no. 12 MSBT was placed during the last replacements in January and May 2016.



**Fig. 3.** The tool obtained by suturing the Montgomery<sup>®</sup> Salivary Bypass Tube (MSBT) to a Cook Airway Exchange Catheter<sup>®</sup> distally is introduced through the laryngoscope until the proximal extremity of the MSBT is positioned at the level of the base of the tongue.

Patient #3 was a 74-year-old man with a past history of radiation therapy for a squamous cell carcinoma of the left tonsil in 1998. In May 2014, he underwent a total laryngectomy extended to the left pyriform sinus and a bilateral neck dissection for a T3N0 of the left pyriform sinus. In November 2014, he started complaining of dysphagia for solid foods: during esophagogastroduodenoscopy (EGDS) a stenosis of the hypopharynx was found. The patient underwent multiple dilations with Savary-Gilliard bougies up to a calibre of 11 mm; in November 2015, his dysphagia worsened and only dilation with Savary-Gilliard bougies up to a calibre of 9 mm was possible. In February 2016, a no. 8 MSBT was positioned using the previously described technique. The MBST was replaced in June 2016.

The mean time needed to perform the procedure was 15 min. No antibiotic prophylaxis was necessary, and no procedure-related complications occurred. The patients were discharged after 24 h. All patients experienced an improvement in the dysphagia and they all started oral feeding after 48 h. No patient developed stent obstruction, and none of them reported an intolerable foreign body sensation. Patient #2 expelled the tube while coughing but it was successfully replaced using the same technique. At the time of writing, 2 or 3 months after insertion, all of the patients have the MSBT still in place.

### 3. Discussion

In 1978, Montgomery first described the use of a silicone salivary tube as an adjuvant therapy for hypopharyngeal or cervical esophageal strictures of different origin [5]. The Montgomery<sup>®</sup> Salivary Bypass Tube (Boston Medical Products, USA) is made of medical silicone which is soft and flexible but firm enough to keep the narrowed area open. It is available in 7 sizes between 8 and 20 mm, the ones measuring 12 and 14 mm being the most commonly used since they are well tolerated and allow a semisolid diet. Tube length is the same for all sizes (191 mm), and the upper end of the tube takes the form of a funnel to ease the collection of saliva and to prevent the tube from displacing distally [6].

According to the original description [5], insertion of the MSBT is done under general anaesthesia and direct visualization of the hypopharynx, using for example, a Jackson or anaesthetic laryngoscope. The tube is inserted with the aid of a McGill forceps and is pushed to its final position with the index finger.

It is well known that the main problems associated with the technique are the difficulty introducing the MSBT and the risk of tube dislocation; the use of the largest possible size of bypass tube can prevent pro- or retrograde migration of the stent [7].

Using the bougie previously employed to dilate the stricture as a guide has been proposed [7,8]. Another group reported inserting a lubricated Montgomery tube on a Savary dilator or a bronchoscope, which was passed through the stricture with endoscopic guidance, before the tube was pushed through the stricture manually [9].

In our experience, this method is not easy to perform because the lubrication required for the tube to cross the stricture makes the tube slippery and difficult to handle and push through the stricture, even when this has already been endoscopically dilated.

We believe that the use of a Cook Airway Exchange Catheter<sup>®</sup> sutured distally to an MSBT may be a valid option to facilitate tube placement, during both the first insertion and the following replacements.

The advantages of the proposed insertion method, also in comparison with other techniques reported in the literature, are as follows:

- A Cook Airway Exchange Catheter<sup>®</sup> is a tool normally found in our operating rooms so its use entails no adjunctive costs;
- The stiffness of the Cook Airway Exchange Catheter<sup>®</sup> can easily overcome the resistance of the distal stricture remaining after bougie dilation, but its blunt tip prevents the risk of damage to the hypopharyngeal and esophageal mucosa;
- The Cook Airway Exchange Catheter<sup>®</sup> can be easily removed from the MSBT once this has been placed in the correct position, without the risk of displacement.

A limit of our study is that, in our cases, the aetiology of the hypopharyngeal and cervical esophageal stricture was the same in all patients, that is, surgery and a previous history of radiotherapy. Further case series are required to assess whether the reported method is also effective in simplifying MSBT placement in the case of stenosis of other aetiologies as well.

### Conflict of interest

The authors declare no conflicts of interest.

### Acknowledgements

The authors thank Eng. Salvatore Scozzese for the technical help in video recording.

The authors thank Itala Mary Ann Brancaleone, MA, RSA Dip TEFLA, teacher of Medical English at the Università degli studi di Trieste, for help with language editing of the manuscript.

### References

- [1] Nguyen NP, Smith HJ, Moltz CC, Frank C, Millar C, Dutta S, et al. Prevalence of pharyngeal and esophageal stenosis following radiation for head and neck cancer. *J Otolaryngol Head Neck Surg* 2008;37:219–24.
- [2] Fuccio L, Hassan C, Frazzoni L, Miglio R, Repici A. Clinical outcomes following stent placement in refractory benign esophageal stricture: a systematic review and meta-analysis. *Endoscopy* 2016;48:141–8.
- [3] Lazarus CL. Effects of chemoradiotherapy on voice and swallowing. *Curr Opin Otolaryngol Head Neck Surg* 2009;17:172–8.
- [4] ASGE Technology Committee, Siddiqui UD, Banerjee S, Barth B, Chauhan SS, Gottlieb KT, et al. Tools for endoscopic stricture dilation. *Gastrointest Endosc* 2013;78:391–404.

- [5] Montgomery WW. Salivary bypass tube. *Ann Otol Rhinol Laryngol* 1978;87(Pt 1):159–62.
- [6] Montgomery WW, Montgomery SK. Manual for use of Montgomery laryngeal, tracheal, and esophageal prostheses: update 1990. *Ann Otol Rhinol Laryngol Suppl* 1990;150:2–28.
- [7] Lörken A, Krampert J, Kau RJ, Arnold W. Experience with the Montgomery Salivary Bypass Tube (MSBT). *Dysphagia* 1997;12:79–83.
- [8] Warren WH, Smith C, Faber LP. Clinical experience with Montgomery salivary bypass stents in the esophagus. *Ann Thorac Surg* 1994;57:1102–7.
- [9] Spinelli P, Parasher VK, Meroni E, Spinelli A, Cerrai F. Treatment of nondilatable malignant pharyngoesophageal strictures by Montgomery salivary bypass tube: a new approach. *Gastrointest Endosc* 1995;41:601–3.