

## Accepted Manuscript

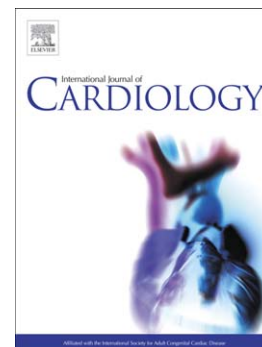
Takotsubo is not a Cardiomyopathy

Francesco Pelliccia, Gianfranco Sinagra, Perry Elliott, Guido Parodi,  
Cristina Basso, Paolo G. Camici

PII: S0167-5273(17)37259-5  
DOI: doi:[10.1016/j.ijcard.2017.12.009](https://doi.org/10.1016/j.ijcard.2017.12.009)  
Reference: IJCA 25763

To appear in: *International Journal of Cardiology*

Received date: 28 November 2017  
Accepted date: 5 December 2017



Please cite this article as: Pelliccia Francesco, Sinagra Gianfranco, Elliott Perry, Parodi Guido, Basso Cristina, Camici Paolo G., Takotsubo is not a Cardiomyopathy, *International Journal of Cardiology* (2017), doi:[10.1016/j.ijcard.2017.12.009](https://doi.org/10.1016/j.ijcard.2017.12.009)

This is a PDF file of an unedited manuscript that has been accepted for publication. As a service to our customers we are providing this early version of the manuscript. The manuscript will undergo copyediting, typesetting, and review of the resulting proof before it is published in its final form. Please note that during the production process errors may be discovered which could affect the content, and all legal disclaimers that apply to the journal pertain.

## Takotsubo is not a Cardiomyopathy

Francesco Pelliccia, MD,<sup>a</sup> Gianfranco Sinagra, MD,<sup>b</sup> Perry Elliott, MD,<sup>c</sup> Guido Parodi, MD,<sup>d</sup> Cristina Basso, MD,<sup>e</sup> and Paolo G. Camici, MD,<sup>f,\*</sup>

<sup>a</sup>Department of Cardiovascular Sciences, Sapienza University, Rome, Italy;

<sup>b</sup>Cardiovascular Department, Azienda Sanitaria-Universitaria Integrata of Trieste 'ASUITS', Trieste, Italy;

<sup>c</sup>Institute of Cardiovascular Science, University College London and St. Bartholomew's Hospital, London, United Kingdom;

<sup>d</sup>Clinical and Interventional Cardiology, Sassari University Hospital, Sassari, Italy;

<sup>e</sup>Department of Cardiac, Thoracic and Vascular Sciences, University of Padua Medical School, Padua, Italy;

<sup>f</sup>Vita-Salute University and San Raffaele Hospital, Milan, Italy.

Word count: 3,242 (overall)

References: 25

Numbers of figures: 2

Short title: Takotsubo Syndrome

\*Corresponding author:

Professor Paolo G. Camici

Vita-Salute University, Via Olgettina, 58,  
20132 Milan, Italy

Tel: +39 02 2643 6206; Fax: +39 02 2643 6218,

E-mail: *camici.paolo@hsr.it*

**ABSTRACT**

Unraveling the mechanisms underlying Takotsubo (TTS) leads to question the current inclusion of the condition within the spectrum of cardiomyopathies. Indeed, the clinical presentation and pathophysiology of TTS clearly differ from cardiomyopathies, i.e. diseases of heart muscle unexplained by abnormal loading conditions or coronary artery disease, which cannot recover spontaneously and may cause sudden death often in minimally symptomatic individuals or result in a gradual deterioration in ventricular function and end-stage heart failure. Furthermore, the term 'cardiomyopathy' can no longer be applied when functional or morphologic abnormalities of the coronary arteries leading to acute myocardial ischemia are deemed responsible for left ventricular (LV) systolic dysfunction.

After 27 years of investigation, time has come to recognize that patients with TTS do suffer from severe myocardial ischemia and fulfill all criteria of acute coronary syndromes, i.e. acute chest pain, typical electrocardiographic changes, cardiac troponin rise, as well as LV wall motion abnormalities. Accordingly, we propose that TTS should be labeled as an acute 'syndrome' to be included more appropriately within the spectrum of ischemic heart disease. With regard to the term 'stress', it may imply that the catecholamine surge is essential to produce the typical transient myocardial injury. Thus, the terminology 'Takotsubo (stress) syndrome' would more accurately reflect recent advances in the pathophysiology.

**Keywords**

Takotsubo; apical ballooning syndrome; catecholamine; coronary circulation, myocardial ischemia; stunning.

**ABBREVIATIONS AND ACRONYMS**

AHA = American Heart Association

ESC = European Society of Cardiology

ISFC = International Society and Federation of Cardiology

LV = left ventricle

TTS = Takotsubo Syndrome

WHO = World Health Organization

ACCEPTED MANUSCRIPT

## Definition and classification of cardiomyopathies

Exactly 60 years ago, the term 'cardiomyopathy' was first used to define myocardial disease not caused by coronary artery disease, and a few years later a systematic approach to the classification of cardiomyopathies according to clinical presentation was proposed.<sup>1</sup> In 1980, the World Health Organization/International Society and Federation of Cardiology (WHO/ISFC) Task Force published a report on the 'definition and classification of cardiomyopathies' designed to promote the use of a common rational approach to nomenclature (1). Cardiomyopathies were defined as '*heart muscle diseases of unknown causes*' to distinguish them from those secondary to systemic/cardiac causes such as hypertension, ischemic heart disease and valvular disease.<sup>1</sup> Since then, continuous progress has been made with regard to the understanding of etiology, pathogenesis, diagnosis and therapy of heart muscle diseases and new forms of cardiomyopathy such as arrhythmogenic right ventricular and restrictive cardiomyopathies have been identified (2).

In 1995, a WHO/IFSC Task Force attempted to account for this rapid evolution of knowledge by proposing a new consensus classification in which cardiomyopathies were defined as '*disease of the myocardium associated with cardiac dysfunction*' and were defined according to anatomy and physiology (3). After a further 10 years, an expert panel under the auspices of the American Heart Association (AHA) proposed a revision of the 1995 classification in which cardiomyopathies were defined as '*a heterogeneous group of diseases of the myocardium associated with mechanical and/or electrical dysfunction ... due to a variety of causes that frequently are genetic*' (4). Cardiomyopathies were considered as either primary or secondary, with the former being those solely or predominantly confined to heart muscle that can be further classified as genetic, mixed or acquired, and the latter showing pathological

myocardial involvement as part of a systemic condition.

In 2008, the European Society of Cardiology (ESC) working group on myocardial and pericardial diseases proposed an update to the WHO/ISFC classification in which cardiomyopathy was defined as '*a myocardial disorder in which the heart muscle is structurally and functionally abnormal in the absence of coronary artery disease, hypertension, valvular disease and congenital heart disease sufficient to explain the observed myocardial abnormality*' (5). These exclusions were justified on the premise that the diagnosis and treatment of these common disorders generally involve clinical issues quite different from those encountered in most cardiomyopathies, as originally proposed in 1995 (3).

The most recent innovation in disease nosology is the MOGE(S) classification (6), which describes disease using five categories: morpho-functional phenotype (M), organ(s) involvement (O), genetic inheritance pattern (G), etiological annotation (E) including genetic defect or underlying disease/substrate, and the functional status (S). The system is based on nomenclatures used in other settings (particularly cancer) and is designed to be sufficiently flexible to be able to take into account new or emerging information about disease and phenotype (6).

### **Takotsubo labeled as a new cardiomyopathy**

It is been 27 years since Sato *et al.* described an unusual appearance of the left ventricle (LV), which resembled the 'takotsubo', a Japanese fisherman's pot with a round bottom and narrow neck used for trapping octopuses (7). The term Takotsubo was subsequently used to describe a clinical condition in which patients present with an abrupt onset of angina-like chest pain and diffuse T-wave inversion, sometimes preceded by ST-segment elevation and cardiac enzyme release (8,9). Initially, the

presentation is indistinguishable from an acute coronary syndrome, but it can be subsequently differentiated by the demonstration of angiographically normal epicardial coronary arteries and involvement of myocardium that extends beyond a single epicardial coronary vessel territory that recovers in few days or weeks (8,9). As is usual when a new disease is described, this condition acquired a remarkable multiplicity of individual descriptive names, including 'apical ballooning', 'broken heart syndrome' and 'ampulla cardiomyopathy', but Takotsubo and stress cardiomyopathy have become the preferred terms and, in the 1995 WHO/IFSC Task Force classification, were included for the first time as an acquired primary form of cardiomyopathy (3).

### **Is the Takotsubo phenomenon a cardiomyopathy?**

Using current ESC and AHA definitions for cardiomyopathy, TTS qualifies as a cardiomyopathy, but it differs in several important respects from other forms of heart muscle disease. Although there is no doubt that mechanisms of TTS still need to be fully elucidated, available data indicate that, at variance with all other cardiomyopathies, TTS does not have any objective marker of a primary myocardial injury and is almost always associated with *restitutio ad integrum* (10). TTS is often precipitated by physical or emotional stress and available evidence clearly shows that catecholamines are a key part of its pathogenesis (10). However, the histological appearances of TTS are quite different from those seen in other states such as pheochromocytoma in which catecholamine toxicity is implicated. In these scenarios, there is contraction band necrosis – a unique form of myocyte injury characterized by hypercontracted sarcomeres, dense eosinophilic transverse bands, and an interstitial mononuclear inflammatory response - that is distinct from the

polymorphonuclear inflammation seen with infarction (11). In contrast, in TTS, serial myocardial biopsies during the phase of severely impaired LV function and after functional recovery show cell swelling and widening of the interstitial space followed by normalization of the myocardium with normal size of myocytes, a few small vacuoles, and a regular interstitium (12).

The lack of irreversible morphologic changes in TTS is further demonstrated by data from cardiac magnetic resonance (CMR). The technique can distinguish TTS from a catecholamine-mediated myocarditis, which commonly occurs in pheochromocytoma (13). The histologic footprint of pheochromocytoma, that include degenerative changes in muscle fibers, foci of necrosis, acute inflammation, chronic interstitial inflammatory exudation, and replacement-type fibrosis, may be observed on CMR as myocardial necrosis and diffuse fibrosis that may be associated with long-term LV functional changes (13). A completely different pattern is observed in TTS patients. CMR studies have shown that the acute phase of the disease is characterized only by intense myocardial edema, with a lack of macroscopic fibrosis. Testa and Feola were able to obtain serial CMR data in some patients with TTS and found no evidence of delayed enhancement after gadolinium injection either in the acute phase or at 3 months follow up, suggesting that the damage in the dysfunctional areas was transient and did not include significant necrosis (14).

None of the existing cardiomyopathy classifications really consider this notion of reversibility. In genetic disease, the underlying defect is permanent, and while it could be argued that dysfunction can be 'reversed' with therapy (as in dilated cardiomyopathy, for example), the intrinsic myocardial defect remains and is never cured. Heart muscle disease caused by myocarditis can be a reversible phenotype, but is more often associated with some permanent damage to the myocardium and



(depending on the cause) be a chronic disease with periods of relapse and remission.

In the 2008 ESC classification, TTS was included as a unique-single category defined as an 'unclassified' and 'non-familial' cardiomyopathy despite the lack of a distinct chronic phenotype, the absence of a genetic origin, and no clear manifestation of structural abnormalities (5). Similarly, it is quite questionable whether Takotsubo can be accommodated in the MOGE(S) classification as the five attributes of a cardiomyopathy cannot be applied after the acute phase (6). In short, the inclusion of Takotsubo within the spectrum of cardiomyopathies is questionable (15).

### **Myocardial ischemia in Takotsubo**

New information has shed additional light on the pathogenesis of TTS supporting the concept that the condition is caused by acute myocardial ischemia (10). The crucial role of myocardial ischemia in TTS has emerged thanks to the evidence that most cases of TTS occur in patients with risk factors for coronary disease and/or comorbidities, including neurologic, psychiatric, pulmonary, kidney, liver and connective tissue disease (16), that are associated with endothelial dysfunction and might therefore constitute a previously unrecognized predisposing factor for TTS (17). Indeed, endothelial dysfunction could explain the propensity to epicardial and/or microvascular coronary artery spasm of the disease (18). This pathologic state of the endothelium characterized by an imbalance between vasoconstricting and vasodilating factors, may represent an important link between stress and myocardial dysfunction in TTS (10). Since the first description of TTS, coronary vasospasm has been suggested as a plausible causative factor. In their original report, Sato *et al.* (7) reported epicardial coronary artery spasm in 8 of 35 patients (23%) and diffuse

coronary vasoconstriction in 19 (54%). Similarly, Angelini *et al.* confirmed the development of coronary spasm in TTS patients who underwent acetylcholine testing (19).

In addition to abnormalities of the epicardial arteries, coronary microvascular dysfunction might play a pathogenetic role in TTS (**Figure 1**)(20). Small coronary arteries and arterioles receive autonomic innervation and are the principal determinants of coronary vascular resistance. In normal subjects the overall response to sympathetic activation is vasodilatation mainly through activation of coronary  $\beta_2$ -adrenoceptors. By contrast, in patients with endothelial dysfunction increased cardiac sympathetic activity can induce  $\alpha$ -adrenoceptor mediated coronary microvascular constriction powerful enough to provoke myocardial ischemia (21). Abnormal coronary microvascular responses have been documented in TTS using invasive and non-invasive diagnostic tools (22). At time of urgent coronary angiography, there is evidence of reduced Thrombolysis in Myocardial Infarction frame count (23). Using myocardial contrast echocardiography, clear perfusion defects can be observed in the LV segments showing reduced contractility. These perfusion defects usually improve transiently with intracoronary adenosine and recover permanently at 1-month of follow-up (24). Single photon emission computed tomography perfusion studies have shown a decrease in tracer uptake during the acute phase of TTS and a return to normal at follow-up, further suggesting a role for coronary microvascular dysfunction as a trigger of myocardial ischemia in this condition (25). In summary, there is now agreement that the increased concentration of catecholamine occurring in the acute phase of TTS induces direct myocardial injury and coronary vasoconstriction, mostly at the microvascular level, together with an increased cardiac workload that contribute to an acute situation of 'supply-

demand mismatch' followed by post-ischemic stunning. The clinical counterpart is the typical, reversible LV ballooning followed by complete functional recovery in most cases (**Figure 2**)(10).

### **Takotsubo, a novel form of ischemic heart disease**

Unraveling the mechanisms underlying TTS leads to question the current inclusion of the condition within the spectrum of cardiomyopathies (17). Indeed, the clinical presentation and pathophysiology of TTS clearly differ from cardiomyopathies, i.e. diseases of heart muscle unexplained by abnormal loading conditions or coronary artery disease, which cannot recover spontaneously and may cause sudden death often in minimally symptomatic individuals or result in a gradual deterioration in ventricular function and end-stage heart failure. Furthermore, the term 'cardiomyopathy' can no longer be applied when functional or morphologic abnormalities of the coronary arteries leading to acute myocardial ischemia are deemed responsible for LV systolic dysfunction.

After 27 years of investigation, time has come to recognize that patients with TTS do suffer from severe myocardial ischemia and fulfill all criteria of acute coronary syndromes, i.e. acute chest pain, typical electrocardiographic changes, cardiac troponin rise, as well as LV wall motion abnormalities (**Central Illustration**).

Accordingly, we propose that TTS should be labeled as an acute 'syndrome' to be included more appropriately within the spectrum of ischemic heart disease (17). With regard to the term 'stress', it may imply that the catecholamine surge is essential to produce the typical transient myocardial injury. Thus, the terminology 'Takotsubo (stress) syndrome' would more accurately reflect recent advances in the pathophysiology (10).

**Conflict of interest:** none declared

ACCEPTED MANUSCRIPT

## References

1. Report of the WHO/ISFC task force on the definition and classification of cardiomyopathies. *Br Heart J* 1980;44:672-3.
2. Thiene G, Corrado D, Basso C. Cardiomyopathies: is it time for a molecular classification? *Eur Heart J* 2004;25:1772–5.
3. Richardson P, McKenna W, Bristow M, et al. Report of the 1995 World Health Organization/International Society and Federation of Cardiology Task Force on the definition and classification of cardiomyopathies. *Circulation* 1996;93:841-2.
4. Maron BJ, Towbin JA, Thiene G, et al. Contemporary definitions and classification of the cardiomyopathies: an American Heart Association Scientific Statement from the Council on Clinical Cardiology, Heart Failure and Transplantation Committee; Quality of Care and Outcomes Research and Functional Genomics and Translational Biology Interdisciplinary Working Groups; and Council on Epidemiology and Prevention. *Circulation* 2006;113:1807-16.
5. Elliott P, Andersson B, Arbustini E, et al. Classification of the cardiomyopathies: a position statement from the European Society Of Cardiology Working Group on Myocardial and Pericardial Diseases. *Eur Heart J* 2008; 29: 270-6.
6. Arbustini E, Narula N, Dec GW, et al. The MOGE(S) classification for a phenotype-genotype nomenclature of cardiomyopathy: Endorsed by the world heart federation. *Glob Heart* 2013;8:355-82.
7. Sato TH, Uchida T, Dote K, Ishihara M. Tako-tsubo-like left ventricular dysfunction due to multivessel coronary spasm. In: Kodama K, Haze K, Hori

- M, eds. Clinical aspect of myocardial injury: from ischemia to heart failure. Tokyo, Japan: Kagakuhyoronsha Publishing Co;1990; 56–64.
8. Templin C, Ghadri JR, Diekmann J, et al. Clinical features and outcomes of Takotsubo (Stress) cardiomyopathy. *N Engl J Med* 2015;373:929–38.
  9. Lyon AR, Bossone E, Schneider B, et al. Current state of knowledge on Takotsubo syndrome: a position statement from the Task force on Takotsubo Syndrome of the Heart Failure Association of the European Society of Cardiology. *Eur J Heart Fail* 2016;18:8–27.
  10. Pelliccia F, Kaski JC, Crea F, Camici PG. Pathophysiology of Takotsubo Syndrome. *Circulation* 2017;135:2426-41.
  11. Basso C, Thiene G. The pathophysiology of myocardial reperfusion: a pathologist's perspective. *Heart* 2006;92:1559–62.
  12. Nef HM, Möllmann H, Kostin S, et al. Tako-Tsubo cardiomyopathy: intraindividual structural analysis in the acute phase and after functional recovery. *Eur Heart J* 2007;28:2456-64.
  13. Ferreira VM, Marcelino M, Piechnik SK, et al. Pheochromocytoma is characterized by catecholamine-mediated myocarditis, focal and diffuse myocardial fibrosis, and myocardial dysfunction. *J Am Coll Cardiol* 2016;67:2364-74.
  14. Testa M, Feola M. Usefulness of myocardial positron emission tomography/nuclear imaging in Takotsubo cardiomyopathy. *World J Radiol* 2014;6:502–6.
  15. Lüscher TF, Templin C. Is takotsubo syndrome a microvascular acute coronary syndrome? Towards of a new definition. *Eur Heart J* 2016;37:2816-20.

16. Pelliccia F, Parodi G, Greco C, et al. Comorbidities frequency in Takotsubo syndrome: an international collaborative systematic review including 1109 patients. *Am J Med* 2015; 128:654.e11-9.
17. Pelliccia F, Greco C, Vitale C, Rosano G, Gaudio C, Kaski JC. Takotsubo syndrome (stress cardiomyopathy): an intriguing clinical condition in search of its identity. *Am J Med* 2014;127:699-704.
18. Naegele M, Flammer AJ, Enseleit F, et al. Endothelial function and sympathetic nervous system activity in patients with Takotsubo syndrome. *Int J Cardiol* 2016;224:226–30.
19. Angelini P. Transient left ventricular apical ballooning: a unifying pathophysiologic theory at the edge of Prinzmetal angina. *Catheter Cardiovasc Interv* 2008;71:342-52.
20. Crea F, Camici PG, Bairey Merz CN. Coronary microvascular dysfunction: an update. *Eur Heart J* 2014;35:1101–11.
21. Heusch G, Baumgart D, Camici P, et al. Alpha-adrenergic coronary vasoconstriction and myocardial ischemia in humans. *Circulation* 2000;101:689–94.
22. Vitale C, Rosano GM, Kaski JC. Role of coronary microvascular dysfunction in Takotsubo cardiomyopathy. *Circ J* 2016;80:299–305.
23. De Caterina AR, Leone AM, Galiuto L, et al. Angiographic assessment of myocardial perfusion in Tako-Tsubo syndrome. *Int J Cardiol* 2013;168:4717-22.
24. Galiuto L, De Caterina AR, Porfidia A, et al. Reversible coronary microvascular dysfunction: a common pathogenetic mechanism in apical ballooning or Tako-Tsubo syndrome. *Eur Heart J* 2010;31:1319–1327.

25. Nishikawa S, Ito K, Adachi Y, Katoh S, Azuma A, Matsubara H. Ampulla (“Takotsubo”) cardiomyopathy of both ventricles: evaluation of microcirculation disturbance using 99mTc-tetrofosmin myocardial single photon emission computed tomography and Doppler guide wire. *Circ J* 2004;68:1076–80.

ACCEPTED MANUSCRIPT



**Figure 1 Mechanism of Myocardial Ischemia**

Coronary microvascular dysfunction has recently emerged as a potential mechanism of myocardial ischemia. As in the case of the other two pathogenetic mechanisms, atherosclerotic disease and/or epicardial coronary vasospasm, coronary microvascular dysfunction (alone or in combination with the two) can lead to transient myocardial ischemia as in patients with coronary artery disease or cardiomyopathy or to severe acute ischemia as observed in Takotsubo syndrome.

CAD, coronary artery disease; CFR, coronary flow reserve; CMP, cardiomyopathy.

The figure is from Crea F et al. and with permission (20).

**Figure 2 Key Pathogenetic Aspects in Takotsubo Syndrome**

The picture depicts the interplay among triggers, pathogenetic factors, mechanisms of cardiac injury, and clinical consequences. Current evidences indicate that in the acute phase of TTS there is an increased concentration of catecholamines that might induce direct myocardial injury and coronary spasm, mostly at the microvascular level, together with an increased cardiac workload that contribute to an acute situation of 'supply-demand mismatch' followed by post-ischemic stunning.

ANS, autonomic nervous system; CNS, central nervous system; LV, left ventricular;  $MVO_2$ , myocardial oxygen consumption.

The figure is from Pelliccia F et al. and with permission (10).

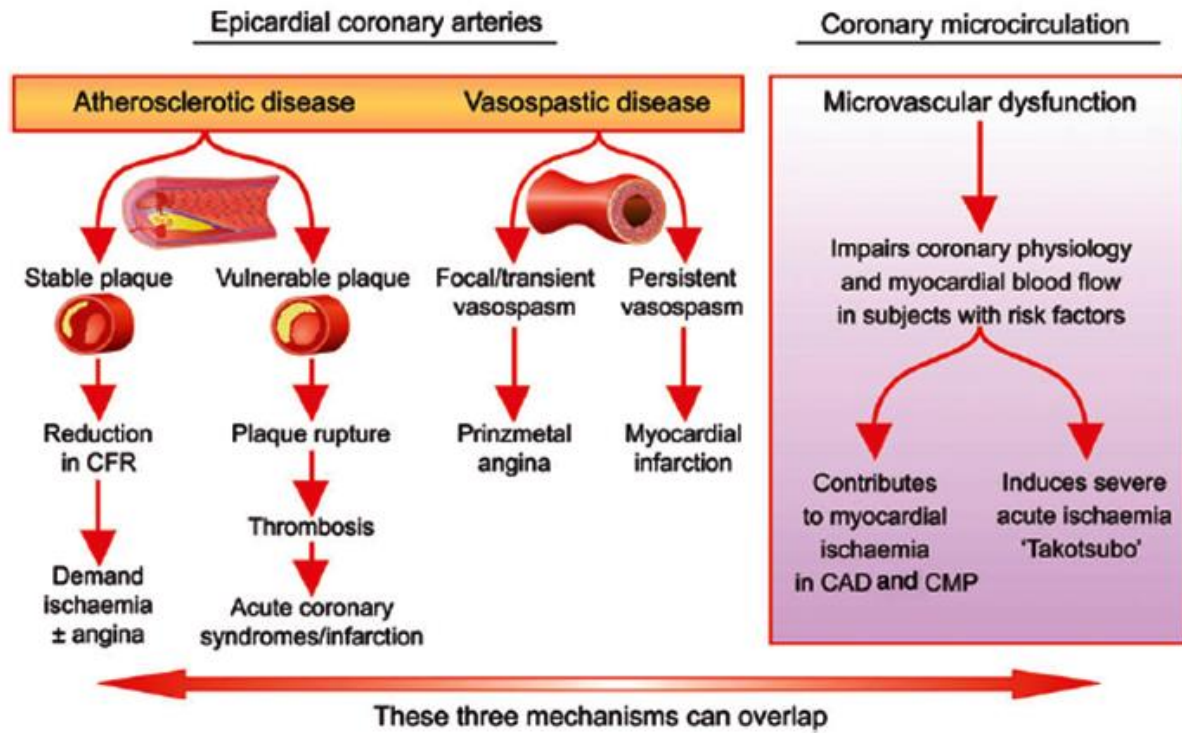


Figure 1

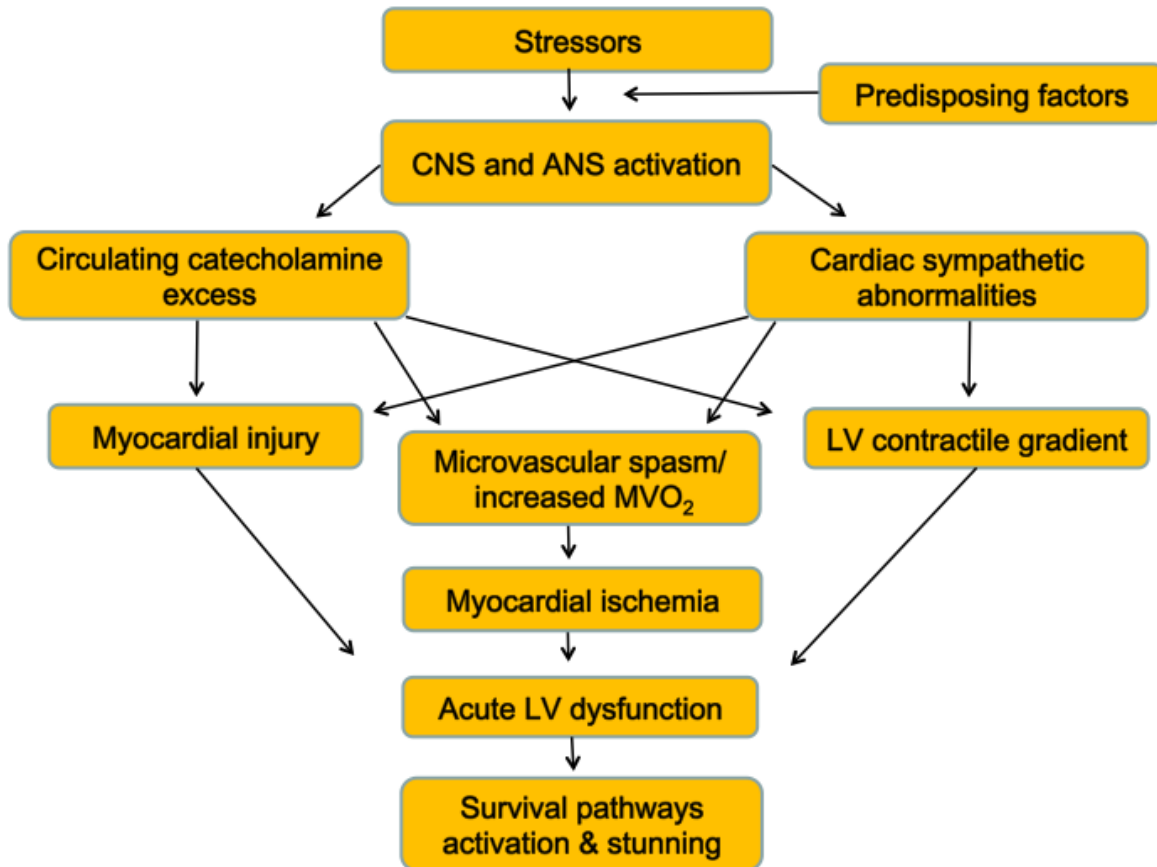


Figure 2

## Highlights

### “Takotsubo is not a Cardiomyopathy”

- The current inclusion of Takotsubo syndrome within the spectrum of cardiomyopathies should be questioned
- The term 'cardiomyopathy' can no longer be applied when functional or morphologic coronary abnormalities occur
- Clinical presentation and pathophysiology of Takotsubo syndrome clearly differ from cardiomyopathies
- Patients with Takotsubo syndrome do suffer from severe myocardial ischemia and fulfill all criteria of acute coronary syndromes
- Takotsubo syndrome should be included more appropriately within the spectrum of ischemic heart disease