Solitary angiokeratoma with Meyerson phenomenon

André Oliveira, MD,[a] Jorge Cardoso, MD,[a] and Iris Zalaudek, MD[b]
Lisbon, Portugal, and Graz, Austria

Key words: angiokeratoma; confocal microscopy; dermoscopy; melanoma; Meyerson phenomenon; skin cancer.

CLINICAL PRESENTATION

A 42-year-old woman was referred to our department for possible melanoma on the left thigh. She presented with a 2-year history of a dark papule that progressively grew larger, and 3 weeks before presentation also with an associated red halo and pruritus. Physical examination revealed a symmetric erythematous halo around a central, ill-defined, firm, dark-blue to black papule, 5 mm in diameter (Fig 1, *A*).

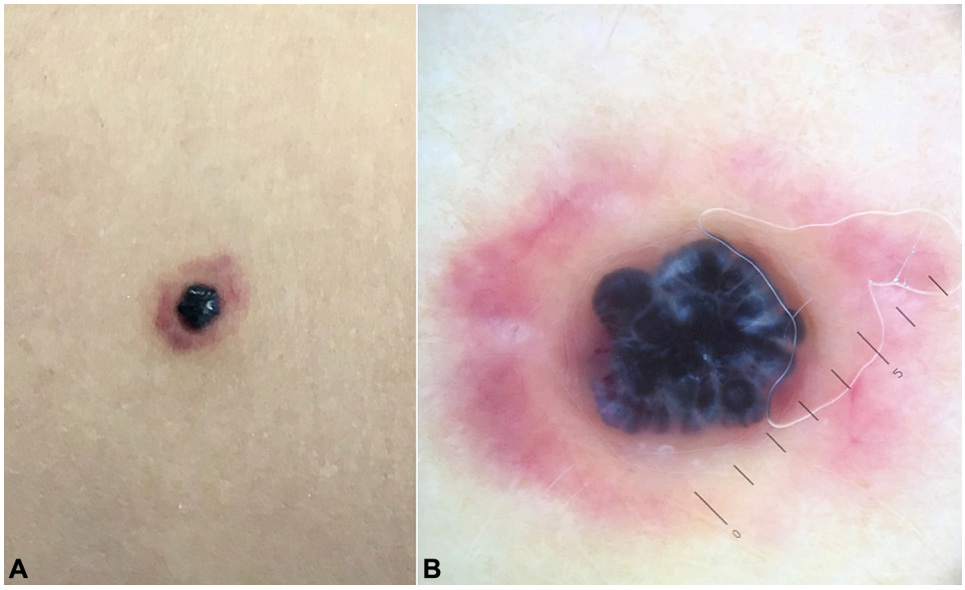

Fig 1. Angiokeratoma, clinical and dermoscopic presentation. **A**, Ill-defined, dark-blue to black papule on the left thigh, 5 mm in diameter, surrounded by a peripheral rim of erythema. **B**, Dermoscopy disclosed central, multiple dark lacunae and whitish veil, and peripheral yellow structureless and erythema areas.

DERMOSCOPIC APPEARANCE

Central dark lacunae and whitish veil were seen surrounded by an inner yellow structureless halo, and peripheral erythema with few dotted vessels within (Fig 1, *B*).

CONFOCAL MICROSCOPY APPEARANCE

Reflectance confocal microscopic features are detailed in Fig 2.

From the Departments of Dermatology at British Hospital, Lisbon,[a] and Medical University of Graz.[b]
Publication of this article was supported by 3Gen Inc.
Funding sources: None.
Conflicts of interest: None declared.
Reprint requests: André Oliveira, MD, Department of Dermatology, British Hospital, Lisbon, Portugal. E-mail: andre.oliveira@sapo.pt.

J Am Acad Dermatol 2017;76:S16-8.
0190-9622/$36.00

http://dx.doi.org/10.1016/j.jaad.2016.04.039

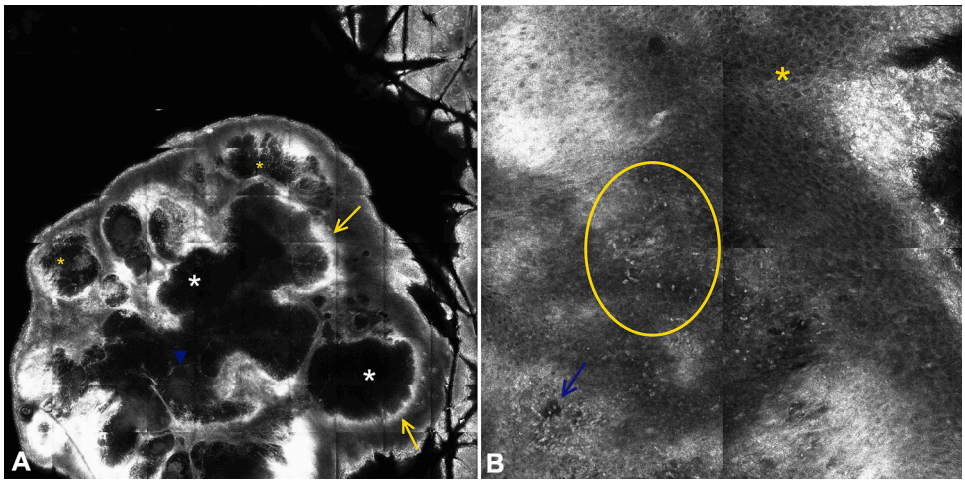

Fig 2. Angiokeratoma, reflectance confocal microscopy appearance. **A**, Mosaic image (5 × 5 mm) at papillary dermis showed multiple lumina below the dermoepidermal junction, as dark dilated spaces (*white asterisk*) correlating with dermoscopic lacunae, separated by bright septa made of epidermal cells (*yellow arrow*); no apparent blood flow was observed. Dark lumina were filled with highly refractile roundish cells, corresponding to endothelial cells, erythrocytes, and leukocytes (*yellow asterisk*), some arranged in a rhomboidal fashion (*blue arrowhead*). **B**, Mosaic image (1 × 1 mm) at spinous and granular layers showed exocytosis of lymphocytes (*yellow circle*), spongiosis (*yellow asterisk*), and few dark vesicles (*blue arrow*), which corresponded to the erythematous, eczema-like halo. At dermoepidermal junction, multiple bright cells and blurred papillae were observed, also related to adjacent areas of skin inflammation.

HISTOLOGIC DIAGNOSIS

Clinical, dermoscopic, and confocal microscopic correlation suggested the diagnosis of solitary angiokeratoma with Meyerson phenomenon, which was supported after shave biopsy specimen and histopathological examination (Fig 3).

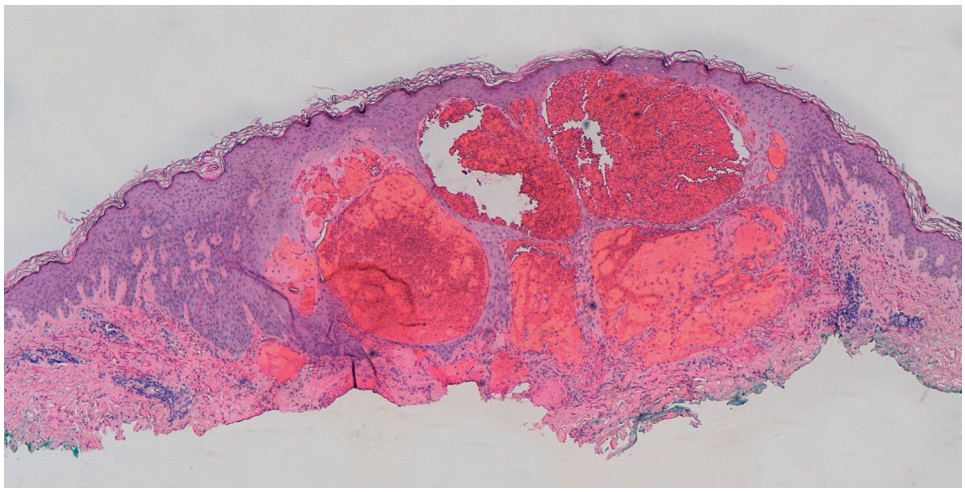

Fig 3. Angiokeratoma, histopathological examination. Multiple, ectatic, thin-walled, congested vessels mainly in the papillary dermis underlying a hyperkeratotic epidermis with variable degrees of acanthosis. In the dermis, a superficial perivascular inflammatory infiltrate mainly composed of lymphocytes and few eosinophils was observed. Ectatic, congested vessels correlated to the dermoscopic dark lacunae and confocal features of dark spaces filled with bright cells. Hyperkeratosis and acanthosis might relate to the whitish veil. Perivascular inflammatory infiltrate corresponded well to the described confocal features of inflammation, and clinical appearance of an eczema-like halo that best characterizes Meyerson phenomenon. (Hematoxylin-eosin stain; original magnification: ×40.)

KEY MESSAGE

Rare Meyerson phenomenon is defined by a symmetric halo of erythema around central, mostly melanocytic tumors.[1] Our case showed that its association with angiokeratoma can be clinically mistaken for melanoma.[2] We report the dermoscopic and reflectance confocal microscopic features that provide clues for this unique presentation, enhancing their importance as noninvasive techniques for the in vivo diagnosis of nonmelanocytic (vascular) tumors and inflammatory (eczematous) lesions.

REFERENCES

1. Oliveira A, Arzberger E, Massone C, Fink-Puches R, Zalaudek I, Hofmann-Wellenhof R. Dermoscopy, reflectance confocal microscopy and immunohistochemical analysis in melanocytic lesions with Meyerson's phenomenon. *Dermatology*. 2014;229:297-305.
2. Alarcón I, Brito J, Alos L, Malvehy J, Puig S. In vivo characterization of solitary angiokeratoma by reflectance confocal microscopy and high definition optical coherence tomography. *J Am Acad Dermatol*. 2015;72(Suppl):S43-S44.