

Blue-gray plaque of the penis



Manuel António Campos, MD, Ana Sousa, MD, Gisela Lage, MD, Paulo Varela, MD,
Nuno Menezes, MD, David Tente, MD, Iris Zalaudek, MD, PhD,
Armando Baptista, MD, and Natividade Rocha, MD
Vila Nova de Gaia, Portugal

Key words: confocal microscopy; dermatopathology; dermoscopy; genital wart; human papillomavirus; penis.

CLINICAL PRESENTATION

We report the case of a 66-year-old white man with a 6-month history of a blue-gray plaque of the glans. The patient was heterosexual, with 2 sexual partners in the last 6 months, and denied condom use. There was no personal or family history of melanoma. Physical examination of the uncircumcised penis found a round, well-demarcated, smooth, blue-gray plaque measuring 8 × 10 mm, arising within an erythematous background plaque of the glans (Fig 1). The remaining physical examination was unremarkable, including the oral cavity.



Fig 1. Round, well-demarcated, smooth, blue-gray plaque measuring 8 × 10 mm, arising within an erythematous background plaque of the glans.

DERMOSCOPIIC APPEARANCE

Within the plaque we observed regularly arranged gray dots surrounded by a white halo over a blue-white structureless background (Fig 2).

From Centro Hospitalar Vila Nova de Gaia e Espinho.

Funding sources: None.

Conflicts of interest: None declared.

Correspondence to: Manuel António Campos, MD, Centro Hospitalar Vila Nova de Gaia e Espinho, Vila Nova de Gaia, Avenida Repatriamento dos Poveiros, nº 28A, 11°C, Edifício Cristal Mar, 4490-404, Póvoa de Varzim, Portugal. E-mail: manuelantonio campos@gmail.com.

JAAD Case Reports 2018;4:531-3.

2352-5126

© 2017 by the American Academy of Dermatology, Inc. Published by Elsevier, Inc. This is an open access article under the CC BY-NC-ND license (<http://creativecommons.org/licenses/by-nc-nd/4.0/>).

<http://dx.doi.org/10.1016/j.jidcr.2017.07.026>

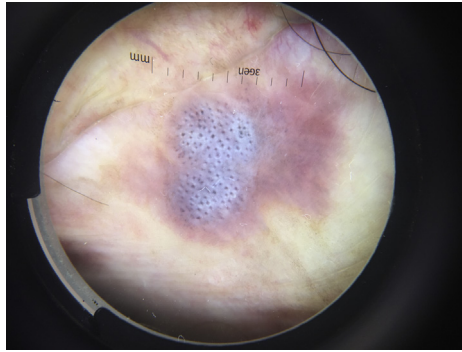


Fig 2. Regularly arranged gray dots surrounded by a white halo over a blue-white structureless background.

CONFOCAL MICROSCOPY APPEARANCE

We observed a cordlike pattern with refractile round cellular structures in the stratum corneum, suggesting parakeratosis.¹ We also observed a typical honeycomb pattern (Fig 3).

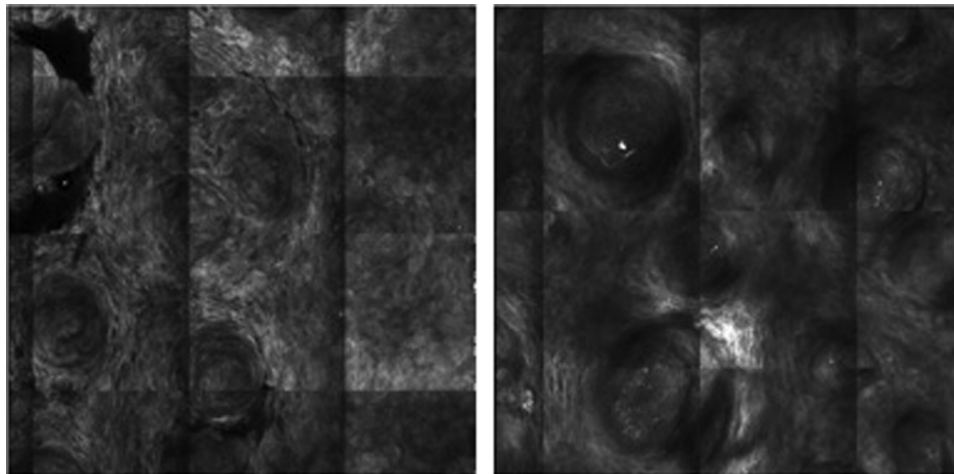


Fig 3. Cordlike pattern with refractile round cellular structures in the stratum corneum, suggesting parakeratosis. Typical honeycomb pattern.

HISTOLOGIC DIAGNOSIS

A shave biopsy found the presence of parakeratosis, acanthosis, and papillomatosis of the epidermis. We also observed within the keratinocytes, abundant cytoplasm and irregularly hyperchromatic nuclei (koilocytosis) (Fig 4). Polymerase chain reaction of the biopsy was positive for human papillomavirus type 6.

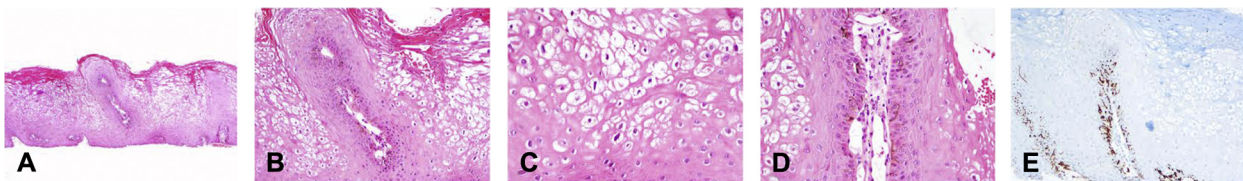


Fig 4. **A**, Parakeratosis with acanthosis, mild papillomatosis, and diffuse koilocytosis. **B**, Abundant basal melanin pigment and papilla with prominent ectatic vascular core. **C**, Detail of the koilocytes with conspicuous perinuclear vacuolization and elongated and irregular hyperchromatic nuclei. **D**, Detail of a markedly dilated capillary in a papilla and the abundant melanin pigment at the basal layer cells. **E**, HMB-45 marker highlighting melanocytes and their cytoplasmic processes. (A-D, Hematoxylin-eosin stain; E, HMB-45 stain; original magnifications: A, ×40; B and E, ×100; C and D, ×200.)

KEY MESSAGE

Genital warts are the most common sexually transmitted disease, and they are caused by the human papillomavirus.² This case highlights the difficulties encountered in the differential diagnosis of darkly pigmented planar lesions of the penis. Dermoscopic patterns in genital warts have been described by several investigators (fingerlike, knoblike, mosaiclike, and pattern combinations).³⁻⁸ We present a case of genital wart that falls into none of the aforementioned patterns. The honeycomb pattern observed on confocal microscopy is normally observed in seborrheic keratoses. This case illustrates the complementarity of dermoscopy and confocal microscopy in the diagnosis of clinically atypical lesions of the genital mucosa.

REFERENCES

1. Gonzalez S. [Clinical applications of reflectance confocal microscopy in the management of cutaneous tumors]. *Actas Dermosifiliogr*. 2008;99(7):528-531.
2. Partridge JM, Koutsky LA. Genital human papillomavirus infection in men. *Lancet Infect Dis*. 2006;6(1):21-31.
3. Dong H, Shu D, Campbell TM, Fruhauf J, Soyer HP, Hofmann-Wellenhof R. Dermoscopy of genital warts. *J Am Acad Dermatol*. 2011;64(5):859-864.
4. Ozdemir F, Kilinc-Karaarslan I, Akalin T. A pigmented, hemorrhagic genital wart: clinical, dermoscopic, and histopathologic features. *Arch Dermatol*. 2008;144(8):1072-1073.
5. Ozkur E, Falay T, Turgut Erdemir AV, Gurel MS, Leblebici C. Vestibular papillomatosis: an important differential diagnosis of vulvar papillomas. *Dermatol Online J*. 2016;22(3).
6. Pastar Z, Lipozencic J. Significance of dermoscopy in genital dermatoses. *Clin Dermatol*. 2014;32(2):315-318.
7. Veasey JV, Framil VM, Nadal SR, Marta AC, Lellis RF. Genital warts: comparing clinical findings to dermoscopic aspects, in vivo reflectance confocal features and histopathologic exam. *An Bras Dermatol*. 2014;89(1):137-140.
8. Zalaudek I, Giacomel J, Cabo H, et al. Entodermoscopy: a new tool for diagnosing skin infections and infestations. *Dermatology*. 2008;216(1):14-23.