

## 46,XY ovotesticular disorders of sex development: A therapeutic challenge

Maria-Grazia Scarpa,<sup>1</sup>  
Massimo Di Grazia,<sup>2</sup> Gianluca Tornese<sup>3</sup>

<sup>1</sup>Pediatric Surgery Institute for Maternal and Child Health, IRCCS Burlo Garofolo, Trieste; <sup>2</sup>Institute for Maternal and Child Health, IRCCS Burlo Garofolo, Trieste; <sup>3</sup>Department of Pediatrics, Institute for Maternal and Child Health, IRCCS Burlo Garofolo, Trieste, Italy

### Abstract

46,XY ovotesticular disorder of sex development is extremely rare and indicates the presence of both testis and ovary in the same patient. Gender assignment in newborns represents a therapeutic challenge. We describe and comment on our multidisciplinary approach, ten years after the Chicago consensus meeting on disorder of sex development.

### Introduction

Ovotesticular disorder of sex development (OT-DSD) means the simultaneous presence in the same individual of both, histologically proven, testis and ovary. OT-DSD is very rare: it occurs between 3% and 10% of the total DSD. In Europe, 46,XY is the less common karyotype in OT-DSD. *Matsui* reports that the most frequent gonadal combination is ovotestis-ovary (33.9%). The gonadal combination of ovotestis-streak gonad occurs in only 1.2% of the case.<sup>1</sup> Gonadal tumours occur between 2.6 and 4.6% of OT-DSD, more frequently in 46,XY cases. The chance of degeneration in Müllerian remnants is exceptional, although some authors describe it.<sup>2</sup>

Gender assignment in newborns with OT-DSD represents a therapeutic challenge. In 2005 the Chicago Consensus Statement on Management of Intersex Disorders established that the factors that influence gender assignment include: i) diagnosis; ii) genital appearance; iii) surgical options; iv) need for life long replacement therapy; v) potential for fertility; vi) views of the family; vii) circumstances relating to cultural practise.<sup>3</sup>

According to recent trends, it is better to postpone surgery, leaving a neutral gender

until patients are able to participate to the decision. There is, however, little evidence provided regarding the impact of non-treated DSD during childhood on individual development, parents, society and risk of stigmatization.<sup>4</sup>

The opinion of the parents about the sex of rearing is crucial especially when diagnosis is made in neonatal age. A constant psychological support is essential for supporting the family. The child well-being in the family and in the society is the final goal of the treatment and should be considered.

We describe and comment on our multidisciplinary approach in a case of 46,XY OT-DSD.

### Case Report

A newborn was transferred to our Institute for genital ambiguity. At birth the patient presented: i) hypospadias without micropenis; ii) penile curvature; iii) not palpable gonads

No familiar, gestational or perinatal problems were reported. The socio-cultural level of the family was low.

### Investigations

Fetal sonogram assessed a male phenotype. Postnatal karyotype was 46,XY. A cytogenetic analysis of 200 metaphases on peripheral blood excluded a X0/XY mosaicism and the SNPs-array was negative for pathological deletions and duplications. A deletion of 1.89 Mb in the region 8p23.3 was found, being of maternal origin. As we know, the gene is not directly correlated to sexual development.

The attempt to investigate mutation of SRY failed and wasn't repeated.

When the patient was nine days old, he daily received an intramuscular injections of 1000 U of human chorionic gonadotropin for three days (hCG test). Before and after the injections a blood sampling was done.

The serum level pre-hCG was: total testosterone 0.68 ng/mL (0.01-1.77); free testosterone 4.46 pg/mL (8.69-54.69); dehydroepiandrosterone-sulphate (DHEAs) 168 µg/dL (1.0-41.0); androstenedion: 9.14 ng/mL (0.60-3.10).

The serum level post-hCG was: total testosterone 1.23 ng/mL; free testosterone 7.25 pg/mL; dehydroepiandrosterone-sulphate (DHEAs) 104.4 µg/dL; androstenedion: 3.19 ng/mL 1.23 ng/mL.

Serum anti-Müllerian hormone (AMH), inhibin B and dihydrotestosterone (DHT) level were normal. Uterus and vagina were identified on ultrasound scan and magnetic resonance imaging (MRI) (Figure 1) and confirmed by laparoscopy.

Correspondence: Maria-Grazia Scarpa, Pediatric Surgery, Institute for Maternal and Child Health, IRCCS Burlo Garofolo, via dell'Istria 65/1, 34137 Trieste, Italy.  
Tel.: +39.040.3785314.  
E-mail: mariagrazia.scarpa@burlo.trieste.it

Key words: disorders of sex development; Ovotestis; Fertility; Gonadal tumor.

Contributions: the authors contributed equally.

Conflict of interest: the authors declare no potential conflict of interest.

Received for publication: 9 February 2017.

Revision received: 1 August 2017.

Accepted for publication: 3 August 2017.

This work is licensed under a Creative Commons Attribution NonCommercial 4.0 License (CC BY-NC 4.0).

©Copyright M-G. Scarpa et al., 2017

Licensee PAGEPress, Italy

Pediatric Reports 2017; 9:7085

doi:10.4081/pr.2017.7085

### Treatment

Preoperatively, parents expressed a strong desire for a male child. At the age of 17 months the laparoscopic exploration allowed us to make a diagnosis of 46,XY OT-DSD. A macroscopically streak gonad (Figure 2) was found and removed on the left side. A small primitive ovary containing follicles was confirmed histologically. On the right side we identify a vas deferens from the uterus and a testis. A biopsy of the right gonad was made. The microscopic evaluation was consistent with a small testicle with numerous immature tubular formations and presence of Leydig and Sertoli cells. No immunohistochemistry studies were performed on gonadic tissue. Orchiopexy and the first correction stage of the hypospadias were performed; we left the asymptomatic Müllerian tissue (uterus and vagina) *in situ*. At the age of 24 months we performed the second phase of hypospadias correction and eight months later the definitive correction with repair of a urethral dehiscence.

### Outcome and follow-up

Last follow-up at 36 months of age, the psychological assessment showed that the behavior of the child and the child's games were typically male. The family was satisfied and received a specific psychological support.

The medical and surgical team explained to the parents the necessity of

annually visit, testicular ultrasound scan and blood dosage of beta hCG and alfa fetoprotein for the risk of development of germ cell tumors. The family was informed that the risk of cancer is higher for a dysgenetic gonad than a simple cryptorchidism, especially in the puberal age. If signs of degeneration will become evident, an orchiectomy will be the therapy together with a substitutive hormonal treatment. The parents understood and accepted the yearly follow-up and its implications.

## Discussion

According to potential fertility, the medical and surgical decisions could be difficult in 46 XY OT-DSD. It seems that males report greater satisfaction with their gender and sexual lives.<sup>5</sup>

The ovarian tissue is usually normal and demonstrates follicular growth. The testicular tissue is often dysgenetic with hyalinization of the seminiferous tubules and poor germ cell development almost always resulting in infertility in patients assigned to the male gender.

Conservative treatment is the goal of the multidisciplinary treatment of DSD, especially when the sex assignment is required during neonatal period.

The aims of surgery are: i) to restore functional genital anatomy; ii) to facilitate future reproduction; iii) to reduce urological

hazards related to abnormal genitourinary anatomy; iv) to avoid fluid or blood retention in vaginal or uterine cavities; v) to avoid late virilization at puberty in individual raised as girls or breast development in individuals raised as boys; vi) to reduce risk of gonadal cancers; vii) to foster development of *individual* and *social identities*; viii) to avoid stigmatization related to atypical anatomy; ix) to respond to the parents' desire to bring up a child in the best possible conditions.<sup>4</sup>

The timing of surgery remains controversial.<sup>3</sup>

Our surgical interventions will not preclude the future possibility of a male-to-female genitoplasty.

At birth, a *no gender* registration is allowed in many countries because of the impossibility of consulting the patient about his or her gender assignment. However, families often ask for an early surgical reconstruction: our opinion is to respect families' will. The child well-being in the family, in the school and in any social interaction is the most important goal. The treatment requires a multidisciplinary approach and excellent medical, surgical and psychological expertise. After adequate psychological counseling, family pressure about male sex assignment was strong in our case and we took into account the familiar desires and the fact that the social visibility or gender is recommended by most to make the child socially visible.<sup>4</sup> The female intra-abdominal gonad macroscopically looked

like a streak gonad, despite the histological presence of follicles. No evidence exists about prophylactic removal of asymptomatic discordant structures, such as Müllerian remnant. A clinical surveillance is mandatory. Annual ultrasound surveillance is recommended for gonadal cancer risk even when the gonad is in the scrotum. If precancerous lesions are suspected, more invasive procedures (MRI, serum tumor markers, biopsy) are mandatory.

## Conclusions

OT-DSD is a very rare anomaly: its sexual assignment is a challenge and the treatment debated. To date, only few studies have been conducted on gender dysphoria in this group of patients and no specific well-coded guidelines exist. It is important to accommodate the requests of the patient, if he or she can express the preference about the sex of rearing. However, after the Consensus Conference of Chicago, most authors suggest not to proceed with a surgical treatment if it is not considered *life-saving*. The question is: what should be done in front of an insistent request of operation by the parents? If the diagnosis is made in the neonatal period, the role of the psychologist becomes essential. A constant psychological support to the family and a multidisciplinary follow-up are the keys for an optimal outcome. The surgery must be more conservative as possible: in our opinion, the

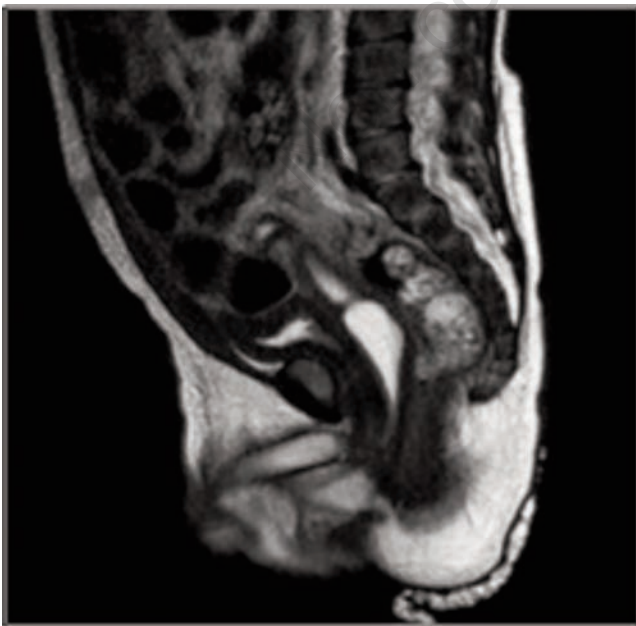


Figure 1. Sagittal image of pre-operative magnetic resonance imaging.

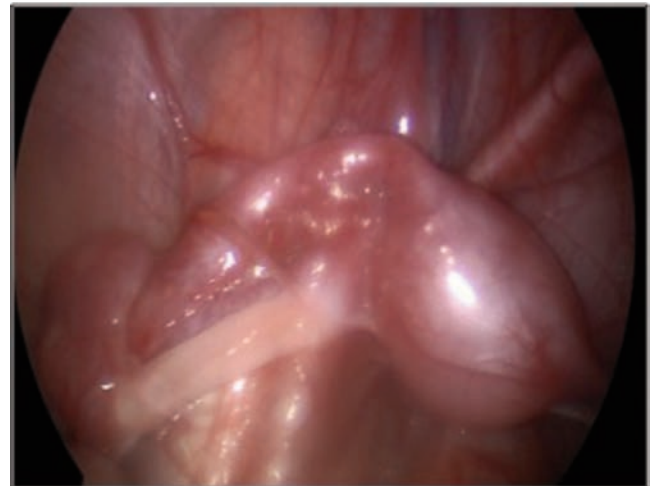

Figure 2. Laparoscopic image of streak gonad.

fact of keeping *in situ* the asymptomatic Müllerian remnants, provides the possibility of a future sex reassignment surgery, on patient's request. What about cryptorchidism and hypospadias? We think that the surgeon and the multidisciplinary team should consult the psychologist.

---

## References

1. Matsui F, Shimada K, Matsumoto F, et al. Long-term outcome of ovotesticular disorder of sex development: a single center experience. *Int J Urol* 2011;18:231-6.
2. Farikullah J, Ehtisham S, Nappo S, et al. Persistent Müllerian duct syndrome: lesson learned from managing a series of eight patients over a 10-year period and review of literature regarding malignant risk from the Müllerian remnants. *BJU* 2012;110:E1084-9.
3. Houk CP, Hughes IA, Ahmed SF, et al. Summary of consensus statement on intersex disorders and their management. *Pediatrics* 2006;118:753-7.
4. Mouriquand PDE, Brindusa Gorduz D, Gay CL, et al. Surgery in disorders of sex development (DSD) with a gender issue: If (why), when, and how? *J Pediatr Urol* 2016;12:139-49.
5. Verkauskas G, Jaubert F, Lortat-Jacob S, et al. The long-term follow-up of 33 cases of true hermaphroditism: a 40-year experience with conservative gonadal surgery. *J Urol* 2007;177:726-31.

Non commercial use only