

## Novel nicastrin mutation in hidradenitis suppurativa–Dowling–Degos disease clinical phenotype: more than just clinical overlap?

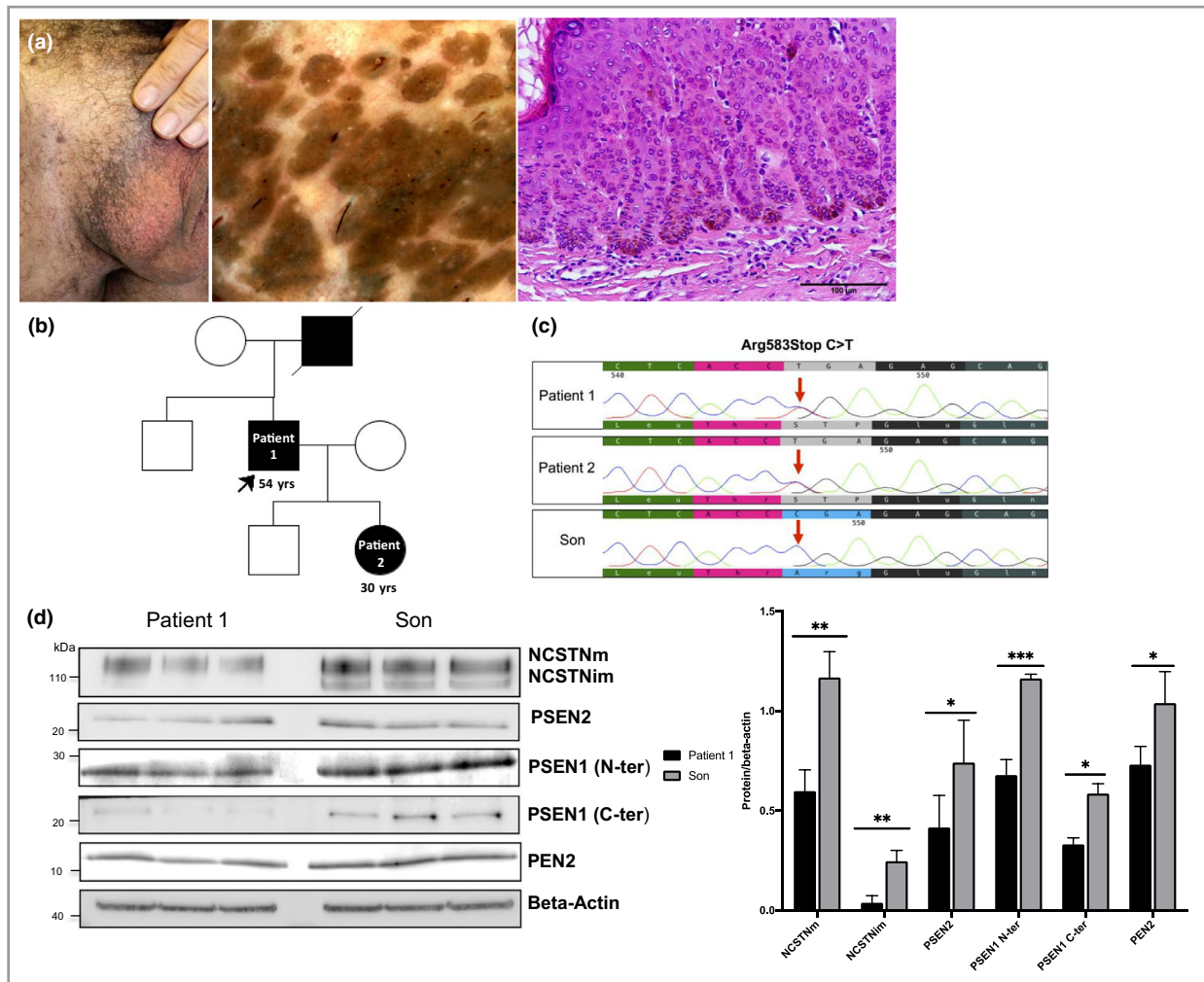
DOI: 10.1111/bjd.19121

DEAR EDITOR, In familial hidradenitis suppurativa (HS), mutations in the genes encoding three subunits of the gamma secretase complex, presenilin-1 (PSEN1), presenilin enhancer (PSENEN) and nicastrin (NCSTN), have pointed to impaired Notch signalling as a pathogenic disease mechanism.<sup>1</sup>

Dowling–Degos disease (DDD; MIM 179850, 615327 and 615696), a rare reticulated pigmentary disorder, has also been

associated with deficient Notch signalling, and patients with mutations in PSENEN suffering from both HS and DDD seem to confirm a potential link between two apparently different conditions.<sup>2,3</sup> However, why mutations in PSENEN cause DDD, HS or the combined HS–DDD phenotype, and why mutations in NCSTN have never been associated to DDD, is not yet understood. In this study, we describe a patient with familial HS and concomitant DDD harbouring a novel nonsense mutation in NCSTN associated with a reduced number of critical subunits of gamma secretase.

A 54-year-old male patient, with a diagnosis of HS and Hurley stage II disease, was examined for recurrent inflammatory lesions affecting the inguinal and genital regions. He reported a family history of HS (father and daughter). In addition, physical examination showed a typical reticulated flexural pigmentation, localized on the scrotum and inguinal crease (Figure 1a).



**Figure 1** (a) Dowling–Degos disease (DDD): flexural reticulate hyperpigmentation with representative dermoscopy and histology. (b) Family pedigree of the proband. (c) Chromatograms of the heterozygous single-nucleotide variation in the nicastrin gene (NCSTN) exon 15 encoding a premature stop codon identified in the proband (Patient 1) and hidradenitis suppurativa (HS)-affected daughter (Patient 2), absent in the clinically healthy son. (d) Western blot analysis of three independent cultures of outer root sheath (ORS) cells isolated from the proband with HS and DDD and his healthy son. Passage 1 ORS cells were seeded in a six-well plate, grown to confluence and proteins extracted in radioimmunoprecipitation assay buffer. Gamma secretase protein expression was studied with antibodies against NCSTN (clone 716910), PEN2 (D6G8), PSEN2 (D30G3) and PSEN1 N-terminal fragment (N-ter; E3L9X) and C-terminal fragment (C-ter; D39D1). Beta-actin was used as loading control. Results from the three experiments were pooled and their distribution compared using an unpaired t-test. m, mature; im, immature. \* $P < 0.05$ ; \*\* $P < 0.01$ ; \*\*\* $P < 0.001$ .

Histopathological examination of lesional skin confirmed diagnosis of classic DDD. Onset of HS lesions was reported at the age of 25 years, while first signs of flexural hyperpigmentation were reported at the age of 40 years. The patient never smoked, had a normal body mass index, and no other comorbidities.

Patient DNA was extracted from saliva. We sequenced, with the Sanger method, using exon-flanking intronic primers, all coding regions of genes associated to DDD: *KRT5* (nine exons), *POGLUT1* (11 exons), *POFUT1* (seven exons) and *PSE-NEN* (four exons). We identified only two missense single-nucleotide variations in *KRT5*, both reported as benign in ClinVar (National Institutes of Health, Bethesda, MD, USA).

As the proband suffered from HS, we sequenced the coding region of *NCSTN* (17 exons) and detected a single-nucleotide variation in *NCSTN* exon 15 (NM\_015331.2:c.1747C>T), encoding a premature stop codon [NP\_056146.1:p.(R583\*)] (Figure 1c, d). This genetic variant was not present in the Genome Aggregation Database (gnomAD) v.2.1.1. Subsequently, we sequenced *NCSTN* from his 30-year-old daughter with HS (Figure 1b) and his clinically healthy son, observing only in the daughter cosegregation of the *NCSTN* heterozygous single-nucleotide variation (Figure 1c, e). Interestingly, physical examination of the patient's daughter did not reveal any signs of DDD.

As the substitution encoded a premature stop codon, we wondered whether the mutation could cause haploinsufficiency following nonsense-mediated RNA decay (NMD) of *NCSTN*. To confirm this, we compared *NCSTN* expression by outer root sheath (ORS) cells isolated from the patient's plucked hairs and those of the healthy son.



It has been reported that *NCSTN* is dispensable for NOTCH receptor processing by gamma secretase, so we questioned whether *NCSTN* haploinsufficiency could lead to gamma secretase complex instability and degradation of its subunits. To verify this, we studied *PEN2*, *PSEN1* (N-terminal and C-terminal fragments) and *PSEN2* expression in ORS cell extracts. After normalization with beta-actin, we observed that the quantity of these subunits was significantly diminished in ORS cells from our patient compared with the healthy son ( $P < 0.05$ ; unpaired t-test) (Figure 1d, f).

The combined HS-DDD phenotype has been reported in different families and case series. Their *PSENE*N mutations have been associated with HS, HS/DDD or isolated DDD.<sup>2–4</sup> Most of the pathogenic variants in *PSENE*N are nonsense or frameshift mutations causing haploinsufficiency of *PEN2* either by its proteasomal degradation or by NMD.<sup>2</sup>

We have further expanded the spectrum of the combined HS/DDD phenotype, reporting the novel role of *NCSTN* and suggesting a putative link between autoinflammatory and pigmentary disorders. Interestingly, the *NCSTN* mutation of our patient affected *PEN2* quantity, mimicking its haploinsufficiency. Preliminary experimental evidence suggests a role of *NCSTN* deficiency in pigmentary disorders, by modulating melanosome degradation.<sup>5</sup>

In autoinflammatory conditions such as HS, *NCSTN* haploinsufficiency seems to stimulate the proliferation, type I

interferon gene expression and tumour necrosis- $\alpha$ -induced inflammatory response of keratinocytes.<sup>6</sup> The fact that our patient has managed to control skin inflammation avoiding well known risk factors could have helped to detect the DDD phenotype, which could arise late in life.<sup>7</sup> The affected daughter did not yet present any clinical signs of DDD, which might develop at a later age, as observed in her father. The clinical and genetic overlap of HS-DDD may also have a clinical relevance, translating into a personalized therapeutic management, such as the combination of retinoids and sulfones.<sup>8</sup>

S. Garcovich <sup>1,2</sup>, P.M. Tricarico,<sup>3</sup> C. Nait-Meddour,<sup>4,5</sup> G. Giovanardi,<sup>1,2</sup> K. Peris,<sup>1,2</sup> S. Crovella<sup>3,6</sup> and M. Boniotta <sup>4,5</sup>

<sup>1</sup>UOC Dermatologia, Dipartimento di Scienze Mediche e Chirurgiche, Fondazione Policlinico Universitario A. Gemelli IRCCS, Rome, Italy;

<sup>2</sup>Università Cattolica del Sacro Cuore, Rome, Italy; <sup>3</sup>Department of Advanced

Diagnostics, Institute for Maternal and Child Health-IRCCS 'Burlo

Garofolo', Trieste, Italy; <sup>4</sup>University of Paris Est-Créteil, Créteil, France;

<sup>5</sup>Institut Mondor for Biomedical Research INSERM U955 Team 16, Créteil,

France; and <sup>6</sup>Department of Medical, Surgical and Health Sciences, University of Trieste, Trieste, Italy

Correspondence: Michele Boniotta.

Email: michele.boniotta@inserm.fr

## References

- Wang B, Yang W, Wen W et al.  $\gamma$ -Secretase gene mutations in familial acne inversa. *Science* 2010; **330**:1065.
- Ralser DJ, Basmanav FB, Tafazzoli A et al. Mutations in  $\gamma$ -secretase subunit-encoding *PSENE*N underlie Dowling-Degos disease associated with acne inversa. *J Clin Invest* 2017; **127**:1485–90.
- Pavlovsky M, Sarig O, Eskin-Schwartz M et al. A phenotype combining hidradenitis suppurativa with Dowling-Degos disease caused by a founder mutation in *PSENE*N. *Br J Dermatol* 2018; **178**:502–8.
- Li C, Li W, Xu H et al. *PSENE*N mutation carriers with co-manifestation of acne inversa (AI) and Dowling-Degos Disease (DDD): is AI or DDD the subphenotype? *J Invest Dermatol* 2017; **137**:2234–6.
- Hsu CH, Liou GG, Jiang YJ. Nicastrin deficiency induces tyrosinase-dependent depigmentation and skin inflammation. *J Invest Dermatol* 2019; **140**:404–14.
- Zhang J, Li M, Yao Z. Updated review of genetic reticulate pigmentary disorders. *Br J Dermatol* 2017; **177**:945–59.
- Cao L, Morales-Heil DJ, Roberson EDO. Nicastrin haploinsufficiency alters expression of type I interferon-stimulated genes: the relationship to familial hidradenitis suppurativa. *Clin Exp Dermatol* 2019; **44**:e118–e125.
- Agut-Busquet E, González-Villanueva I, Romani de Gabriel J et al. Dowling-Degos disease and hidradenitis suppurativa. Epidemiological and clinical study of 15 patients and review of the literature. *Acta Derm Venereol* 2019; **99**:917–18.

Funding sources: This work was supported by a Biomolecular Analyses for Tailored Medicine in AcneInversa (BATMAN) project, funded by ERA PerMed, and by a grant from the Institute for Maternal and Child Health IRCCS 'Burlo Garofolo/Italian Ministry of Health' (RC16/2018).

Conflicts of interest: The authors declare they have no conflicts of interest.