

# Evaluation of Surgical Outcome in Rhinoplasty: A Comparison Between Rasp and Osteotome in Dorsal Hump Removal

Ear, Nose & Throat Journal  
2021, Vol. 100(5S) 436S–442S  
© The Author(s) 2019  
Article reuse guidelines:  
sagepub.com/journals-permissions  
DOI: 10.1177/0145561319883529  
journals.sagepub.com/home/ear  


Simone Zucchini, MD<sup>1</sup>, Silvia Brancatelli, MD<sup>1</sup>, Alice Piccinato, MD<sup>1</sup> ,  
Alberto Vito Marcuzzo, MD<sup>1</sup> , Max Bianchi, MD<sup>1</sup>, and Giancarlo Tirelli, MD<sup>1</sup>

## Abstract

Dorsal hump reduction is a crucial point of rhinoplasty, as it has a great impact on the final shape of nasal pyramid. Depending on morphological features of the hump, its removal is usually obtained by the use of an osteotome or a rasp. In our study, we describe a closed rhinoplasty technique performed in 2 groups of patients: the only difference between the groups is the surgical tools used during the dorsal hump removal phase (rasp vs the 5-mm osteotome). We used 2 questionnaires of quality of life (QoL), Nasal Obstruction Symptom Evaluation (NOSE), and Rhinoplasty Outcome Evaluation (ROE) questionnaire, to evaluate postoperative outcome (6 months after surgery). Closed rhinoplasty was performed in 107 patients. Dorsal hump removal was carried out with rasp on 35 patients; while in 72 cases, it was performed using a 5-mm osteotome. All the patients were given 2 copies of NOSE and ROE questionnaires (1 month before surgery and 6 months after surgery) to evaluate postoperative QoL. In our study emerged that the use of osteotome in dorsal hump reduction is associated with a better aesthetic outcome (evaluated by analyzing patients QoL with ROE questionnaire) without any difference between the 2 groups in terms of functional outcome (expressed by NOSE questionnaire), major and minor complications and surgical procedure duration.

## Keywords

rhinoplasty, dorsal hump reduction, NOSE, ROE, quality of life

## Introduction

Rhinoplasty is one of the most complex challenges in otorhinolaryngology and aesthetic surgery.<sup>1</sup> The main purpose of this technique is to obtain an improvement in nasal obstruction together with a refinement of the nasal shape.

There are multiple methods, both objective and subjective, to quantify surgical outcomes after rhinoplasty. The objective measures of nasal patency and of the aesthetic outcome, anyway, do not always correlate with subjective patient perception and overall satisfaction.<sup>2</sup> Thus, validated subjective measures to evaluate nasal obstruction and satisfaction have been developed to quantify surgical outcomes. In this field, the main instruments used to evaluate the quality of life (QoL) after surgery are Rhinoplasty Outcome Evaluation (ROE) questionnaire, which scores nasal shape and its influence on aesthetics and self-confidence of the patient and Nasal Obstruction Symptom Evaluation (NOSE) questionnaire, which scores nasal breathing function.<sup>3</sup>

There are many articles in the literature that evaluate surgical outcome using only 1 questionnaire but few articles

that describe the functional and aesthetic results using both NOSE and ROE questionnaires.

In rhinoplasty, the approach to dorsal hump can be done by using different tools: usually, prominent humps are preferably treated with the osteotome, while mild humps can also be approached just by a rasp. In some cases, the surgeon can be undecided about how to treat dorsal hump (typically in those cases when the hump is not too prominent, but the bone is thick and the use of rasp could lead to the development of bone irregularities). In those cases, the experience of the surgeon

<sup>1</sup> Department of Otorhinolaryngology and Head and Neck Surgery, Cattinara Hospital, University of Trieste, Strada di Fiume, Trieste, Italy

Received: May 10, 2019; revised: September 26, 2019; accepted: September 27, 2019

### Corresponding Author:

Alice Piccinato, Department of Otorhinolaryngology and Head and Neck Surgery, Cattinara Hospital, University of Trieste, Strada di Fiume 447, 34149, Trieste, Italy.

Email: [alice.piccinato@yahoo.it](mailto:alice.piccinato@yahoo.it)





**Figure 1.** Different surgical tools used in rhinoplasty: rasps (on the left) and osteotomes (on the right) of different sizes.

becomes crucial in order to choose the most suitable tool for dorsal hump reduction and to obtain a satisfactory aesthetic surgical outcome (Figure 1).

For this reason, we retrospectively evaluated surgical outcome after rhinoplasty in 2 groups of patients: 1 group treated with the osteotome and 1 group treated just with the rasp.

We used both NOSE and ROE questionnaires in order to evaluate pre- and postoperative QoL in these patients. Major and Minor complications and surgical procedure duration were noted.

The only difference between the groups was the surgical tools used during the dorsal hump removal phase: a rasp versus a 5-mm osteotome.

## Patients and Methods

This is a retrospective study approved by the institutional review board of University of Trieste. Every patient gave their informed consent to the present study.

### Population

We identified 165 patients who underwent a rhinoplasty between March 1, 2009, and July 1 2018, at the Department of Otolaryngology of Cattinara Hospital, Trieste, Italy.

All these patients were subjected to a closed rhinoplasty, performed by the same surgeon (M.B.). We chose to include the experience of a single surgeon (M.B.), in order to reduce variability in technique and ensure that the same structural approach to rhinoplasty was applied during surgery; 123 patients met the following inclusion criteria:

- aged older than 18 years and younger than 65 years
- posttraumatic nasal obstruction (facial trauma occurred at least 1 year earlier) with a deviation of the nasal septum and of the nasal pyramid

The exclusion criteria were:

- severe posttraumatic cases (that often require an open approach to rhinoplasty);
- prominent deformities of the tip of the nose;

**Table 1.** The Characteristics of the Sample.

Features	TOT	Osteotome Group 72 Patients	Rasp Groups 35 Patients	P Value <sup>a</sup>
<b>Sex</b>				
Male	55	37	18	<i>P</i> = NS
Female	52	35	17	
<b>NOSE questionnaire</b>				
Pre	77.1	77.7	76.0	<i>P</i> = NS
Post	44.1	41.8	48.7	<i>P</i> = NS
<b>ROE questionnaire</b>				
Pre	41.23	40.5	42.7	<i>P</i> = NS
Post	74.16	77.0	68.3	<i>P</i> = .005
<b>Complications</b>				
Minor	10.3%	8.3%	14.3%	<i>P</i> = NS
Major	0.9%	2.8%	0%	<i>P</i> = NS
<b>Mean age</b>	33 ± 11.2	32.9 ± 10.5	34.4 ± 10.3	<i>P</i> = NS

Abbreviations: NOSE, Nasal Obstruction Symptom Evaluation; NS, not statistically significant; ROE, Rhinoplasty Outcome Evaluation; TOT, total.

<sup>a</sup>The *P* value refers to the statistical comparison between the osteotome group and the rasp group.

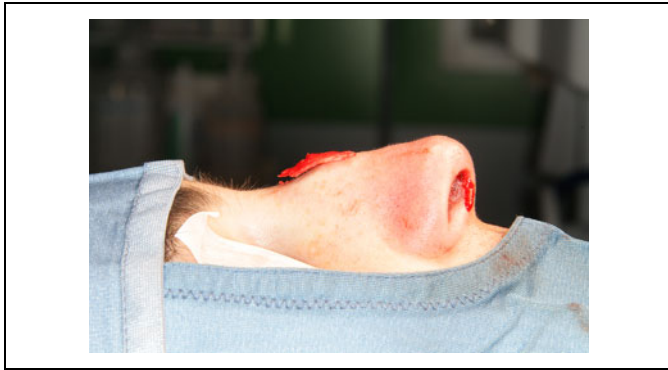- C-shaped deviation of the nasal septum, as they often require the use of grafts with an open approach;
- chronic rhinosinusitis, who needed an additional functional endoscopic sinus surgery during the same session of rhinoplasty;
- all the procedures performed for neoplasia or congenital deformity; and
- revision rhinoplasties.

Of the 123 patients who met the inclusion criteria, only 107 agreed to participate in the study, Table 1 resumes the characteristic of the sample.

We divided the 107 patients into 2 groups, according to the surgical tool used during the phase of dorsal hump removal: rasp (35 patients) or 5-mm osteotome (72 patients). In the included patients, in no cases were both instruments used.

### Surgical Technique

All procedures are performed under general anesthesia, and the rhinoplasty surgery is always a morphofunctional type conducted with a closed technique.<sup>4</sup> In our technique, the first surgical step is an approach to the septum performing a caudal transfixion incision, that is, made through both sides of the membranous septum. This approach provides wide access to all parts of the septum including anterior nasal spine, premaxilla and nasal floor, as well as the nasal dorsum and tip. The surgeon creates 2 surgical tunnels by elevating the mucoperichondrium and the mucoperiosteum from both sides. The cartilaginous septum is disconnected posteriorly by a vertical incision at the chondroperpendicular junction, and the bony



**Figure 2.** Surgical outcome after dorsal hump removal obtained with the use of the osteotome.

and cartilaginous crests are removed. After disconnecting the cartilaginous septum from bony septum by one or more chondrotomies, its base will have to be dissected and dislocated from the premaxilla and anterior nasal spine to provide wide access to the posterior septum. Parts of the septum that are irreversibly deformed or need to be removed to allow repositioning are resected. The next step is an intracartilaginous incision, made at the junction of the upper and lower part of the alar cartilage and continuously with the transfixion incision. The alar cartilages are then shaped in order to model the nasal tip. The surgeon then proceeds to perform a subperichondral and subperiosteal dissection, through the intracartilaginous and transfixion incision in order to approach the dorsal hump.

The following steps are the removal of the dorsal hump (both cartilaginous and bony) and the medial nasal osteotomy. The dorsal hump can be reduced by an osteotome or by a rasp: the choice depends on the features of the bone and on the surgeon experience. When dorsal hump bone is not too prominent but thick, this choice can be difficult and both tools can be used. The osteotome is introduced in the already made “cutting plane” of the cartilaginous hump so that the osteocartilaginous hump can be removed “en bloc” (Figure 2). In case of a small hump, a rasp can be used by doing oscillating movements that progressively reduce the height of the bony dorsum.

The last step is represented by lateral osteotomies: They are performed in order to close the open roof produced by hump removal as well as to narrow and refine the nasal pyramid and to straighten the nasal bones. Lateral osteotomies include both base and horizontal osteotomy: base osteotomy separates the nasal maxillary process from the rest of the maxilla at the base of the nasal pyramid. Horizontal osteotomy which is perpendicular to the base osteotomy is carried out along the line connecting the 2 medial canthi of the eyes to separate the frontal nasal process from the bones of the nose. At the end of the procedure, we insert a nasal pack in each nasal fossa and silastic sheeting as a septal splint secured with a through-and-through suture. We then apply a plaster cast to protect the nasal pyramid.

## Data Collection, Questionnaires, and Statistical Analysis

The data collected about the patients were the following:

- sex and age,
- preoperative and postoperative frontal and lateral pictures of the nasal pyramid, and
- duration of surgery.

Postoperative major complications such as bleeding (requiring additional surgery), and minor complications such as postoperative pain (VAS scale), postoperative bleeding that did not require additional surgery, edema, or ecchymosis.

Each patient received 2 copies of both NOSE and ROE questionnaires (Figure 3) for preoperative (1 month before surgery) and postoperative (6 months after surgery) evaluation.

Nasal Obstruction Symptom Evaluation consists of 5 questions about nasal breathing, each scored by the patient on a scale from 0 (not a problem) to 4 (severe problem). The final result is obtained by multiplying the raw score by 5 to obtain a score from 0 to 100. Thus, a higher score indicates worse symptoms. A negative difference between postoperative and preoperative scores means improvement of nasal obstruction after the intervention. Rhinoplasty Outcome Evaluation is composed of 6 questions (5 about nose shape and 1 about nasal breathing), each rated by the patient on a scale from 0 (worst) to 4 (best). The sum of the scores is recorded as a percentage (of 100). Thereby, a lower score indicates more dissatisfaction. A positive difference between postoperative and preoperative scores means improvement after intervention.

Data analysis was done with statistical software Statistical Package for Social Sciences version 15 (SPSS Inc, Chicago, Illinois). Analysis of variance test was used to analyze patients satisfaction (from a functional and aesthetic point of view) before and after surgery in the 2 groups, the age and surgical procedure time. Student *t* test was used to evaluate global satisfaction rate after surgery in the entire sample. Fisher test was used to evaluate sex distribution, minor, and major complication in the 2 groups.

## Results

The mean age of the sample was  $33 \pm 11.2$  years ( $32.9 \pm 10.5$  for the osteotome group,  $34.4 \pm 10.3$  for the rasp group;  $P = .786$ ). The mean follow-up period was 9.2 months. In the osteome group, there were 35 females and 37 males, while in the rasp group, females were 17 and males were 18 ( $P = .780$ ). Analysis of the NOSE scale showed no significant difference in the 2 groups in the preoperative functional state ( $P = .098$ ), the mean preoperative score was 77.7 for the osteotome group and 76.0 for the rasp group. The mean preoperative NOSE score of the entire sample was 77.1 and the mean postoperative NOSE score was 44.1; therefore, a significant improvement was found comparing the pre- and postoperative functional state ( $P = .000$ ). Comparing the postoperative functional results of the 2 groups, the patients treated with osteotome showed no statistically difference in surgical outcome ( $P = .574$ ), that

Nasal Obstruction Symptoms Evaluation (NOSE)

The nose instrument is used to evaluate functional changes primarily  
For the following questions, how much of a problem were the following condition for you over the last month? Circle the best answer

Nasal congestion or stuffiness  
Not a problem    Very mild problem    Moderate problem    Fairly bad problem    Severe problem  
0                    1                    2                    3                    4

Nasal blockage or obstruction  
Not a problem    Very mild problem    Moderate problem    Fairly bad problem    Severe problem  
0                    1                    2                    3                    4

Trouble breathing through your nose  
Not a problem    Very mild problem    Moderate problem    Fairly bad problem    Severe problem  
0                    1                    2                    3                    4

Trouble sleeping  
Not a problem    Very mild problem    Moderate problem    Fairly bad problem    Severe problem  
0                    1                    2                    3                    4

Unable to get enough air through your nose during exercise or exertion  
Not a problem    Very mild problem    Moderate problem    Fairly bad problem    Severe problem  
0                    1                    2                    3                    4

Rhinoplasty Outcomes Evaluation (ROE)

The ROE instrument is used to evaluate aesthetic changes primarily

How well do you like the appearance of your nose?  
Not at all            Somewhat            Moderately            Very much            Completely  
0                    1                    2                    3                    4

How well are you able to breath through your nose?  
Not at all            Somewhat            Moderately            Very much            Completely  
0                    1                    2                    3                    4

How much do you feel your friends and loved ones like your nose?  
Not at all            Somewhat            Moderately            Very much            Completely  
0                    1                    2                    3                    4

Do you think your current nasal appearance limits your social or professional activities?  
Always                Usually                Sometimes            Rarely                Never  
0                    1                    2                    3                    4

How confident are you that your nasal appearance is the best that it can be?  
Not at all            Somewhat            Moderately            Very much            Completely  
0                    1                    2                    3                    4

Would you like to surgically alter the appearance or function of your nose?  
Definitely            Most likely            Possibly                Probably not            No  
0                    1                    2                    3                    4

**Figure 3.** NOSE and ROE Questionnaires.<sup>3</sup> NOSE indicates Nasal Obstruction Symptom Evaluation; ROE, Rhinoplasty Outcome Evaluation.

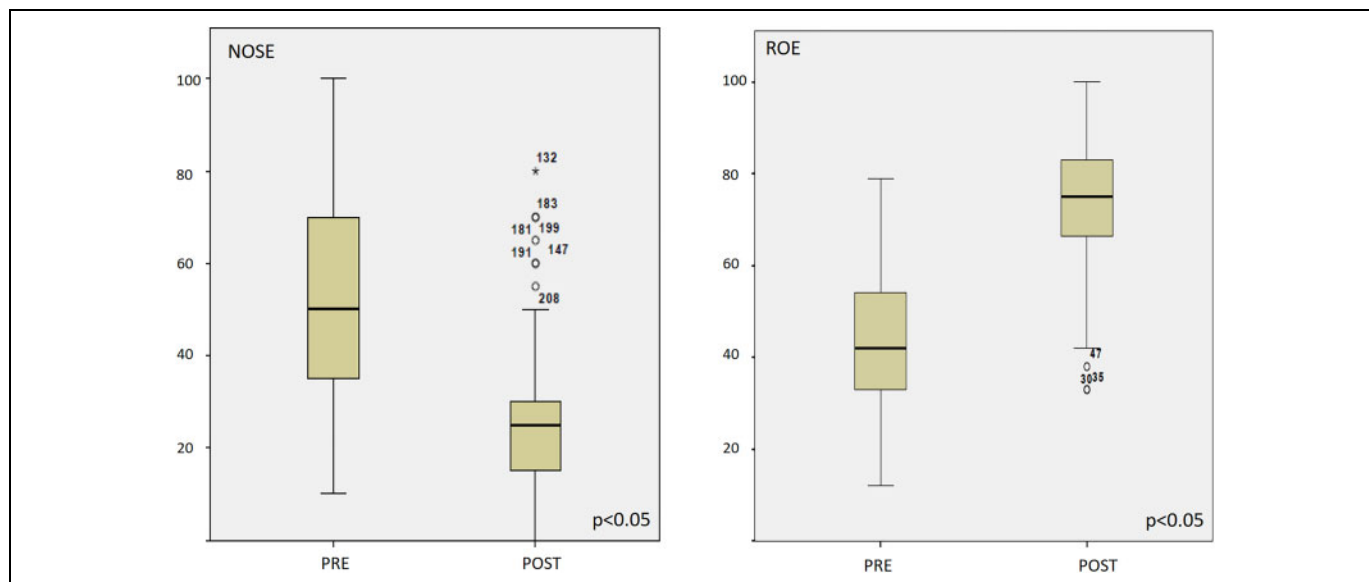
was, 41.8 for the patients treated with the osteotome and 48.7 for the patients treated with the rasp.

Analysis of the ROE scale showed no significant difference in the 2 groups in the preoperative aesthetic state ( $P = .409$ ) with 40.5 in the osteotome group and 42.7 in the rasp group. The mean ROE score of the entire sample preoperatively was 41.23; the mean postoperative score was 74.16 ( $P = .000$ ; Figure 4). The osteotome group showed a higher improvement of the postoperative QoL (77.0) compared to the rasp group in postoperative ROE scale (68.3;  $P = .005$ ; Figure 5).

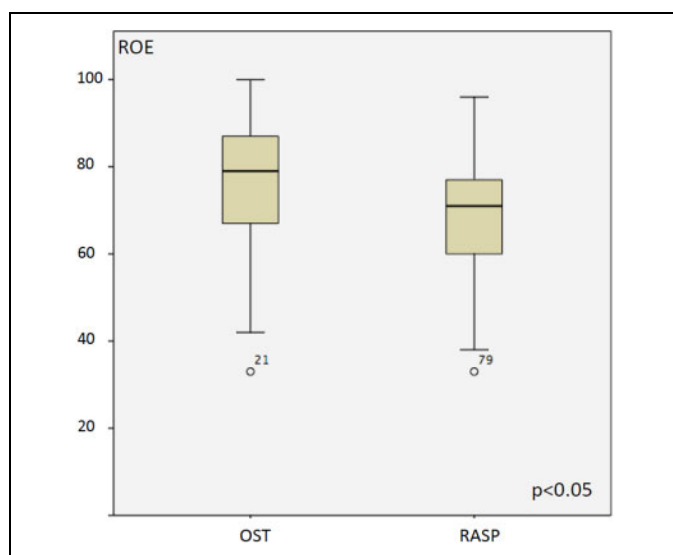
In the osteotome group, there were 2 cases of bleeding after removal of nasal packing that required a further surgical treatment to control hemorrhage (2.8%), no other major complications. No major complication occurred in the rasp group (0%).

The osteotome group showed 6 (8.3%) minor complications; while in the rasp group, 5 minor complications were reported (14.3%;  $P = .264$ ). We did not report case of major esthetical deficit as open roof deformity.

The mean duration of surgery in the rasp group was 64.1 minutes, and 62.7 minutes in the osteotome group ( $P = .981$ ).



**Figure 4.** The postoperative improvement based on NOSE and ROE scores in all patients. NOSE indicates Nasal Obstruction Symptom Evaluation; PRE, preoperative score, POST, postoperative score; ROE, Rhinoplasty Outcome Evaluation.



**Figure 5.** The postoperative outcome of the osteotome group compared to the rasp group based on ROE questionnaires. OST indicates osteotome, RASP, rasp; ROE, Rhinoplasty Outcome Evaluation.

## Discussion

The aim of a septorhinoplasty is to increase patients' QoL after surgery. The appropriate surgery should be chosen not only based on the anatomical part to be rebuilt but also according to what the patient expects about his/her appearance. Patients require careful attention in presurgical consultations, and clear communication should be prioritized to ensure that the surgeon understands the patient's expectations.<sup>5</sup>

There are many surgical techniques to perform rhinoplasty and every technique should be tailored to the clinical features

of the patient. For this reason, we described a sample of patients with homogeneous morphofunctional features, who were submitted to the same surgical procedure. The only difference was the tool used to perform the dorsal hump reduction (osteotome vs rasp).

Objective measures of outcomes are usually more reliable than subjective measures. Unfortunately, a simple, inexpensive, accessible, and reproducible measure does not exist for nasal surgery. Clinical examination is subject to observer bias and is hard to quantify, so it cannot be considered to be objective. This has been shown by the poor correlation between examination and rhinometric measures.

According to Chislolm and Jallali, there is currently no objectively accurate and reproducible means of measuring nasal airway patency.<sup>6</sup>

The difficulty of obtaining an objective measurement of surgical outcomes has moved the attention to the assessment of the subjective QoL of the patient in the postoperative time.

Many tools have been developed to measure patient improvement in QoL after surgery. We chose to use the ROE and NOSE questionnaires because they had been validated<sup>7,8</sup> and they are simple, wieldy, and easy to understand. These questionnaires evaluate preoperative QoL and how it changes during the postoperative period, thus evaluating the degree of patients' satisfaction.

We have decided not to take rhinomanometry into consideration for the postoperative evaluation because there are some disadvantages to this procedure:

- Time-consuming (mask positioning, clearing of nasal cavities, instrumentation, nasal decongestion);
- The facial mask, nozzles, and adapters can falsify the measures and also the nasal catheter can create discomfort on the inflammatory nasal mucosa



- Mathematical description of nonlinear relation and non-laminar flow make rhinomanometry still imperfect.<sup>9</sup>
- The primary aim of this work is to evaluate results of different tools in dorsal hump removal thus rhinomanometry does not give an accurate evaluation about this aspect.

The ROE was found to have excellent test–retest reliability and internal consistency scores, as well as the responsiveness to accurately measure change after surgical interventions. The test–retest reliability coefficient was 0.83, generally recommended for adequate instrument reliability and internal consistency in QoL evaluation.<sup>10</sup>

Cingi et al say that the use of validated procedure-specific QoL tools is essential components for accurately measuring patient-reported outcomes of facial plastic surgery procedures.<sup>11</sup>

In the surgical procedure, osteotomies and dorsal hump removal are fundamental steps in the creation of a sculpted bony pyramid and usually are the most critical surgical moments.

Dorsal hump reduction is typically performed in combination with other nasal alterations. Although surgeon preference is variable for determining the order of the procedure, it is often appropriate to perform the tip refining steps of the procedure before executing the dorsal hump reduction.<sup>12,13</sup>

Reduction of the bony dorsum often accompanies reduction of the cartilaginous dorsum. Both a rasp and an osteotome can be used.<sup>14</sup>

For mild to moderate bony reduction, a pull nasal rasp may be used to reduce the bony portion of the dorsal hump. For large dorsal humps, an osteotome is inserted underneath the transected cartilaginous hump and used to complete the hump reduction en bloc and simultaneously create the medial osteotomies.<sup>15</sup>

The rasp is often used also for smaller bony humps or for fine dorsal contouring. After rasping, it is important to ensure that no palpable small bony particles or irregularities are retained, especially in the thin-skinned patient. Larger bony humps can be removed with a straight osteotome.<sup>16</sup>

In dorsal hump surgery, our work showed a better result by using the osteotome than the rasp. Patients who underwent removal of the hump by means of an osteotome expressed a greater statistically significant satisfaction with the ROE questionnaire.

This may be due to the fact that the dorsal hump reduction by rasp inevitably leads to the formation of minute irregularities of the dorsum that are difficult to control precisely by applying a closed technique. Dorsal hump reduction by osteotome, on the other hand, leads to a clearer and more precise cut allowing to create more regular bone margins. On the other hand, its use requires good surgical skills in order to avoid an exceeding reduction of the dorsal hump bone.

From the functional point of view, there was no statistically significant difference since the improvement is mainly determined by the septoplasty and not by the morphological correction of the nasal hump. Moreover, there is no statistically

significant difference in surgical procedure duration using osteotome or rasp. A prominent dorsal hump may guide the choice to the osteotome because of the increased bone density of the nasal pyramid, particularly evident in male patients. Other factors that could direct toward osteotome technique concern the possible complications using rasp as the disarticulation of the quadrangular cartilage from the bony septum with a catastrophic aesthetic result, and the fact that using a dull rasp can cause much trauma to the dorsal skin with secondary thickening that may take months to thin. One of the most unpleasant aspects of rhinoseptoplasty is postoperative symptoms that include bleeding, pain, ecchymosis, and periorbital edema. In our study, only 2 patients had recurrent bleeding after nasal packing removal and both cases had been treated with osteotome for dorsal hump removal. This is probably due to a greater traumatic effect of this tool at the level of the pyramid dorsum.

The retrospective design is a weakness of the study, and a prospective study should be encouraged; nonetheless, we preferred to work with a larger number of samples with a relatively long follow-up period. Although we tried to avoid selection bias, it remains a possible weakness that also could be eliminated with a prospective, randomized design.

## Conclusion

From our study, it appears that the use of the osteotome rather than the rasp does not influence functional outcomes in dorsal hump removal in selected patients for whom either technique alone would be appropriate. These 2 tools are also comparable in terms of surgical complications rate and surgical time. However, the use of the osteotome in the dorsal hump removal is associated with better aesthetic results in terms of QoL.


## Declaration of Conflicting Interests


The author(s) declared no potential conflicts of interest with respect to the research, authorship, and/or publication of this article.

## Funding

The author(s) received no financial support for the research, authorship, and/or publication of this article.

## ORCID iD

Alice Piccinato  <https://orcid.org/0000-0002-2619-5489>

Alberto Vito Marcuzzo  <https://orcid.org/0000-0002-1340-9900>

## References

1. Apaydin F. Rhinoplasty at the global crossroads. *Arch Facial Plast Surg*. 2009;11(6):421-423.
2. Chisholm E, Jallali N. Rhinoplasty and septorhinoplasty outcome evaluation. *Ear Nose Throat J*. 2012;91(3):E10-E12.
3. Saleh AM, Younes A, Friedman O. Cosmetics and function: quality-of-life changes after rhinoplasty surgery. *Laryngoscope*. 2012;122(2):254-259.

4. Tirelli G, Tofanelli M, Bullo F, Bianchi M, Robiony M. External osteotomy in rhinoplasty: piezosurgery vs osteotome. *Am J Otolaryngol*. 2015;36(5):666-671.
5. Barone M, Cogliandro A, La Monaca G, Tambone V, Persichetti P. Cognitive investigation study of patients admitted for cosmetic surgery: information, expectations, and consent for treatment. *Arch Plast Surg*. 2015;42:46-51.
6. Chisholm E, Jallali N. Rhinoplasty and septorhinoplasty outcome evaluation. *Ear Nose Throat J*. 2012;91(3):E10-E14.
7. Alsarraf R, Larrabee WF Jr, Anderson S, et al. Measuring cosmetic facial plastic surgery outcomes: a pilot study. *Arch Facial Plast Surg*. 2001;3(3):198-201.
8. Stewart MG, Witsell DL, Smith TL, et al. Development and validation of the Nasal Obstruction Symptom Evaluation (NOSE) scale. *Otolaryngol Head Neck Surg*. 2004;130(2):157-163.
9. Pirilä T, Nuutinen J. Acoustic rhinometry, rhinomanometry and the amount of nasal secretion in the clinical monitoring of the nasal provocation test. *Clin Exp Allergy*. 1998;28(4):468-477.
10. Patrick DL, Erickson P. *Health Status and Health Policy: Quality of Life in Health Care Evaluation and Resource Allocation*. New York, NY: Oxford University Press, 1-6, 1993.
11. Cingi C, Songu M, Bal C. Outcomes research in rhinoplasty: body image and quality of life. *Am J Rhinol Allergy*. 2011;25(4):263-267.
12. Larrabee WF. The tripod concept. *Arch Otolaryngol Head Neck Surg*. 1989;115(10):1168-1169.
13. Papel ID. Interlocked transdomal suture technique for the wide interdomal space in rhinoplasty. *Arch Facial Plast Surg*. 2005;7(6):414-417.
14. Sykes J, Tapias V, Kim JE. Management of the nasal dorsum. *Facial Plast Surg*. 2011;27(2):192-202.
15. Azizzadeh B, Reilly M. Dorsal hump reduction and osteotomies. *Clin Plast Surg*. 2016;43(1):47-58.
16. Ilhan AE, Cengiz B, Caypinar Eser B. Double-blind comparison of ultrasonic and conventional osteotomy in terms of early post-operative edema and ecchymosis. *Aesthet Surg J*. 2016;36(4):390-401.