

The use ultrasound guided for refilling intrathecal baclofene pump in complicated clinical cases: A practical approach

P. Caruso*, G. Mazzon, V.M. Sarra, L. Tacconi, P. Manganotti

Unit of Clinical Neurology Department of Medical Sciences, University of Trieste, University Hospital and Health Services of Trieste, Italy

ARTICLE INFO

Accepted 13 August 2018

Keywords:

Muscular spasticity
Intrathecal baclofen therapy
Doppler ultrasounds

ABSTRACT

Muscular spasticity due to neurological disorders is a heavy cause of severe pain and disability for many patients, compromising the independence and quality life. Baclofene is a good tool to guarantee patients independence and pain control. Anyway in chronic therapy oral treatment become unsatisfactory. In all these cases, intrathecal baclofen therapy (ITB), after sub fascial implantation of intrathecal pumps is used as an important long term treatment to reduce spasticity.

After pump implantation the drug reservoir must be refilled periodically in order to maintain the reduction of spasticity and avoid the symptoms and signs of withdrawal. ITB refilling, which involves the insertion of a needle through the skin until the access port of the pump, is often hard, mainly due to the layer of abdominal fat, spasticity, suboptimal pump positioning, pump rotation or inversion, and scar formation over the implantation site. To avoid the difficulties of ITB refilling radiography or other invasive supportive examinations are sometimes needed.

We reported here our experience and we suggest a simple method to use the ultrasound in refilling with particular attention to some cases with complications after implantation with a difficult approach in refilling. We used the ultrasound examination to identify the access port of her pump so as to avoid multiple needle punctures and infections and radiation exposition. Ultrasound-guided technique may facilitate ITB refill in technically challenging cases.

With ultrasound ITB was easily detectable and was quite simple to identify the exact point of needle injection.

In the last years different new applications for ultrasounds are emerging. In our opinion the use of Doppler ultrasounds in the study of muscles and nerves represent an emerging tool for the physician's neurological rehabilitation.

1. Introduction

Muscular spasticity due to neurological disorders usually leads to severe pain and disability compromising the independence and quality life. Intrathecal Baclofen administration (ITB) has been largely described as an important therapy of spasticity in those chronic patients in whom oral and focal therapy became unsatisfactory [1–3].

Baclofen is a gamma-aminobutyric acid (GABA)-B agonist acting on both presynaptic sites and postsynaptic sites. Baclofen inhibits sensory input to the motor neurons of the spinal cord. As previous reported, it is used to treat muscle spasms, spasticity,

and neuropathic pain. FDA approved Baclofen for spasticity to be used intrathecally [4].

In chronic refractory patients continuous regular administration of Baclofen has been seen to be more efficacious than singular bolus. Intrathecal baclofen therapy (ITB), after sub fascial implantation of intrathecal pumps, is used with satisfactory results in muscular spasticity control [5,6].

IDDS implantation is usually easy to manage and consists of two parts requiring two separate incisions. The pump is typically located in the abdomen, the depth of the pocket is typically 1.5–2.5 cm to allow for appropriate needle length during pump refills in the future.

After pump implantation the drug reservoir must be refilled periodically in order to maintain the reduction of spasticity and avoid the symptoms and signs of withdrawal that could compromise quality life; a screening test dose is done prior to implanting

* Corresponding author at: Neurological Department, University of Trieste, Cattinara Hospital ASUITS, Strada di Fiume 447, Trieste, Italy.

E-mail address: paola.caruso1983@libero.it (P. Caruso).

the pump via a lumbar puncture with infusion of baclofen (usually starting with 50 µg incrementing to 100 µg if necessary) [7,8].

Then ITB refilling is usually quite simple maneuver that involves the insertion of a needle through the skin until the access port of the pump, it can readily be performed under the guidance of the refill template. Anyway, refilling pump might be hard procedure in some patients mainly because the gain of weight that patient experience and the thick layer of abdominal fat, moreover, spasticity, suboptimal pump positioning, pump rotation or inversion, and scar formation over the implantation site may worsen the operation. To avoid the difficulties of ITB refilling radiography or other invasive supportive examinations are often needed [9–11].

Aim of this study is to report our experience in the use of ultrasound in refilling the intrathecal pump of baclofen, describing some cases with post implantation complications and to suggest a possible clinical method to approach the use of ultrasound in refilling.

2. Patients and methods

In our department we daily use US guidance to refill baclofen pump, during the last months of 2016 over 7 patients have been followed. In the majority of cases spasticity came from stroke injury, in two cases patients carry the consequences of major trauma with spinal injury. In all cases pump implantation or pump substitution was made in the last 5 years, between 2010 and 2015. The average age of patients was 57 years, and average body mass index was 70 kg/m².

All cases had spasticity of cerebral origin and had oral Baclofen therapy for several years.

In all cases ultrasound machine (Toshiba Aplio XG) with a 10 MHz high-frequency linear array transducer was used to locate the reservoir fill port of the ITB ump. The surface of the intrathecal pump was identified by a well-defined hyperechoic line with acoustic shadowing deep to this line. The transducer was translated across the pump in 2 perpendicular planes in order to center the port on the ultrasound machines screen. The reservoir fill port was identified as a hypoechoic area, which is surrounded by the hyperechoic metallic pump. With a retracted pen we marked the site of the port of the pump. To detect the entrance of pump we used the ultrasound device firstly in vertical line over the pump and then following the horizontal line over the pump. When on the display we detected the clear and defined areas of membrane we signed the skin with two points for each line of the ultrasonic probe. After this, the area was cleaned with Betadine. Then the refill procedure was completed using the needle included in the kit (ITB: Medtronic-SynchroMed II, titanium, 87.5 mm × 25 mm, capacity 20 ml). After refill, ultrasounds were used to ensure that no subcutaneous or pump-pocket fluid was present.

In most of the cases the procedure is simple, repeatable and US finding totally match with the refilling template. In two “difficult patients” the method was useful also in avoiding long approach for refilling in terms of needle pain and radiological examination.

3. Two cases presentation

The *first case* regards a 50-year-old female with spastic quadriplegia as a consequence of a subarachnoid hemorrhage due to middle cerebral artery aneurism rupture. Baclofen pump was implanted in 2010 because of a severe and painful spasticity with a good response. After all, patients gained several kilos and the pump was dislocated in deep stratifications and was quite mobile under the belly and during last year the ITB refill was progressively difficult and in some circumstances patient was necessary the execution of abdominal radiography for refilling. We used the

ultrasound examination to identify the access port of her pump so as to avoid multiple needle punctures and the risk of infections. Patient was positioned seated with the wheelchair. With Doppler ultrasound ITB was easily detectable and was quite simple to identify the exact point of needle injection. This way was repeatable different times and we avoided the use of radiations.

The *second case* regards a 70 years old man with a painful spastic paraparesis due to a car incident. In this patient pump implantation had a good effect on spasticity but was complicated by infections and subsequent changes in pump position (pump felt more deeply in the abdomen pocket) so after couple of years a second implantation procedure was needed. After all patient had presented challenges during prior pump refill procedures mostly due a tight scar tissue and because of significant subcutaneous fat overlying the pump, seated position, with the necessity of previous multiple needle adjustments and radiological imaging support. In the last years ultrasound-guided technique was used with the guidance of the refill template to refill the pump.

The two cases are represented in Fig. 1.

4. Discussion

We describe the possible use of US in the management of intrathecal pump of baclofen as previously reported. In particular we described two intriguing cases with complicated refilling procedure. In both cases because of the deep and mobility of the pump and because of the presences of scars just over the membrane the US was useful.

Baclofen is found to be efficacious for treatment of the spasticity of spinal origin that is a common sequela of spinal cord injury and multiple sclerosis. Data from literature showed that the drug improved spasticity in almost 70–87% of patients [12,13].

The main adverse effects of oral baclofen administration are sedation or somnolence, excessive weakness, vertigo and psychological disturbances; with an incidence reported from 10% to 75%. The majority of adverse effects are transient and reversible. Intrathecal baclofen administration reduce the main adverse effect of the oral dosage and is indicated for use in patients with spasticity of spinal origin unresponsive to treatment with maximum doses of oral baclofen. The benefits of continuous intrathecal baclofen infusion are known and regard improvement in tone and spasms. The main risks of baclofen administration are symptoms related to overdose or withdrawal (seizures, psychic symptoms and hyperthermia). Both conditions may be related to error during refill and programming of the pump.

Refill frequency varies between 1 and 6 months. A kit provided by the pump manufacturer is used during the refill procedure which typically contains an access needle and a template. Usually the maneuver is quite simple, the template is placed on top of the skin overlying the pump, in order to consent the reservoir fill port detection (that usually is located in the center portion of the pump).

In the center of the port a silicone septum is detected and the needle is inserted through the skin and septum [14,15].

During time after pump implantation, changes in pump position, excess of subcutaneous tissues, patient movement, and pain increased the technical difficulty of the refill. Additional factors that may present refill challenges are deep pump pocket, scar tissue, seroma, pump movement within the pocket, in a high percentage of cases catheter complication are reported (like disconnections, migration, kinks, obstruction, development of fibrosis). For instance the migration of the pump into the peritoneal cavity or baclofen pump pocket infection have been previously described. Children appear to be at higher risk for complications than adults [16–18].

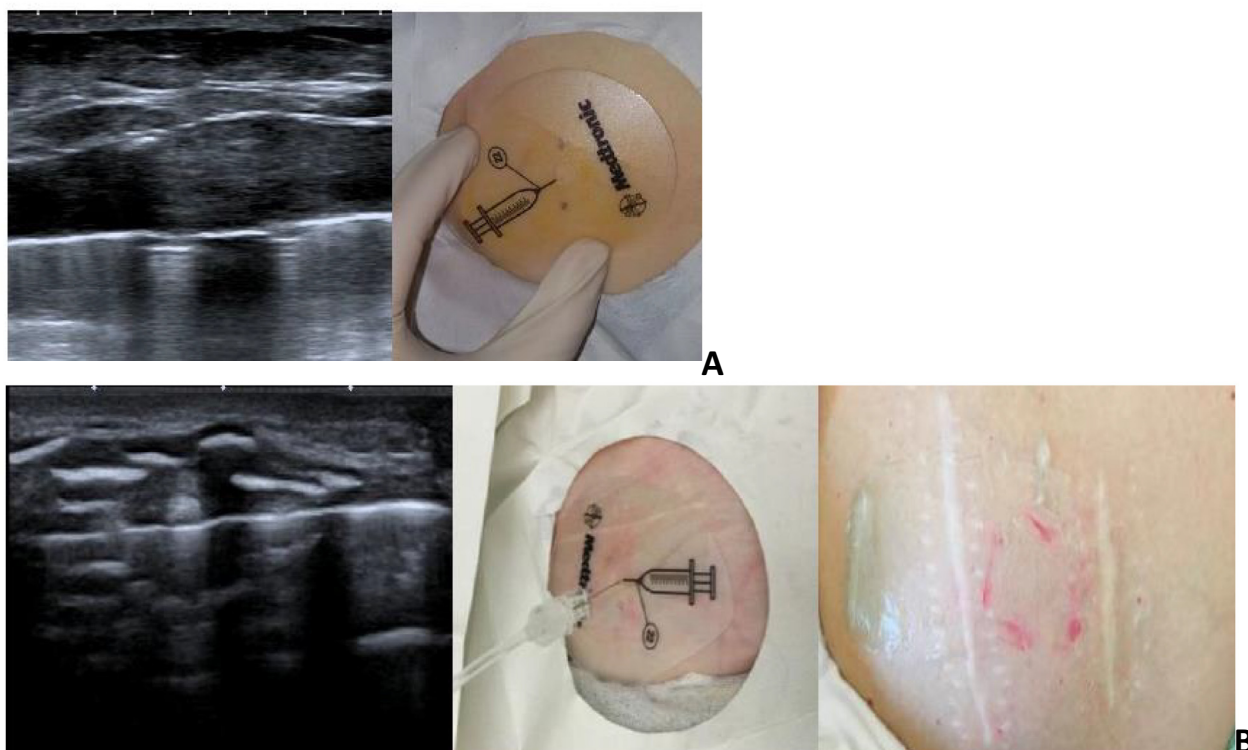


Fig. 1. A. Case one: US imaging of ITB, surface of the intrathecal pump identified by a well-defined hyperechoic line with acoustic shadowing deep to this line with the shadows of the hole with the membrane. The distance between the skin and the pump was of less than 1 cm; Photo pf Belly: Access port of the pump showed with the guidance of the refill template, black spots (marked on the bilateral side of the ultrasonic probe) identified with US completely match with the access of the pump. B. Case two: US imaging of ITB, surface of the intrathecal pump identified by a well-defined hyperechoic line with acoustic shadowing deep to this line with the shadows of the hole with the membrane. The dysomogeneous hyperdense tissue on the surface of the pump characterize the big scars and fat layer. Photo pf Belly: Access port of the pump showed with the guidance of the refill template, black spots (marked on the bilateral side of the ultrasonic probe) identified with US completely match with the access of the pump, cutaneous scars and fat layer.

As a result, multiple unsuccessful attempts at accessing the reservoir fill port can be painful and increase the risk of infection, particularly when repeat skin puncture is required. Blind attempts to refill a pump in challenging cases may also result in subcutaneous injection or pocket fill, resulting in a potentially fatal baclofen withdrawal syndrome.

In these complicated patients the port may also be detected using radiological examination and ultrasound. Ultrasound guidance may allow for pump task visualization and successful port access in several complicated patients.

5. Future aspects

The use of ultrasound guidance to facilitate pump refill seems to present an innovative technical challenges for refill procedures in order to prevent complications. Moreover the use of US may help also in a second phase of drug delivery and procedure monitoring, allowing physicians to early recognize any drug extravasation in the subcutaneous layer. In the same way, data from literature already have reported the use of ultrasounds in pediatric patients with ITB.

ITB pump is usually made of titanium and it reflects ultrasound waves and appears as a highly echogenic outline, anyway the silicone septum is easily visualized as a hypoechoic rectangular structure. This contrast may allow to identify the pump port and may guide the refill procedure.

Fluoroscopy can also be helpful in identifying the position of pumps, and abdominal radiographs can identify flipped pumps, but these are more expensive and not feasible at the bedside.

Ultrasonography is easy to perform, can be performed at bed side, shows dynamic real time imaging, does not involve radiation exposure and potential cost benefits.

Ultrasounds consent also a real-time visualization of the needle traversing tissue and entering the pump port.

In our experience a real-time ultrasound-guided technique has been shown to be beneficial for those complicated patients in which pump refill is challenged (those who have lost a significant amount of weight and have redundant abdominal skin, those who have large pump pockets allowing the pump to easily shift from moment to moment with small movement by the patient, or finally, patients with severe spasticity causing abdominal or hip-girdle spasm during the procedure). We hope in the next future we could learn more and more new application for ultrasounds techniques due to low cost of exams and, in the same time, to its safety.

6. Conclusion

Physicians who provides ITB refilling need to be aware that these devices may suffer unheralded catastrophic malfunction that can lead to potentially lethal overdose administration or failure of refill in those complicated patients in which pump refill is challenged. In the last years different new applications for ultrasounds are emerging. In our opinion the use of Doppler ultrasounds in the study of muscles and nerves represent an emerging tool for the physicians. Ultrasound-guided technique may facilitate ITB refill in technically challenging cases. More experiencing data are needed to improve the technique.

References

- [1] Levy MH. Pain control in patients with cancer. *Oncology* 1999;13(5 Suppl. 2):9–14.
- [2] Lamer T. Treatment of cancer-related pain: when orally administered medications fail. *Mayo Clin Proc* 1994;69:473–80.
- [3] Onofrio BM, Yaksh TL, Arnold PG. Continuous low-dose intrathecal morphine administration in the treatment of chronic pain of malignant origin. *Mayo Clin Proc* 1981;56:516–20.
- [4] Bottros Michael M, Christo Paul J. Current perspectives on intrathecal drug delivery. *J Pain Res* 2014;7:615–26.
- [5] Blackshear PJ, Rohde TD, Prosl F, Buchwald H. The implantable infusion pump: a new concept in drug delivery. *Med Prog Technol* 1979;30:146–9.
- [6] Prager JP. Neuraxial medication delivery: the development and maturity of a concept for treating chronic pain of spinal origin. *Spine* 2002;27:2593–605.
- [7] Mathur SN, Chu SK, McCormick Z. Long-term intrathecal baclofen: outcomes after more than 10 years of treatment. *PM&R* 2014;6(506). e1Y13.e1.
- [8] Greher M, Eichenberger U, Gustorff B. Sonographic localization of an implanted infusion pump injection port: another useful application of ultrasound in pain medicine. *Anesthesiology* 2005;102:243.
- [9] Yang TF, Wang JC, Chiu JW. Ultrasound-guided refilling of an intrathecal baclofen pump: a case report. *Childs Nerv Syst* 2013;29: 347Y9.
- [10] Mithra B, Maneyapanda George C, Chang Chien, Ryan Mattie DO, Prin Amorapanth, Christopher Reger, Zachary L. McCormick: ultrasound guidance for technically challenging intrathecal baclofen pump refill three cases and procedure description. *Am J Phys Med Rehabil.* doi:10.1097/PHM.0000000000000495.
- [11] Ethans K. Intrathecal baclofen therapy: indications, pharmacology, surgical implant, and efficacy. *Acta Neurochir Suppl* 2007;97(Pt 1):155–62.
- [12] Maneyapanda MB, Chang Chien GC, Mattie R, Amorapanth P, Reger C, McCormick ZL. Ultrasound guidance for technically challenging intrathecal baclofen pump refill: three cases and procedure description. *Am J Phys Med Rehabil* 2016.
- [13] Dario A, Tomei G. A benefit-risk assessment of baclofen in severe spinal spasticity. *Drug Saf* 2004;27(11):799–818.
- [14] Plassat R, Perrouin Verbe B, Menei P, Menegalli D, Mathé JF, Richard I. Treatment of spasticity with intrathecal Baclofen administration: long-term follow-up, review of 40 patients. *Spinal Cord* 2004;42(12):686–93.
- [15] Kolaski K, Logan LR. A review of the complications of intrathecal baclofen in patients with cerebral palsy. *NeuroRehabilitation* 2007;22(5):383–95.
- [16] Dastgir A, Ranalli NJ, MacGregor TL, Aldana PR. Baclofen pump catheter leakage after migration of the abdominal catheter in a pediatric patient with spasticity. *J Neurosurg Pediatr* 2015 Sep;16(3):335–9.
- [17] Vanhauwaert DJ, Kalala JP, Baert E, Hallaert G, Crombez E, Caemaert J, et al. Migration of pump for intrathecal drug delivery into the peritoneal cavity. *Case Rep Surg Neurol* 2009 May;71(5):610–2.
- [18] Atiyeh BS, Hayek SN, Skaf GS, Al Araj A, Chamoun RB. Baclofen pump pocket infection: a case report of successful salvage with muscle flap. *Int Wound J* 2006 Mar;3(1):23–8.