

Fatal cardiac perforation and pulmonary embolism of leaked cement after percutaneous vertebroplasty

D'Errico Stefano*, Niballi Sara, Bonuccelli Diana

Department of Legal Medicine, Azienda USL Toscana Nordovest, Lucca, Italy

ARTICLE INFO

Keywords:

Percutaneous vertebroplasty
Cement leakage
Cardiac perforation

ABSTRACT

Percutaneous vertebroplasty consists of percutaneous injection of polymethylmethacrylate (PMMA) via a transpedicular approach for the treatment of collapsed osteoporotic or metastatic vertebrae. Even if percutaneous vertebroplasty is considered to be minimally invasive, threatening complications can occur. Cement leakage is the most common complication of percutaneous vertebroplasty. Rigorous patient selection and individual therapeutic strategy may reduce the occurrence of leakage, in particular the risk of cement entry into the venous system and the spinal canal is the potent major hazard of this technique. Cement pulmonary and cardiac embolism are reported in literature as a cause of unexpected death after percutaneous vertebroplasty. Authors report a fatal case of pulmonary cement embolization occurred after vertebroplasty with haemopericardium, due to the perforation of the right atrium wall from a cement solidified fragment. A complete post mortem examination documented the presence of multiple cement fragments in the pulmonary arteries and transmural perforation of the wall of the right atrium by a whitish needle-like foreign body. Pulmonary microembolization was observed under polarized light.

1. Introduction

Percutaneous vertebroplasty is a minimally invasive technique, described for the first time in 1987 by Galibert, consisting of percutaneous injection of a biomaterial, usually polymethylmethacrylate (PMMA), into the collapsed vertebrae via a transpedicular approach.¹⁻³ Since percutaneous vertebroplasty was introduced, many studies have reported on its effectiveness for relieving persistent pain and for strengthening vertebral bodies weakened by various vertebral diseases, such as osteoporotic vertebral compression fractures, osteolytic metastases, myeloma, and vertebral angioma.^{4,5} However, complications can still occur during the procedure despite the fact that it is considered to be minimally invasive. Reports to the FDA concerned soft tissue damage and nerve root compression related to the leakage of bone cement. In addition the FDA mentioned the lack of prospective, randomized, controlled trials to characterize the long-term safety and effectiveness of vertebroplasty and kyphoplasty. Cement leakage is reported as the main cause of complications; in particular the risk of cement entry into the venous system and the spinal canal is the potent major hazard of this technique.^{6,7} Fatal cases in cardiac perforation are still unreported.

2. Case report

We present the case of a 72yo woman affected by osteoporosis with a 12-week history of severe back pain caused by multiple thoracic vertebral compression fractures. Her past history included reduction mastoplasty. Percutaneous vertebroplasty was performed at T10-T11-T12 with a percutaneous radio-guided injection of 8 cc polymethylmethacrylate (PMMA) directly into the fractured vertebral body using the left transpedicular approach. The patient complained about a mild discomfort shortly after surgery, and a sudden cardiac arrest developed 3 h later. Despite the prompt resuscitation attempts the woman died shortly after. A complete autopsy was performed the day after death. After opening the pericardial sac, 80 gr blood clot was found. A transmural perforation of the wall of the right atrium 1 mm in diameter was also detected with a whitish needle like foreign body 10 mm in length and with a thickness of 1 mm still surfacing from it (Fig. 1a-b). Mild adventitial haemorrhagic infiltration of the proximal aortic segment nearest the transmural surfacing needle-like foreign body was observed (Fig. 1c). The coronary arteries were studied according to Fineschi and Baroldi method, whose result was negative for lumen obstruction. A paravertebral cement leakage in correspondence of T12 was also detected. A gross examination of lungs revealed the presence of whitish string-like foreign bodies with a maximum length of 25 mm in the main

* Corresponding author.

E-mail address: stefano.derrico@uslnordovest.toscana.it (D. Stefano).

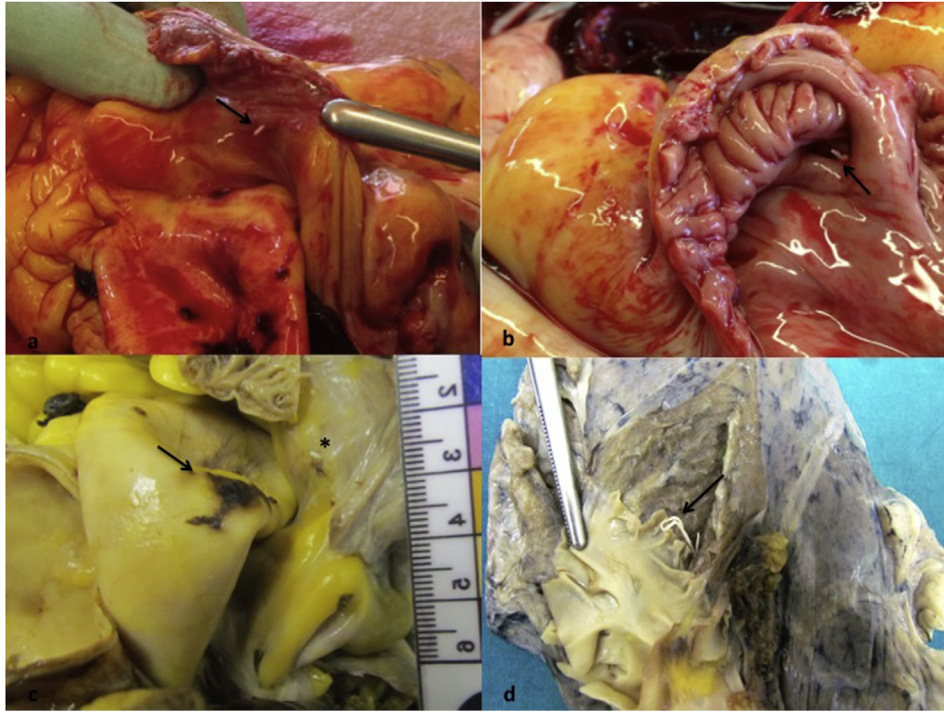


Fig. 1. a-b. Right atrium, complete perforation of the wall from a whitish needle-shaped foreign body. **c.** Haemorrhagic infiltration of aortic wall (black arrow) in correspondence of atrial perforation (asterisk). **d.** Foreign bodies in the main branches of pulmonary artery.

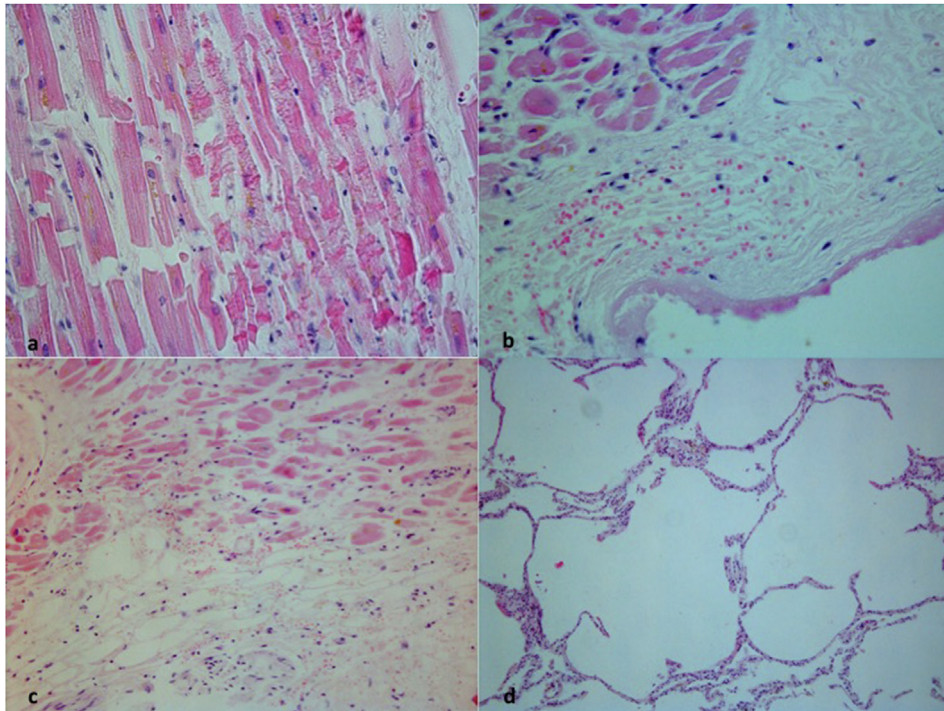


Fig. 2. a. Foci of contraction band necrosis (H&O, 10x). **b-c.** Fibrin layer on the right atrium surface with erythrocytes infiltrating the subepicardial fat and myofibers. **d.** acute pulmonary emphysema.

branches of both pulmonary arteries (Fig. 1d). Samples of organs were collected for histopathological examination and stained with H&E. Multiple foci of contraction band necrosis were detected near the site of perforation (Fig. 2a), where a thin layer of fibrin with few erythrocytes infiltrating the subepicardial fat and myofibers were also observed (Fig. 2b-c). Mild coronary arteriosclerosis was also detected, hence patchy or diffuse fibrosis was excluded. Acute emphysema was

recorded in the lungs (Fig. 2d). Foreign bodies birefringent under polarized light were observed in the lumen of pulmonary septal vessel (Fig. 3a-d). A cardiac tamponade due to perforation of the right atrium from embolized PMMA after vertebroplasty was identified as the cause of death.

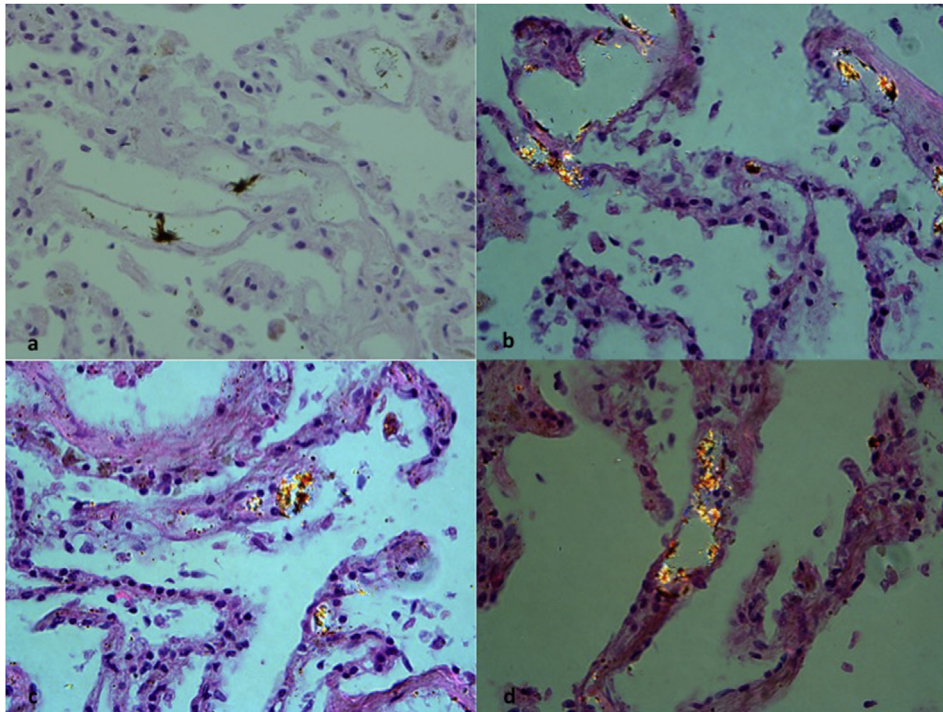


Fig. 3. a. Multiple PMMA emboli in the lumen of pulmonary septal vessels (H&O, 20x). b-d. Multiple PMMA emboli birefringent under polarized light (20x).

3. Discussion

The reported incidence paravertebral leakage of cement ranges widely, from 38% to 73% of patients with malignant collapse, and in 30–65% of patients with osteoporotic vertebral collapse.^{6,7} Cement may leak into a large variety of anatomical compartments, including the needle track, the prevertebral soft tissue in 6%–52.5% of patients, and the spinal canal in up to 37.5% of patients. It may also leak into the intervertebral disc in 5%–25%, prevertebral veins in 5%–16.6%, and epidural veins in 16.5% of patients. Leakage into the metameric artery, inferior vena cava, aorta and lungs have also been reported.⁸ According to the literature, one possible reason for cement leakage (regardless of subsequent embolism of cement material into pulmonary arteries) could be associated with an insufficient polymerisation of the injected cement, probably due to an unbalanced monomer-to-powder ratio.⁷ The cement injection usually occurs through two 10 or 11-gauge cannulae, each of these inserted into one pedicle. Due to problems regarding the cement flow through the relatively slender cannulae with the risk of accidentally cementing the cannulae into the vertebral body, both the viscosity and curing time of the involved cement are important factors to consider during the treatment.⁹ Accurate needle placement, slow injection of cement under good-quality fluoroscopy, and early recognition of cement leaks with termination of injection and release of syringe pressure can all help decrease the risk of cement leaks. Venous cement leakage is reported in up to 24% of percutaneous vertebroplasty, nevertheless, the majority of these remain asymptomatic and carry a risk of pulmonary embolism. Pulmonary embolism caused by percutaneous vertebroplasty has been reported in literature, although the incidence of pulmonary embolism caused by cement from this procedure is unknown because patients do not routinely undergo chest imaging after the procedure. Luetmer et al. reported a relatively high incidence of small asymptomatic cement pulmonary embolism (9.4%) in a cohort of 244 patients treated at 465 vertebral levels during 313 separate vertebroplasty sessions.¹⁰ Of these, 87% had cement pulmonary embolism, and 13% had probable cement pulmonary embolism. A review of the literature found the incidence of cement pulmonary embolism to range from 2.1% to 30%.^{11–20} Paradoxical

cerebral embolism, renal artery embolism and acute respiratory distress syndrome are other life-threatening consequences reported in literature. The possible mechanisms of cement embolism are insufficient polymerisation of the PMMA at the time of the injection, the needle position with respect to the basivertebral vein, and overfilling of the vertebral body, which facilitates cement migration into the venous system. In a few cases, even small emboli may be lethal if they lodge in the right atrium or ventricle and cause cardiac perforation and cardiac tamponade rather than traveling to the pulmonary circulation.^{21–30} Linear pieces of cement as small as 10–20 mm long have been reported to cause cardiac tamponade, and pieces as small as 20 mm have been reported to cause perforations of the right ventricle. It is not surprising that this complication can occur when we consider that all pulmonary emboli pass through the right-sided cardiac chambers. If the cement reaching the right ventricle is too long and stiff to go into the pulmonary artery, it may stay in the heart.^{31–35} Several recommendations have been made to prevent cement leakage into the circulation: (1) cement of an appropriate viscosity and volume should be injected. A paste-like consistency and smaller amounts are preferred; (2) high-resolution fluoroscopy and mixing of the PMMA with barium or tungsten for opacification are essential for the early detection of venous PMMA migration; (3) greater attention should be paid during the multilevel procedure, which has a higher associated risk of pulmonary embolism than single-level PVP; (4) if vertebral venography identifies a direct shunt from the needle tip to the venous system, a repositioning of the needle tip and gelfoam insertion could prevent venous drainage.³⁶ Cardiac perforation is an extremely rare complication of vertebroplasty, with only few cases reported in literature; to the best of our knowledge this is the first fatal cardiac perforation in embolism of leaked cement after vertebroplasty. It has been supposed that while still in a semi-fluid state, the bone cement migrated to the right atrium through the venous system and the cement solidified in the cardiac chambers, resulting in the formation of multiple whitish string-like foreign bodies. One of these perforated the right atrium, others passed through the tricuspid valve in the right ventricle and then in the pulmonary arteries.

References

- Buchbinder R, Johnston RV, Rischin KJ, et al. Percutaneous vertebroplasty for osteoporotic vertebral compression fracture. *Cochrane Database Syst Rev*. 2018. <https://doi.org/10.1002/14651858>.
- Aparisi F. Vertebroplasty and kyphoplasty in vertebral osteoporotic fractures. *Semin Musculoskel Radiol*. 2016;20:382–391.
- Karmakar A, Acharya S, Biswas D, Sau A. Evaluation of percutaneous vertebroplasty for management of symptomatic osteoporotic compression fracture. *J Clin Diagn Res*. 2017;11:RC07–RC10.
- De la Garza-Ramos R, Benvenuti-Regato M, Caro-Osorio E. Vertebroplasty and kyphoplasty for cervical spine metastases: a systematic review and meta-analysis. *Internet J Spine Surg*. 2016;10:7.
- Filippiadis DK, Marcia S, Masala S, Deschamps F, Kelekis A. Percutaneous vertebroplasty and kiphoplasty: current status, new developments and old controversies. *Cardiovasc Interv Radiol*. 2017;40:1815–1823.
- Grelat M, le Van T, Fahed E, Beaurain J, Madkouri R. Rare complication of a percutaneous technique: intradural cement leakage and its surgical treatment. *World Neurosurg*. 2018. <https://doi.org/10.1016/j.wneu.2018.07.045>.
- Saracen A, Kotwica Z. Complications of percutaneous vertebroplasty: an analysis of 1100 procedures performed in 616 patients. *Medicine (Baltim)*. 2016;95:e3850.
- Laredo JD, Hamze B. Complications of percutaneous vertebroplasty and their prevention. *Skeletal Radiol*. 2004;33:493–505.
- Zhan Y, Jiang J, Liao H, Tan H, Yang K. Risk factors for cement leakage after vertebroplasty or kyphoplasty: a meta-analysis of published evidence. *World Neurosurg*. 2017;101:633–642.
- Luetmer MT, Bartholomai BJ, Rad AE, Kallmes DF. Asymptomatic and unrecognized cement pulmonary embolism commonly occurs with vertebroplasty. *Am J Neuroradiol*. 2011;32:654–657.
- Chen HL, Wong CS, Ho ST, Chang FL, Hsu CH, Wu CT. A lethal pulmonary embolism during percutaneous vertebroplasty. *Anesth Analg*. 2002;95:1060–1062.
- Chloe DH, Marom EM, Ahrar K, Truong MT, Madewell JE. Pulmonary embolism of polymethyl methacrylate during percutaneous vertebroplasty and kyphoplasty. *Am J Roentgenol*. 2004;183:1097–1102.
- Duran C, Sirvanci M, Aydoan M, Ozturk E, Ozturk C, Akman C. Pulmonary cement embolism: a complication of percutaneous vertebroplasty. *Acta Radiol*. 2007;48:854–859.
- Focardi M, Bonelli A, Pinchi V, et al. Pulmonary cement embolism after kyphoplasty. *J Forensic Sci*. 2016;61S:S252–S255.
- Jang JS, Lee SH, Jung SK. Pulmonary embolism or polymethylmethacrylate after percutaneous vertebroplasty: a report of three cases. *Spine*. 2002;27:E146–E148.
- Kim JY, Lee JW, Park KW, et al. Pulmonary cement embolism after percutaneous vertebroplasty in osteoporotic vertebral compression fractures: incidence, characteristics, and risk factors. *Radiology*. 2009;251:250–259.
- Krueger A, Bliemel C, Zettl R, Ruchholtz S. Management of pulmonary cement embolism after percutaneous vertebroplasty and kyphoplasty: a systematic review of the literature. *Eur Spine J*. 2009;18:1257–1265.
- Monticelli F, Meyer HJ, Tutsch-Bauer E. Fatal pulmonary cement embolism following percutaneous vertebroplasty (PVP). *For. Sci. Int*. 2005;149:35–38.
- Stricker K, Orler R, Yen K, Takala J, Luginbuhl M. Severe hypercapnia due to pulmonary embolism of polymethylmethacrylate during vertebroplasty. *Anesth Analg*. 2004;98:1184–1186.
- Mansour A, Abdel-Razeq N, Abuali H, et al. Cement pulmonary embolism as a complication of percutaneous vertebroplasty in cancer patients. *Cancer Image*. 2018;18:5.
- Fadili Hassani S, Cormier E, Shotar E, et al. Intracardiac cement embolism during percutaneous vertebroplasty: incidence, risk factors and clinical management. *Eur Radiol*. 2018. <https://doi.org/10.1007/s00330-018-5647-0>.
- Hatzantonis C, Czyn M, Pyzik R, Boszczyk BM. Intracardiac bone cement embolism as a complication of vertebroplasty: management strategy. *Eur Spine J*. 2017;26:3199–3205.
- Bouchez S, Mauermann E, Philipsen T, Wouters P. 3D echocardiographic diagnosis of right ventricular perforation with polymethylmethacrylate particles after vertebroplasty. *J Cardiothorac Vasc Anesth*. 2017;31(6):2123–2126 S1053-0770(17)30107-6.
- Caynak B, Onan B, Sagbas E, Duran C, Akpınar B. Cardiac tamponade and pulmonary embolism as a complication of percutaneous vertebroplasty. *Ann Thorac Surg*. 2009;87:299–301.
- Dreger H, Treskatsch S, Lembcke A, Grubitzsch H, Knebel F, Laule M. Perforation of the right ventricle by bone cement: a rare complication of kyphoplasty. *Eur Heart J*. 2013;34:1203.
- Gosev I, Nascimben L, Huang PH, et al. Right ventricular perforation and pulmonary embolism with polymethylmethacrylate cement after percutaneous kyphoplasty. *Circulation*. 2013;127:1251–1253.
- Ishikawa K, Hayashi H, Mori H. Cardiac perforation caused by cement after percutaneous balloon kyphoplasty. *Asian Cardiovasc Thorac Ann*. 2017;25:204–206.
- Kim SP, Son BS, Lee SK, Kim DH. Cardiac perforation due to intracardiac bone cement after percutaneous vertebroplasty. *J Card Surg*. 2014;29(4):499–500.
- Kim SY, Seo JB, Do KH, Lee JS, Song KS, Lim TH. Cardiac perforation caused by acrylic cement: a rare complication of percutaneous vertebroplasty. *Am J Roentgenol*. 2005;185:1245–1247.
- Shridar P, Chen Y, Khalil R, et al. A review of PMMA bone cement and intra-cardiac embolism. *Materials*. 2016;9. <https://doi.org/10.3390/ma9100821>.
- Lim SH, Kim H, Kim HK, Baek MJ. Multiple cardiac perforations and pulmonary embolism caused by cement leakage after percutaneous vertebroplasty. *Eur J Cardiothorac Surg*. 2008;33:509–511.
- Mattis T, Knox M, Mammen L. Intracardiac methylmethacrylate embolism resulting in right atrial wall perforation and pericarditis following percutaneous vertebroplasty. *J Vasc Interv Radiol*. 2012;23:719–720.
- Moon MH, Jo KH, Kim HW. Cardiac perforation caused by bone cement embolism. *Arch. Cardiovasc. Dis*. 2013;106:413–414.
- Schoenes B, Bremerich DH, Risteski PS, Thalhammer A, Meininger D. Cardiac perforation after vertebroplasty. *Anaesthesist*. 2008;57:147–150.
- Son KH, Chung JH, Sun K, Son HS. Cardiac perforation and tricuspid regurgitation as a complication of percutaneous vertebroplasty. *Eur J Cardiothorac Surg*. 2008;33:508–509.
- Grasso G. Does optimal volume fraction in percutaneous vertebroplasty prevent cement leakage? *World Neurosurg*. 2018. <https://doi.org/10.1016/j.wneu.2018.05.015>.