




Comparisons of fascio-cutaneous anterolateral thigh and sandwich fascial ALT free flap in the distal extremity reconstruction

Mario Cherubino¹  | Chiara Stocco²  | Mario Ronga³ | Federico Tamborini¹ |
Francesca Maggiulli¹ | Danilo Di Giovanna¹ | Corrado Campisi⁴ |
Pietro Di Summa⁵  | Luigi Valdatta¹

¹Division of Plastic and Reconstructive Surgery, Microsurgery and Lymphatic Surgery Research Center, Department of Biotechnology and Life Sciences, University of Insubria, Varese, Italy

²Department of Medical, Surgical and Health Sciences, Plastic and Reconstructive Surgery Unit, University of Trieste, Trieste, Italy

³Department of Medicine and Health Sciences "Vincenzo Tiberio", University of Molise, Campobasso, Italy

⁴Plastic, Reconstructive and Aesthetic Surgery, Lymphatic Surgery and Microsurgery, ICLAS, GVM Care & Research, Rapallo, Genoa, Italy

⁵Department of Plastic and Hand Surgery, Centre Hospitalier Universitaire Vaudois (CHUV), Lausanne, Switzerland

Correspondence

Mario Cherubino, Plastic surgery Unit, Microsurgery and Hand Surgery Unit, ASST Settelaghi Varese, Italy.
Email: mario.cherubino@gmail.com

Abstract

Introduction: The anterolateral thigh (ALT) flap is considered a workhorse reconstructive option; however, it is encumbered by its bulkiness that can result in poor final outcome and need for revision surgery. The aim of the present study was to compare the standard cutaneous ALT free flap and sandwich fascial ALT (SALT) free flap, raised harvesting between the Scarpa's fascia and the crural fascia, for distal extremity soft tissue reconstruction, including pre- intra- and post-operative considerations and outcomes.

Patients and methods: A retrospective review of medical records from 2013 to 2018 of 24 patients who underwent distal extremity reconstruction with standard fascio-cutaneous ALT flap (13 patients) and SALT flap (11 patients) was performed. The mean defect dimensions were 12 × 6.5 cm in group 1 and 12 × 6 in group 2. Surgical outcomes and quality of life were assessed (through the upper extremity functional scale and the lower extremity functional scale questionnaires).

Results: The mean flap dimensions were 13.1 × 7.1 in group 1 and 14.1 × 7.8 in group 2, the overall flap success rate was 100% (one microvascular venous thrombosis occurred in group 1), no statistically significant difference was recorded regarding microvascular thrombosis (one patient in group $p = .369$) and infections (one patient in group 1, $p = .36$) while a statistically significant difference was presence regarding the number of secondary/debulking procedures (6 patients vs. 0) ($p = .0076$) and the quality of life perception showed an overall better perception in group 2 with statistical significant difference ($p = .03$).

Conclusion: The SALT flap represents a valid option, as showed through our preliminary data, when a thin and robust reconstruction is required when dealing with distal extremities soft tissue reconstruction.

1 | INTRODUCTION

The anterolateral thigh (ALT) is a widely used flap and it represents the workhorse option in the reconstruction of heterogeneous anatomic regions (Lee, Chiu, & Shieh, 2011); it can be harvested as

cutaneous, fascio-cutaneous, adipo-fascial or chimeric flap with a variable portion of vastus lateralis muscle. This versatility allows for a tailored reconstructive option based on the specific needs of every case.

On the other hand, it is extensively known that its bulkiness often results in poor aesthetic outcome and need for revision surgery

(Coelho, Ekberg, Svensson, Mani, & Rodriguez-Lorenzo, 2017); this occurrence is particularly true when dealing with areas such as the periorbital area (Cherubino, Turri-Zanoni, et al., 2017) or distal extremity reconstructions (Arnež et al., 2017; Cherubino, Valdatta, et al., 2017; Kuo et al., 2001).

Among the type of flaps from the thigh that can be considered when a thin flap is required, the suprafascial ALT flap, the suprafascial TFL flap or the suprafascial AMT (antero-medial thigh) flap can be considered. However, they are burdened by a certain amount of fat tissue/bulkiness that cannot overcome the need for a thin but reliable flap.

In addition to these reconstructive options, the sandwich fascial ALT (SALT) (Cherubino, Berli, et al., 2017) flap, which is raised including the superficial fascia, fat and crural fascia, can be considered as it can be harvested as a super-thin flap, helping to overcome the bulkiness of the anatomic region.

Historically the standard fascio-cutaneous ALT flaps were defined as those flaps elevated including all layers from epidermis to the muscular fascia (incorporating the crural fascia) while the SALT flaps were defined as those flaps elevated from the Scarpa's fascia to the muscular fascia, overturned and then skin grafted.

The aim of the present study was to review our experience comparing the standard fascio-cutaneous ALT free flap and SALT free flap reconstruction for distal extremity soft tissue reconstruction, including pre- intra- and post-operative considerations and outcomes especially from a functional/aesthetic point of view, with particular focus on the number of complications and number of second procedures needed.

2 | PATIENTS AND METHODS

A retrospective review of medical records at the Microsurgery and Hand Surgery unit, ASST "Sette Laghi," University of Insubria of patients who underwent distal extremity reconstruction with standard ALT flap and SALT flap performed by the same surgeon (MC) from 2013 to 2018 was made.

Patients demographics, pre-operative and operative characteristics, surgical complications need for secondary procedures and follow-up were recorded.

Twenty-four consecutive microsurgical ALT flap reconstructions were performed on 24 distal extremities after tumor excision/trauma: from 2013 to 2016 13 standard fascio-cutaneous ALT flap reconstructions were performed (group 1) and, since its first application in distal extremities reconstruction in 2016, the SALT flaps were chosen and performed (when no weight bearing areas were involved) in 11 patients (group 2). Therefore, in this case series from 2013 to 2016 standard ALT flaps while from 2016 to 2018 SALT flaps were performed (in non-weight-bearing areas and in patients with the same surgical indication).

Patients' mean age was 52 years (range 21–82 years) in group 1 and 55 years (range 24–77 years) in group 2 (Table 1), the mean defect dimensions were 12 × 6.5 cm in group 1 and 12 × 6 cm in group 2.

2.1 | Surgical technique

Preoperative markings of ALT perforators were performed using a hand-held Doppler, following the standard anatomical landmarks (Song, Chen, & Song, 1984). Intraoperatively, the area to be treated was excised or debrided and the recipient vessels prepared. A template of the defect was drawn and transposed to allow for a tailored ALT designed on the thigh. The plane of the flap elevation was performed either at the muscular fascial plane (ALT flap) or between the Scarpa and muscular fascia (SALT flap) (in both techniques the crural fascia was included in the harvesting of the flap); flaps were harvested based on a single dominant perforator that was carefully dissected (Figure 1). The SALT flaps were inset in a "upside-down" fashion with the undersurface of the deep fascia outwards; the SALT flaps were then skin grafted using the cutaneous projection of the standard ALT flaps, allowing for a donor site excision and direct closure, with no additional scarring on the donor site (Figure 2).

At 1 year follow up, all patients were given the upper extremity functional scale (UEFS) and lower extremity functional scale (LEFS) questionnaires.

2.2 | Statistical analysis

Continuous variables were analyzed by Wilcoxon–Mann–Whitney test, median, first, and third quartile; discrete variables analysis was performed through percentage, Chi-square and Fisher test. A *p*-value of less than .05 was considered significant. All statistical studies were conducted using R software version 3.3.3.

3 | RESULTS

The mean size of the flap was similar and comparable. In group 1 the mean ALT dimensions were 13.1 cm × 7.1 cm (range 9–18 × 6–8 cm) and in group 2 the mean SALT dimensions 14.1 cm × 7.8 cm (range 15.5–12.5 × 5.5–12 cm). No major bones involvement in hands and lower legs reconstruction was recorded; in two cases there was a first toe fracture that was stabilized (1 in each group) and in one case (group 1) an amputation of the first three toes was performed.

The mean body mass index (BMI) between the two groups were comparable: 27 in group 1 (range 25–28) and 28 in group 2 (range 26–29) with no statistical significant difference.

The fascio-cutaneous ALT flap thickness was between 2 and 3.8 cm and the SALT flaps between 1.1 and 2.4 cm.

The overall free flap success rate was 100%; In group 1, one vascular complication was recorded (one venous thrombosis) while none in group 2; 1 deep infection was recorded in group 1 and treated with targeted antibiotic therapy in addition to surgical debridement (with the spare of the flap) and a total of 6 patients needed secondary debulking procedures (6 in group 1 and 0 in group 2) in order to improve the functionality or aesthetics. In group 2, in all cases a skin graft was used (it was meshed in three cases) and it healed

TABLE 1 Patients' demographics, flap characteristics/complications/secondary procedures and questionnaire results

Characteristics	Group 1 (adipofascial ALT flap)	Group 2 (SALT flap)	p value
Number of patients	13	11	
Females	5	7	
Defect location			
Hand, n (%)	6	5	
Lower leg/ft, n (%)	7	6	
Age, mean (range)	52 (21-82)	55 (24-77)	
Etiology			
Trauma	12	11	
Burn scarring	1	0	
BMI, mean (range)	27 (25-28)	28 (26-29)	
Defect dimension cm (mean, range)	12 × 6.5 (8-16 × 5-7.5)	12 × 6 (7-13 × 4-10)	
Flap dimension cm (mean, range)	13.1 × 7.1 (9-18 × 6-8 cm)	14.1 × 7.8 (8.5-15.5 × 5.5-12)	
Flap thickness cm (mean, range)	3 (2-3.8)	1.5 (1.1-2.4)	
Donor site primary closure, n (%)	13 (100%)	11 (100%)	
Complications			
Total flap loss, n (%)	0 (0%)	0 (0%)	
Partial flap loss, n (%)	0 (0%)	0 (0%)	
Skin graft failure, n (%)	Not applicable	2 partial (18.1%)	
Vascular complications, n (%)	1 (7.6%)	0 (0%)	.369
Infections, n (%)	1 (7.6%)	0 (0%)	.369
Secondary debulking procedures, n (%)	6 (46.15%)	0 (0%)	.0076
Post-operative outcomes			
UEFS (mean, range)	60.25 ± 3.8	70.75 ± 3.6	.05
LEFS (mean, range)	58.0 ± 4.3	73.75 ± 4.2	.03

Abbreviations: ALT, anterolateral thigh; BMI, body mass index; LEFS, lower extremity functional scale; SALT, sandwich fascial ALT; UEFS, upper extremity functional scale.

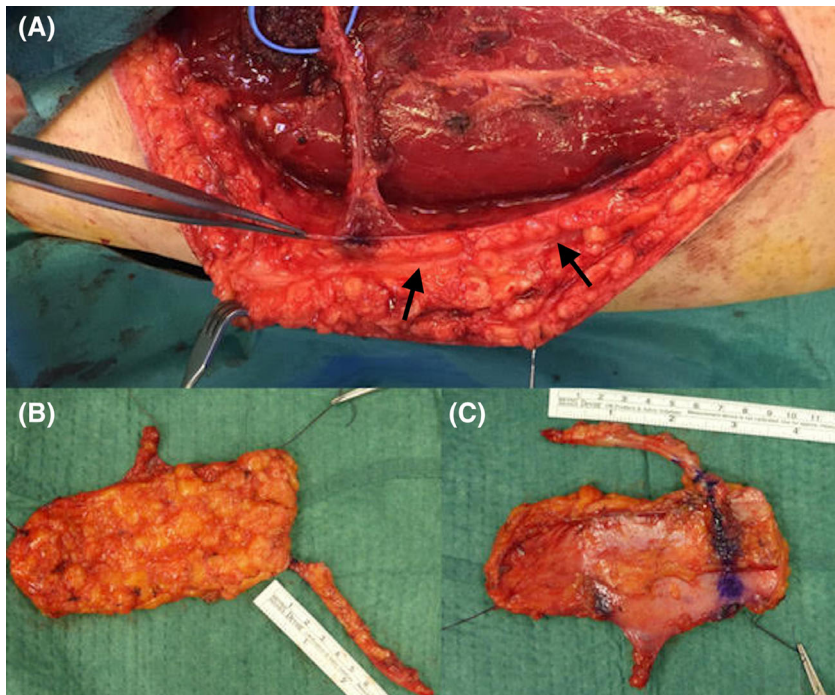


FIGURE 1 SALT flap. In picture (a), the superficial (black narrows) and deep fascia were identified. Picture (b,c) shows the two sides of the SALT flap. SALT, sandwich fascial ALT

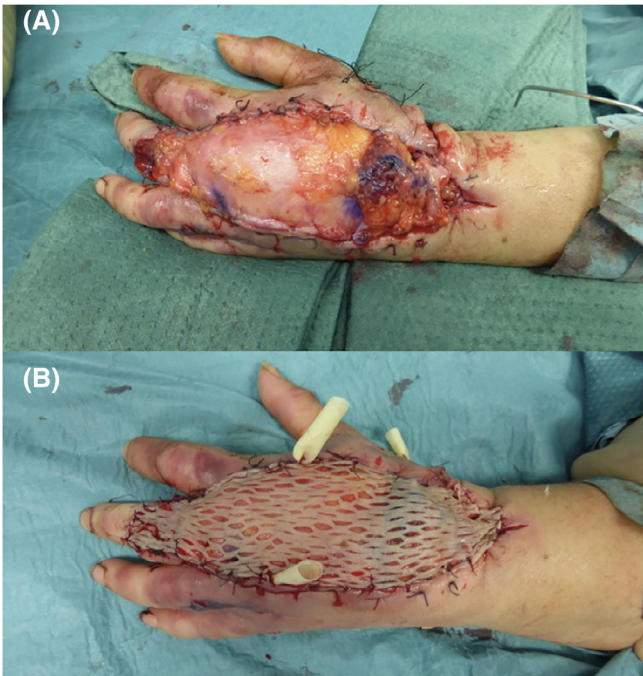


FIGURE 2 hand dorsum reconstruction with SALT flap, intraoperative details. (a) SALT inset and (b) skin graft. SALT, sandwich fascial ALT

satisfactorily with an aesthetic appearance acceptable to the patient. Some representative cases are shown in Figures 3–6.

No significant statistical difference was recorded between the two groups regarding the rate of vascular thrombosis (one patient experienced venous thrombosis in group 1, while none were recorded in group 2, $p = .36$) and infections (one in group 1 and 0 in group 2, $p = .36$) while a statistically significant difference was found regarding the secondary/debulking procedures ($p = .0076$) (Table 1).

At one-year post-operative follow-up visit, all patients were given the UEFS or the LEFS evaluation questionnaires. Three patients were not reachable; hence, 21 patients were available for quality of life questionnaire assessment (10 from group 1 and 11 from group 2). The questionnaires scores displayed a statistically significant difference between the two groups: group 1 UEFS $60.2560.25 \pm 3.8$, group 2 UEFS = 70.75 ± 3.6 ($p = .05$) group 1 LEFS = 58.0 ± 4.3 , group 2 LEFS = 73.75 ± 4.2 , showing an overall better perception in group 2 with statistical significant difference ($p = .03$).

4 | DISCUSSION

The ALT flap is widely considered a workhorse flap for several anatomic region reconstruction due to its versatility and reliability (Ali,

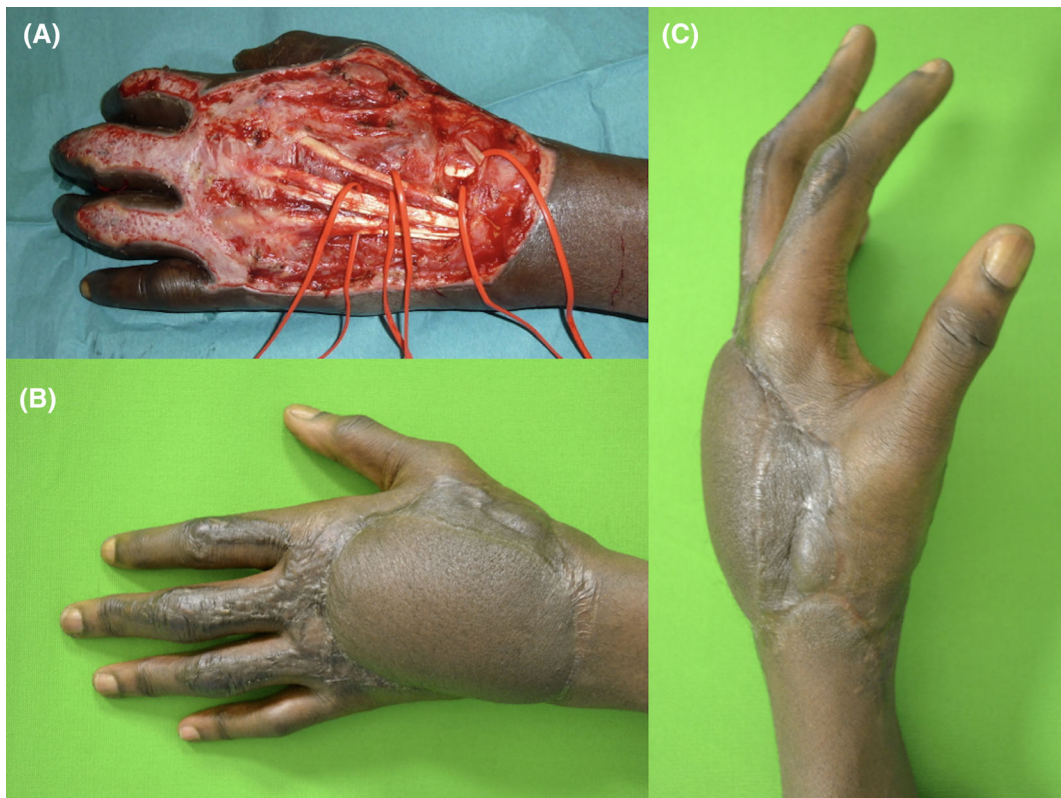


FIGURE 3 ALT hand dorsum reconstruction. (a) Wound after debridement, (b) post-operative frontal and (c) lateral views. This 24-year-old male patient suffered from a hand burn injury while working. The wound was immediately debrided and covered after few days. The flap dimensions were 9×7 cm. The follow-up was of 13 months and the hand functionality was preserved (UEFS score 63.25). ALT, anterolateral thigh; UEFS, upper extremity functional scale

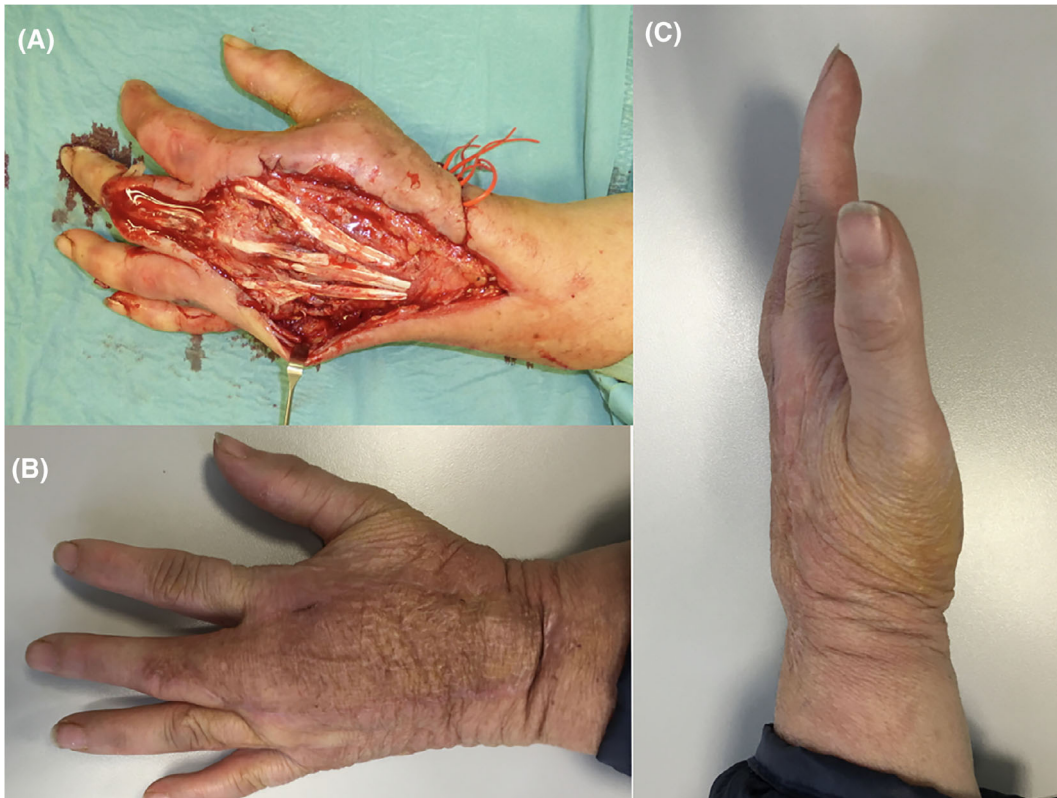


FIGURE 4 SALT hand dorsum reconstruction. (a) Wound after debridement, (b) post-operative frontal and (c) lateral views. This 77-year-old woman suffered from a skin necrosis due to soft tissues infection. The wound was debrided and covered by a 5.5 × 8 cm SALT flap, after resolution of the infection. The follow up pictures were taken at 18 months and the hand functionality was preserved (UEFS score 78). SALT, sandwich fascial ALT; UEFS, upper extremity functional scale

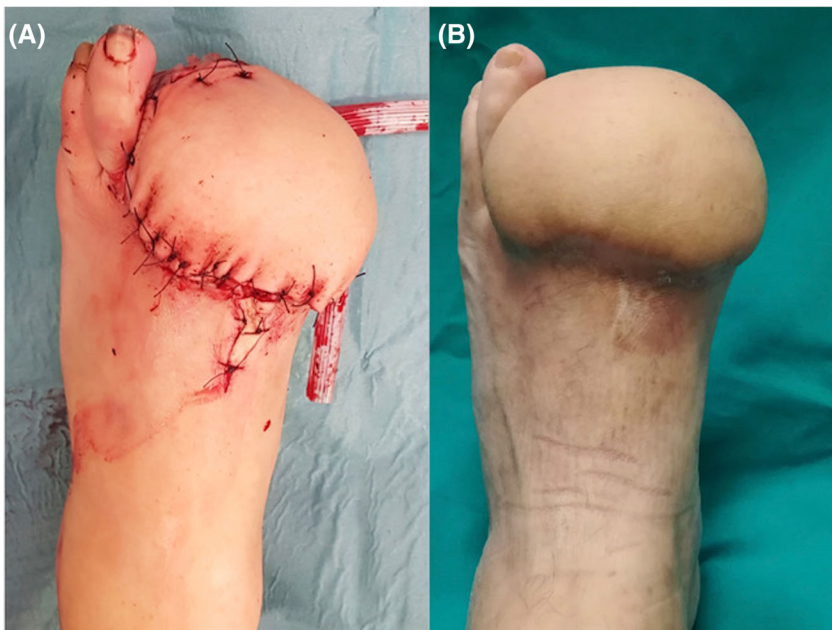


FIGURE 5 ALT foot dorsum reconstruction in a 52-year-old man that suffered from a work accident and underwent surgical debridement with I-II-III toes amputation and a 13 × 8 cm ALT flap. The follow up picture was taken at 15 months; it can be seen that the bulkiness and oedema increased in the late post-operative period (b) compared to the immediate post-operative one (a). The LEFS score was 51. ALT, anterolateral thigh; LEFS, lower extremity functional scale

Bluebond-Langner, Rodriguez, & Cheng, 2009). Nevertheless, the ideal distal extremity reconstruction with an ALT free flap can be hard to achieve, as the fascio-cutaneous ALT flap can be too thick to allow a definitive one stage reconstruction (Wei et al., 2002).

Initially described as a fascio-cutaneous full-thickness flap, the anterolateral thigh flap can be designed and harvested in different fashions such as full- thickness fascio-cutaneous, suprafascial, adipo-fascial, chimeric etc. The decision of the elevation plane varies

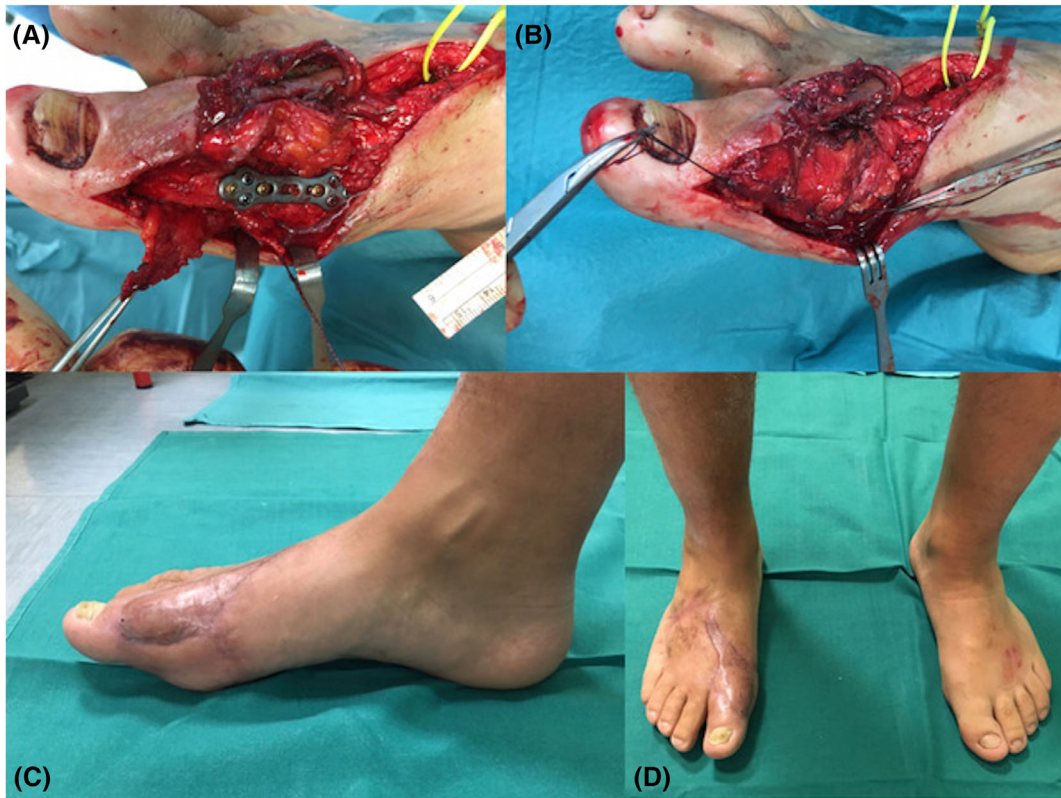


FIGURE 6 a 37-year-old man that suffered from a bike accident and received a first metatarsophalangeal joint arthrodesis and a soft tissue 5.5 × 8.5 cm SALT flap reconstruction. (a,b) Intraoperative details; (c,d) anterior and lateral views at 1 year. The LEFS score was 71.25. LEFS, lower extremity functional scale; SALT, sandwich fascial ALT

depending on the site of reconstruction, on the bulkiness needed and on the patient's habitus, sex, BMI, and thigh pliability (Hong et al., 2014).

In delicate areas such as the distal extremities, the correct selection of flap in combination with an appropriate indication is required; the reconstruction must rely on a robust, reliable well-vascularized thin flap, to allow patients to maintain the function and walk without restriction wearing regular shoes (Dayan, Lin, & Wei, 2009).

In cases, when a thinner flap is needed, a suprafascial ALT flap can be considered a valid option (Maruccia et al., 2017) and it may be raised and debulked at the time of harvest (Seth & Iorio, 2017). This procedure can be technically challenging and in obese patients the flap can still be too bulky (Kim, Lee, & Mun, 2018). Indeed, in certain cases, an immediate flap debulking can be performed (before the flap inset) but this could lead to subdermal plexus/microcirculation impairment, contour and thickness irregularities, and partial flap loss increased rate (Cuomo et al., 2018; Kimura, Saitoh, Hasumi, Sumiya, & Itoh, 2009; Sharabi et al., 2010); a delayed thinning of the flap can be performed at a later stage through liposuction/flap re-elevation and excision but this will increase the number of hospital admissions, the health care system costs and patients' level of stress (Hui-Chou, Sulek, Bluebond-Langner, & Rodriguez, 2011; Ross et al., 2003).

The complication rate related to the thinning techniques, demonstrated that the subfascial plane revealed to be the safest harvesting modality, compared to the suprafascial plane or the thinning

microdissection. In addition, while performing the suprafascial dissection, it is unavoidable that nearby the chosen perforator a variable amount of fat will remain, giving the flap itself the aspect of an inverted pyramid (Figure 6).

In addition, when providing coverage to exposed tendons with the SALT flap, the superficial fascia and the adipose tissue are specifically in contact with the tendons and nerves allowing for an improved chance to give a gliding surface for the tendons and a good option of overcoming the fascial adhesion if a secondary procedure (like a tendon reconstruction) is needed (Crosio et al., 2014). Moreover, a better graft take occurs on the deep fascia surface, comparing to the adipose tissue propose with the standard adipo-fascial flap.

Having made these considerations, the SALT free flap finds one of its most appropriate indications when dealing with distal extremities since it proved to have most of the characteristics needed as it is thin, reliable, and safe.

In this study, we demonstrated that the SALT flap, elevated between the Scarpa's fascia and the Crural fascia is a valid option in distal extremity soft tissue reconstruction; in our report, all the flaps were raised on a single dominant perforator but it is possible to harvest the SALT flap based on multiple perforators if needed. In our opinion, the appropriate surgical indication is represented by non-weight bearing areas (i.e., ankle, foot dorsum) or areas where there is no need for a sensate reconstruction; furthermore, it represents the only choice when an ALT flap is indicated and we are dealing with

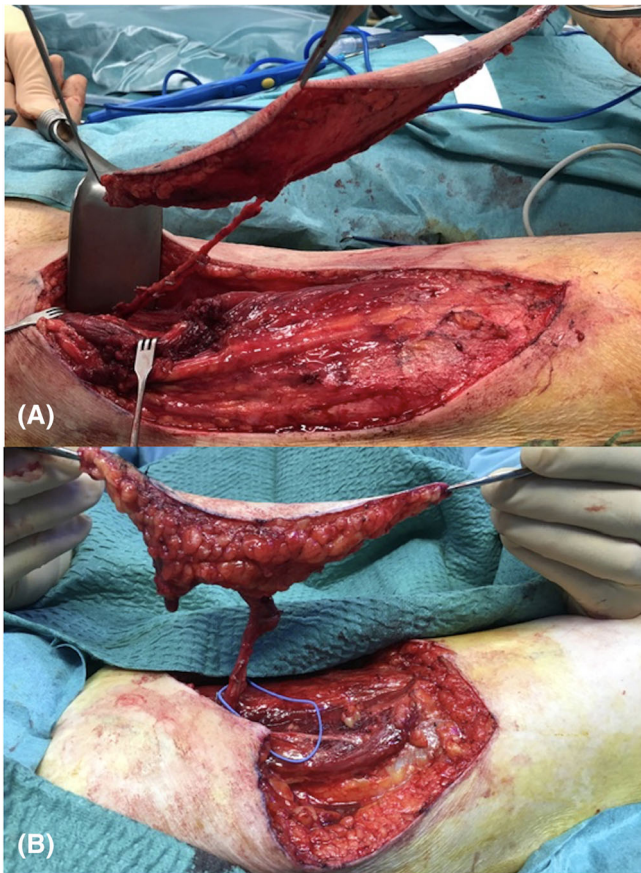


FIGURE 7 The suprafascial ALT flap, with the presence of a variable amount of fat around the perforator. The fat thickness can vary substantially between men (a) and women (b) and needs to be considered when planning a reconstruction. ALT, anterolateral thigh

overweight/obese patients or female “pear shaped” patients (Karastergiou, Smith, Greenberg, & Fried, 2012) (Figure 7).

Analyzing our SALT reconstructions, the functional and aesthetic success, both objective and subjective, was evident thanks to the capability of patients to wear normal shoes and to perform everyday life movements without any kind of function impairment. Moreover, in group 2, patients received only one reconstruction procedure, with no need for secondary flap refinements/debulking, thus leading to a faster return to everyday life, which should not be underestimated. Furthermore, the UEFS and LEFS questionnaires showed a better, and statistically significant, scores in the SALT group of patients. The SALT flaps overcome the main questions present in the introduction, especially regarding the need for secondary surgeries as “touch-up” for the bulkiness of the Fascial ALT.

The limits of this flap are represented by the need for a skin graft which makes it more difficult to be monitored, as the post-operative vascular complications are more arduous to be detected (monitor executable with the hand-held Doppler) with delayed clinical signs of vascular compromise, the treated region needs to be immobilized for 7 days and the skin graft might not take (Cuomo, Grimaldi, Brandi, Nisi, & D'Aniello, 2017); in addition, as previously stated, it cannot be used in weight-bearing areas and where a sensate flap is needed.

In our experience, none of the SALT flaps had a total or partial necrosis, even though the surface reconstruct was fairly extended (Table 1). However, clear anatomy of the blood supply of this flap is unclear. We believe that studies, with the use of the indocyanine green, could add important information on the physiology of these flaps.

The limits of the present report are represented by the retrospective nature of the data and the small cohort of patients (24 patients over 5 years' time) which is a small volume of patients. However, despite the small cohort of patients, in this study we present the first and largest comparing series of patients published to date, analyzing the standard ALT and adipo-fascial ALT flap in distal extremities reconstruction. Further studies and different comparison between SALT and other design of ALT flap should be needed.

5 | CONCLUSION

Distal extremity soft tissue reconstruction remains a demanding issue, as it requires a careful pre-operative planning with specific focus on both function and aesthetic outcome.

The preliminary data obtained from this case series showed that the SALT flap represents a valid option when dealing with distal extremities soft tissue reconstruction and a thin and robust reconstruction is required.

CONFLICT OF INTEREST

The authors declare no potential conflict of interest.

ORCID

Mario Cherubino  <https://orcid.org/0000-0003-1196-3075>

Chiara Stocco  <https://orcid.org/0000-0003-0034-7533>

Pietro Di Summa  <https://orcid.org/0000-0002-3143-8115>

REFERENCES

- Ali, R. S., Bluebond-Langner, R., Rodriguez, E. D., & Cheng, M. H. (2009). The versatility of the anterolateral thigh flap. *Plastic and Reconstructive Surgery*, 124(6, Suppl), e395–e407.
- Arnež, Z. M., Papa, G., Ramella, V., Novati, F. C., Ahcan, U., & Stocco, C. (2017). Limb and flap salvage in Gustilo IIIC injuries treated by vascular repair and emergency free flap transfer. *Journal of Reconstructive Microsurgery*, 33(S 01), S03–S07.
- Cherubino, M., Berli, J., Turri-Zanoni, M., Battaglia, P., Maggiulli, F., Corno, M., ... Valdatta, L. (2017). Sandwich fascial anterolateral thigh flap in head and neck reconstruction: Evolution or revolution? *Plastic and Reconstructive Surgery. Global Open*, 5(1), e1197.
- Cherubino, M., Turri-Zanoni, M., Battaglia, P., Giudice, M., Pellegatta, I., Tamborini, F., ... Valdatta, L. (2017). Chimeric anterolateral thigh free flap for reconstruction of complex cranio-orbito-facial defects after skull base cancers resection. *Journal of Cranio-Maxillo-Facial Surgery*, 45(1), 87–92.
- Cherubino, M., Valdatta, L., Tos, P., D'Arpa, S., Troisi, L., Igor, P., ... Khan, U. (2017). Role of negative pressure therapy as damage control in soft tissue reconstruction for open Tibial fractures. *Journal of Reconstructive Microsurgery*, 33(S 01), S08–S13.

- Coelho, R., Ekberg, T., Svensson, M., Mani, M., & Rodriguez-Lorenzo, A. (2017). Reconstruction of late esophagus perforation after anterior cervical spine fusion with an adipofascial anterolateral thigh free flap: A case report. *Microsurgery*, 37(6), 684–688.
- Crosio, A., Valdatta, L., Cherubino, M., Izzo, M., Pellegatta, I., Pascal, D., ... Tos, P. (2014). A simple and reliable method to perform biomechanical evaluation of postoperative nerve adhesions. *Journal of Neuroscience Methods*, 233, 73–77. <https://doi.org/10.1016/j.jneumeth.2014.06.008> Epub 2014 Jun 14.
- Cuomo, R., Grimaldi, L., Brandi, C., Nisi, G., & D'Aniello, C. (2017). Skin graft donor site: A procedure for a faster healing. *Acta Bio-Medica*, 88(3), 310–314.
- Cuomo, R., Sisti, A., Grimaldi, L., Nisi, G., Brandi, C., & D'Aniello, C. (2018). Ischemic damage of the flaps: New treatments. *Journal of Investigative Surgery*, 2, 1–2 [Epub ahead of print].
- Dayan, J. H., Lin, C. H., & Wei, F. C. (2009). The versatility of the anterolateral thigh flap in lower extremity reconstruction. *Handchirurgie, Mikrochirurgie, Plastische Chirurgie*, 41(4), 193–202.
- Hong, J. P., Choi, D. H., Suh, H., Mukarramah, D. A., Tashti, T., Lee, K., & Yoon, C. (2014). A new plane of elevation: The superficial fascial plane for perforator flap elevation. *Journal of Reconstructive Microsurgery*, 30(7), 491–496.
- Hui-Chou, H. G., Sulek, J., Bluebond-Langner, R., & Rodriguez, E. D. (2011). Secondary refinements of free perforator flaps for lower extremity reconstruction. *Plastic and Reconstructive Surgery*, 127(1), 248–257.
- Karastergiou, K., Smith, S. R., Greenberg, A. S., & Fried, S. K. (2012). Sex differences in human adipose tissues—the biology of pear shape. *Biology of Sex Differences*, 3(1), 13–24.
- Kim, S. Y., Lee, Y. J., & Mun, G. H. (2018). Anatomical understanding of target subcutaneous tissue layer for thinning procedures in Thoracodorsal artery perforator, superficial circumflex iliac artery perforator, and anterolateral thigh perforator flaps. *Plastic and Reconstructive Surgery*, 142(2), 521–534.
- Kimura, N., Saitoh, M., Hasumi, T., Sumiya, N., & Itoh, Y. (2009). Clinical application and refinement of the microdissected thin groin flap transfer operation. *Journal of Plastic, Reconstructive & Aesthetic Surgery*, 62(11), 1510–1516.
- Kuo, Y. R., Jeng, S. F., Kuo, M. H., Huang, M. N. L., Liu, Y. T., Chiang, Y. C., ... Wei, F. C. (2001). Free anterolateral thigh flap for extremity reconstruction: Clinical experience and functional assessment of donor site. *Plastic and Reconstructive Surgery*, 107(7), 1766–1771.
- Lee, Y. C., Chiu, H. Y., & Shieh, S. J. (2011). The clinical application of anterolateral thigh flap. *Plastic Surgery International*, 2011, 127353.
- Maruccia, M., Fallico, N., Cigna, E., Ciudad, P., Nicoli, F., Trignano, E., ... Chen, H. C. (2017). Suprafascial versus traditional harvesting technique for free antero lateral thigh flap: A case-control study to assess the best functional and aesthetic result in extremity reconstruction. *Microsurgery*, 37(8), 851–857.
- Ross, G. L., Dunn, R., Kirkpatrick, J., Koshy, C. E., Alkureishi, L. W., Bennett, N., ... Camilleri, I. G. (2003). To thin or not to thin: The use of the anterolateral thigh flap in the reconstruction of intraoral defects. *British Journal of Plastic Surgery*, 56(4), 409–413.
- Seth, A. K., & Iorio, M. L. (2017 Sep). Super-thin and suprafascial anterolateral thigh perforator flaps for extremity reconstruction. *Journal of Reconstructive Microsurgery*, 33(7), 466–473.
- Sharabi, S. E., Hatef, D. A., Koshy, J. C., Jain, A., Cole, P. D., & Hollier, L. H., Jr. (2010). Is primary thinning of the anterolateral thigh flap recommended? *Annals of Plastic Surgery*, 65(6), 555–559.
- Song, Y. G., Chen, G. Z., & Song, Y. L. (1984). The free thigh flap: A new free flap based on the septocutaneous artery. *British Journal of Plastic Surgery*, 37, 149–159.
- Wei, F. C., Jain, V., Celik, N., Chen, H. C., Chuang, D. C., & Lin, C. H. (2002). Have we found an ideal soft-tissue flap? An experience with 672 anterolateral thigh flaps. *Plastic and Reconstructive Surgery*, 109, 2219–2226 Discussion 2227–2230.