

Malattie Mieloproliferative, project number 1005. E.R. received funding from the Italian Society of Experimental Hematology and the Italian Ministry of Health for Young Investigators.

Contribution: A.S.H. and R.K. conceived and designed the experiments; A.S.H., R.G., C.K., R.J., T.K., T.B., J.D.M.F., B.G., A.C.M., K.P., and K.L.B. performed the experiments; A.S.H., R.G., C.K., A.S., R.J., T.K., D.C., J.D.M.F., F.P.B., J.C., K.L.B., and R.K. analyzed the data; A.S.H., A.S., F.P.B., and J.C. performed the statistical analysis; H.G., E.R., F.P., D.P., R.H., J.C., K.L.B., G.S.-F., M.C., E.H., and R.K. contributed reagents/materials/analysis tools; A.S.H. and R.K. wrote the paper; and all authors contributed to the final version of the manuscript.

Conflict-of-interest disclosure: The authors declare no competing financial interests.

Correspondence: Robert Kralovics, CeMM Research Center for Molecular Medicine of the Austrian Academy of Sciences, Lazarettgasse 14, AKH BT 25.3, 1090 Vienna, Austria; e-mail: rkrlovics@cemm.oew.ac.at.

References

- Kralovics R, Stockton DW, Prchal JT. Clonal hematopoiesis in familial polycythemia vera suggests the involvement of multiple mutational events in the early pathogenesis of the disease. *Blood*. 2003;102(10):3793-3796.
- Rumi E, Passamonti F, Pietra D, et al. JAK2 (V617F) as an acquired somatic mutation and a secondary genetic event associated with disease progression in familial myeloproliferative disorders. *Cancer*. 2006;107(9):2206-2211.
- Bellanné-Chantelot C, Chaumareil I, Labopin M, et al. Genetic and clinical implications of the Val617Phe JAK2 mutation in 72 families with myeloproliferative disorders. *Blood*. 2006;108(1):346-352.
- Landgren O, Goldin LR, Kristinsson SY, Helgadottir EA, Samuelsson J, Björkholm M. Increased risks of polycythemia vera, essential thrombocythemia, and myelofibrosis among 24,577 first-degree relatives of 11,039 patients with myeloproliferative neoplasms in Sweden. *Blood*. 2008;112(6):2199-2204.
- James C, Ugo V, Le Couédic JP, et al. A unique clonal JAK2 mutation leading to constitutive signalling causes polycythaemia vera. *Nature*. 2005;434(7037):1144-1148.
- Kralovics R, Passamonti F, Buser AS, et al. A gain-of-function mutation of JAK2 in myeloproliferative disorders. *N Engl J Med*. 2005;352(17):1779-1790.
- Pikman Y, Lee BH, Mercher T, et al. MPLW515L is a novel somatic activating mutation in myelofibrosis with myeloid metaplasia. *PLoS Med*. 2006;3(7):e270.
- Klampfl T, Gisslinger H, Harutyunyan AS, et al. Somatic mutations of calreticulin in myeloproliferative neoplasms. *N Engl J Med*. 2013;369(25):2379-2390.
- Nangalia J, Massie CE, Baxter EJ, et al. Somatic CALR mutations in myeloproliferative neoplasms with nonmutated JAK2. *N Engl J Med*. 2013;369(25):2391-2405.
- Lundberg P, Nienhold R, Ambrosetti A, Cervantes F, Pérez-Encinas MM, Skoda RC. Somatic mutations in calreticulin can be found in pedigrees with familial predisposition to myeloproliferative neoplasms. *Blood*. 2014;123(17):2744-2745.
- Maffioli M, Genoni A, Caramazza D, et al. Looking for CALR mutations in familial myeloproliferative neoplasms. *Leukemia*. 2014;28(6):1357-1360.
- Rumi E, Harutyunyan AS, Pietra D, et al; Associazione Italiana per la Ricerca sul Cancro Gruppo Italiano Malattie Mieloproliferative Investigators. CALR exon 9 mutations are somatically acquired events in familial cases of essential thrombocythemia or primary myelofibrosis. *Blood*. 2014;123(15):2416-2419.
- Delhommeau F, Dupont S, Della Valle V, et al. Mutation in TET2 in myeloid cancers. *N Engl J Med*. 2009;360(22):2289-2301.
- Ley TJ, Ding L, Walter MJ, et al. DNMT3A mutations in acute myeloid leukemia. *N Engl J Med*. 2010;363(25):2424-2433.
- Carbuccia N, Murati A, Trouplin V, et al. Mutations of ASXL1 gene in myeloproliferative neoplasms. *Leukemia*. 2009;23(11):2183-2186.
- Olcaydu D, Rumi E, Harutyunyan A, et al. The role of the JAK2 GGCC haplotype and the TET2 gene in familial myeloproliferative neoplasms. *Haematologica*. 2011;96(3):367-374.
- Saint-Martin C, Leroy G, Delhommeau F, et al; French Group of Familial Myeloproliferative Disorders. Analysis of the ten-eleven translocation 2 (TET2) gene in familial myeloproliferative neoplasms. *Blood*. 2009;114(8):1628-1632.
- Olcaydu D, Harutyunyan A, Jäger R, et al. A common JAK2 haplotype confers susceptibility to myeloproliferative neoplasms. *Nat Genet*. 2009;41(4):450-454.
- Jäger R, Harutyunyan AS, Rumi E, et al. Common germline variation at the TERT locus contributes to familial clustering of myeloproliferative neoplasms. *Am J Hematol*. 2014;89(12):1107-1110.
- Oddsson A, Kristinsson SY, Helgason H, et al. The germline sequence variant rs2736100_C in TERT associates with myeloproliferative neoplasms. *Leukemia*. 2014;28(6):1371-1374.
- Tapper W, Jones AV, Kralovics R, et al. Genetic variation at MECOM, TERT, JAK2 and HBS1L-MYB predisposes to myeloproliferative neoplasms. *Nat Commun*. 2015;6:6691.
- Li L, Deng B, Xing G, et al. PACT is a negative regulator of p53 and essential for cell growth and embryonic development. *Proc Natl Acad Sci USA*. 2007;104(19):7951-7956.
- Lee WH, Bookstein R, Hong F, Young LJ, Shew JY, Lee EY. Human retinoblastoma susceptibility gene: cloning, identification, and sequence. *Science*. 1987;235(4794):1394-1399.
- Wallace MR, Marchuk DA, Andersen LB, et al. Type 1 neurofibromatosis gene: identification of a large transcript disrupted in three NF1 patients. *Science*. 1990;249(4965):181-186.
- Hussussian CJ, Struwing JP, Goldstein AM, et al. Germline p16 mutations in familial melanoma. *Nat Genet*. 1994;8(1):15-21.

To the editor:

Complement activation in antiphospholipid syndrome and its inhibition to prevent rethrombosis after arterial surgery

Pier Luigi Meroni,^{1,2} Paolo Macor,³ Paolo Durigutto,³ Luca De Maso,³ Maria Gerosa,¹ Mariano Ferrareso,^{1,4} Maria Orietta Borghi,^{1,2} Tom Eirik Mollnes,⁵⁻⁷ and Francesco Tedesco²

¹Department of Clinical Sciences and Community Health, University of Milan, Milan, Italy; ²Laboratory of Immuno-Rheumatology, Istituto Di Ricovero e Cura a Carattere Scientifico, Istituto Auxologico Italiano, Milan, Italy; ³Department of Life Sciences, University of Trieste, Trieste, Italy; ⁴Division of Kidney Transplant, Istituto Di Ricovero e Cura a Carattere Scientifico, Fondazione Ca' Granda-Ospedale Maggiore, Milan, Italy; ⁵Research Laboratory, Nordland Hospital, Bodø, Norway; ⁶Department of Immunology, Oslo University Hospital, Oslo, Norway; and ⁷Faculty of Health Sciences, K. G. Jebsen Thrombosis Research and Expertise Center, University of Tromsø, Tromsø, Norway

Deep vein thrombosis accompanied by pulmonary embolism and thrombotic occlusion of the cerebral and coronary arteries are common and severe complications of antiphospholipid syndrome (APS).¹ Antibodies against beta-2 glycoprotein I (β_2 GPI) bound to endothelial and other circulating cells, including platelets and monocytes, have been implicated in thrombus formation.² Evidence

from animal models supports a 2-hit theory with 1 hit represented by the presence of antibodies against the cell-bound β_2 GPI and the second hit triggered by mechanical, physical, and/or inflammatory stimuli promoting the deposition of β_2 GPI on endothelial cells.²⁻⁴ Infectious agents, arterial hypertension, pregnancy, oral contraceptive pills, and surgical interventions have all been documented as

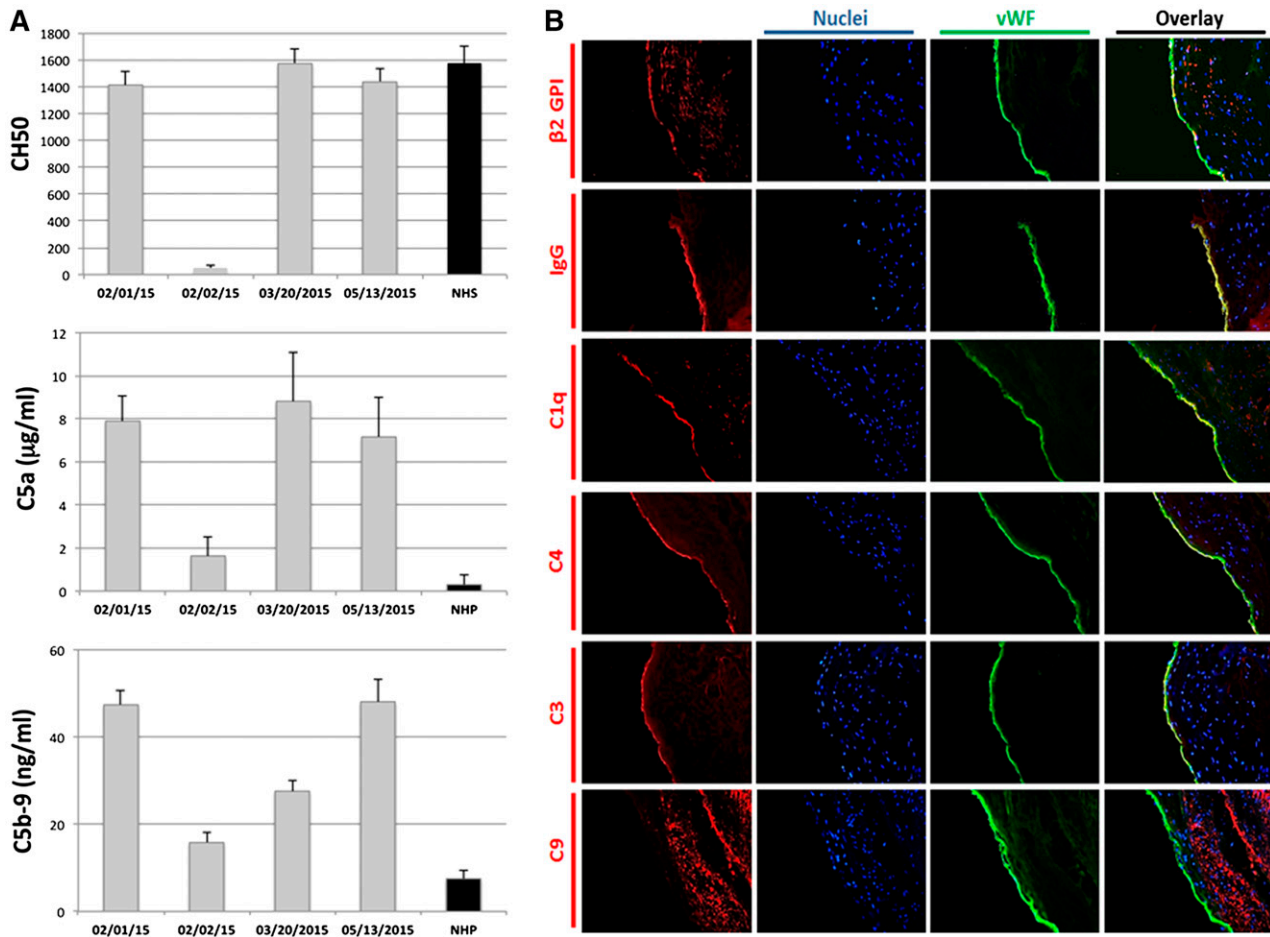


Figure 1. Complement profile in serum/plasma samples and immunofluorescence analysis of the wall of the occluded femoral artery for the deposition of β_2 GPI and complement components. (A) CH50 hemolytic activity was evaluated in serum samples collected from the patient before (February 1, 2015) and at various time points after the infusion of eculizumab. A pool of sera from 25 healthy blood donors (normal healthy sera [NHS]) was used as control. The levels of C5a and soluble C5b-9 were measured in plasma samples at the same time points. A pool of plasma from 25 healthy blood donors (normal healthy plasmas [NHP]) was used as control. (B) The tissue was stained for β_2 GPI with biotin-labeled recombinant antibody MBB2 Δ CH2 followed by phycoerythrin-labeled streptavidin. To evaluate deposition of human IgG, CY3-labeled goat anti-human IgG was used; goat polyclonal antibodies were used to detect C1q, C4, and C3 followed by tetramethylrhodamine-labeled rabbit anti-goat IgG. C9 deposition was revealed by mouse monoclonal antibody (aE11) and CY3-labeled goat anti-mouse IgG. von Willibrand factor (vWF) on tissue was detected by using polyclonal rabbit IgG followed by fluorescein isothiocyanate-labeled horse anti-rabbit IgG. The sections were examined under a Leica DM2000 fluorescence microscope (Leica) equipped with a digital camera (DFC 490; Leica). Images were acquired by using Leica Application Suite Software. Original magnification $\times 200$. Note the deposition of β_2 GPI, IgG, C1q, C4, and C3, double-stained together with vWF on the endothelium, whereas C9 was predominantly localized in the subendothelium region.

potential triggers.² These findings have important implications in APS patients undergoing surgery, particularly in those requiring bypass surgery to restore blood flow following a thrombotic vascular occlusion.⁵

Activation of the complement system by antibody- β_2 GPI complexes has been shown to play a critical role in thrombus formation as demonstrated by the ability of C5 inhibitors to prevent blood clots in animals receiving intravascular infusion of antibodies to β_2 GPI.^{3,6,7} Herein we report for the first time the case of an APS patient with vascular occlusion who required bypass surgery and was successfully treated prophylactically with eculizumab to prevent thrombosis of the bypass. We also provide evidence of complement deposition at the site of the occluded vessel.

The complement system was investigated by measuring 50% complement (CH50) hemolytic activity in serum and the circulating levels of the activation products C5a and terminal complement complex (C5b-9) in plasma samples collected in EDTA as previously described in detail.⁸

The wall of the occluded femoral artery was examined by indirect immunofluorescence for deposits of β_2 GPI and complement

activation products by using primary antibodies from goat (anti-immunoglobulin G [anti-IgG], Sigma-Aldrich, Milan, Italy; anti-C1q and C4 [The Binding Site, Birmingham, United Kingdom]; and anti-C3 [Quidel, San Diego, CA]), rabbit (anti-von Willibrand factor, Dako, Glostrup, Denmark), and mouse (anti-C9 monoclonal antibody AE11),⁹ along with human antibody selected from the human phage display library (monoclonal antibody anti- β_2 GPI)⁶ and fluorescein isothiocyanate-labeled secondary antibodies.

The patient is a 59-year-old woman admitted to this study after obtaining informed consent and approval from the Institutional Review Board of Milan, Area B. She had a long history of primary APS¹⁰ starting at the age of 43 years with an episode of left limb deep vein thrombosis and secondary pulmonary thromboembolism followed 6 months later by complete occlusion of the right anterior and posterior tibial arteries, leading to amputation of the III, IV, and V right toes. Screening analysis for antiphospholipid antibodies revealed positivity for lupus anticoagulant and high levels of IgG anticardiolipin and anti- β_2 GPI. She was given anticoagulant therapy with warfarin that was maintained thereafter. In 2007, the patient experienced a large nonhealing skin ulcer in the pretibial area, and in

2012, she developed seizures. Two years later, multiple skin ulcers appeared over the I and II toes of the right foot followed by critical ischemia of the II right toe. Doppler ultrasound showed a partial occlusion of the femoral artery just above the knee and multiple segmental occlusions in both tibial arteries. Extensive investigation for traditional cardiovascular risk factors was negative. Warfarin therapy was stopped and replaced by low-molecular-weight heparin (1 mg/kg every 12 hours) prior to percutaneous transluminal angioplasty of the distal femoral artery and the posterior tibial artery and stenting of the right dorsalis pedis artery. Unfortunately, she displayed an acute ischemia soon after the procedure that required thrombolysis. Six weeks later, a progressive reduction in blood supply to the II right toe was observed. Doppler ultrasound and angiography revealed a subocclusion of the stent and complete occlusion of the distal femoral and popliteal arteries and also of the anterior and posterior tibial arteries. The patient was scheduled for a femoro-popliteal bypass performed 2 weeks later. Because of the high risk of rethrombosis after surgical procedure reported in the literature,⁵ the previous clinical history of the patient, and failure of animals that were C6 deficient^{3,9} and treated with anti-C5³ to develop antibody-induced thrombi, a short prophylactic treatment with eculizumab was adopted to prevent complement activation. The patient was still on low-molecular-weight heparin and received the first dose of eculizumab (900 mg) the day before surgery followed 1 week later by a second infusion of the same dose. The postoperative period was uneventful, and complete revascularization of the right limb was achieved while the patient was receiving heparin.

Analysis of the serum sample collected before the first infusion of eculizumab showed a CH50 value within the normal range whereas the levels of C5a and soluble C5b-9 were elevated in the plasma sample (Figure 1A). The normal CH50 activity, despite the elevated levels of the activation products of the terminal components, can be explained by the higher sensitivity of the detection system used to reveal the presence of these products. As expected, the CH50 activity dropped to a negligible value 1 day after eculizumab administration and returned to a normal level approximately 50 days later (Figure 1A). Similarly, the levels of these complement activation products markedly decreased in the early phase after infusion and then gradually arose to preinfusion values after therapy was stopped, which suggests ongoing complement activation. The marked decrease of the plasma levels of soluble C5b-9 and C5a cannot be attributed to their interaction with eculizumab because this antibody recognizes only native C5 and fails to react with either C5a or C5b present in the terminal complex. This finding can be better explained by the reduced release of newly formed C5 fragments induced by eculizumab and also by their short half-life, which helps limit their damaging effect.

Immunofluorescence analysis of cells from the artery wall harvested during the bypass procedure (Figure 1B) revealed for the first time in an APS patient the presence of β_2 GPI on the endothelium perturbed by the mechanical occlusion and the associated metabolic changes, which confirms the findings obtained in an animal model of APS. We have previously shown that fluorescently labeled β_2 GPI does not bind in vivo to quiescent endothelium with the exception of decidual endothelial cells and that the cell binding requires priming by lipopolysaccharide.⁴ IgG co-localized with β_2 GPI on the endothelial cells is most likely directed against this glycoprotein, and the endothelial deposition of C1q, C4, and C3 provides indirect evidence that the cell-bound immune complexes activate complement through the classical pathway. Progression of complement activation to the terminal sequence is supported by the vascular localization of C9 revealed by an antibody that recognizes

a neoantigen expressed by this molecule in the C5b-9 complex. This extends to a human patient the finding of C9 deposited at sites of thrombus formation in a rat model of APS induced by antibodies to β_2 GPI.³

In conclusion, we report for the first time complement activation by antiphospholipid antibodies in arterial thrombosis in the circulation and, more importantly, in the arterial wall. Moreover, the clinical history of our patient supports the rationale for complement inhibition therapy with a short course of eculizumab to prevent rethrombosis triggered by vascular surgery, although randomized controlled studies are required to justify the adoption of this therapeutic strategy. Our finding reinforces the use of eculizumab in APS, which extends the beneficial effect of the drug already reported in the catastrophic variant of this syndrome.^{11,12}

Acknowledgments: This work was supported by Ricerca Corrente, Istituto Di Ricovero e Cura a Carattere Scientifico, Istituto Auxologico Italiano (P.L.M.).

Contribution: P.L.M. designed the research; P.M. designed the complement analysis; P.D. performed the immunofluorescence analysis; L.D.M. performed the complement assays; M.G. prepared the clinical history; M.F. organized and performed the surgical intervention and collected the tissue, serum, and plasma samples; M.O.B. performed the screening assays for antiphospholipid antibodies; P.L.M., T.E.M., and F.T. wrote the manuscript; and all the authors critically reviewed and edited the manuscript.

Conflict-of-interest disclosure: The authors declare no competing financial interests.

Correspondence: Pier Luigi Meroni, Division of Rheumatology, Istituto G. Pini, Ricerca Corrente by Istituto Auxologico Italiano, Piazza C. Ferrari 1, 20122 Milan, Italy; e-mail: pierluigi.meroni@unimi.it.

References

1. Giannakopoulos B, Krilis SA. The pathogenesis of the antiphospholipid syndrome. *N Engl J Med*. 2013;368(11):1033-1044.
2. Meroni PL, Borghi MO, Raschi E, Tedesco F. Pathogenesis of antiphospholipid syndrome: understanding the antibodies. *Nat Rev Rheumatol*. 2011;7(6):330-339.
3. Fischetti F, Durigutto P, Pellis V, et al. Thrombus formation induced by antibodies to beta2-glycoprotein I is complement dependent and requires a priming factor. *Blood*. 2005;106(7):2340-2346.
4. Agostinis C, Biffi S, Garrovo C, et al. In vivo distribution of β_2 glycoprotein I under various pathophysiologic conditions. *Blood*. 2011;118(15):4231-4238.
5. Saunders KH, Erkan D, Lockshin MD. Perioperative management of antiphospholipid antibody-positive patients. *Curr Rheumatol Rep*. 2014;16(7):426-434.
6. Agostinis C, Durigutto P, Sblattero D, et al. A non-complement-fixing antibody to β_2 glycoprotein I as a novel therapy for antiphospholipid syndrome. *Blood*. 2014;123(22):3478-3487.
7. Romay-Penabad Z, Carrera Marin AL, Willis R, et al. Complement C5-inhibitor rEV576 (coversin) ameliorates in-vivo effects of antiphospholipid antibodies. *Lupus*. 2014;23(12):1324-1326.
8. Marzari R, Sblattero D, Macor P, et al. The cleavage site of C5 from man and animals as a common target for neutralizing human monoclonal antibodies: in vitro and in vivo studies. *Eur J Immunol*. 2002;32(10):2773-2782.
9. Noris M, Galbusera M, Gastoldi S, et al. Dynamics of complement activation in aHUS and how to monitor eculizumab therapy. *Blood*. 2014;124(11):1715-1726.
10. Miyakis S, Lockshin MD, Atsumi T, et al. International consensus statement on an update of the classification criteria for definite antiphospholipid syndrome (APS). *J Thromb Haemost*. 2006;4(2):295-306.
11. Strakhan M, Hurtado-Sbordoni M, Galeas N, Bakirhan K, Alexis K, Elrafei T. 36-year-old female with catastrophic antiphospholipid syndrome treated with eculizumab: a case report and review of literature. *Case Rep Hematol*. 2014;2014:704371.
12. Erkan D, Aguiar CL, Andrade D, et al. 14th International Congress on Antiphospholipid Antibodies: task force report on antiphospholipid syndrome treatment trends. *Autoimmun Rev*. 2014;13(6):685-696.